



Supernumerary Teeth – Literature Review

Kamil Tworkowski^{1,A-B,D-F}, Ewelina Gąsowska^{1,B,D}, Dorota Baryła^{1,C-D}, Katarzyna Gabiec^{2,E-F}

¹ Student Research Group “StuDentio”, Department of Dentistry Propaedeutics, Medical University, Białystok, Poland

² Private Practice Lux-Dent Stomatologia, Białystok, Poland

A – Research concept and design, B – Collection and/or assembly of data, C – Data analysis and interpretation, D – Writing the article, E – Critical revision of the article, F – Final approval of article

Tworkowski K, Gąsowska E, Baryła D, Gabiec K. Supernumerary Teeth – Literature Review. J Pre-Clin Clin Res. 2020; 14(1): 18–21. doi: 10.26444/jpccr/119037

Abstract

Introduction and objective. Hyperdontia is a developmental anomaly characterised by an increased number of dental buds. It is condition with a prevalence of 0.3–1.8% in primary dentition and 1.5–3.9% in permanent dentition. The abnormality occurs more often in the jaw, in anterior region and in permanent dentition. This study aimed to review current literature and present the aetiology, prevalence, diagnosis, treatment options and complications of supernumerary teeth.

State of knowledge. Supernumerary teeth can be divided according to different criteria: by structure, tooth shape, location and number of additional teeth. The most common supernumerary tooth is mesiodens, which is an additional tooth located between the central incisors of the jaw. The aetiology of formation of supernumerary teeth is not yet fully known. At present, the most probable hypothesis for the development of hyperdontia is the hyperactivity of dental lamina. Supernumerary teeth may cause aesthetic and functional problems like delayed eruption, alterations in the eruptive pattern, shift in the midline, dental crowding, pathology in adjacent teeth, problems with correct occlusion. These problems are the most common reason for patients to report to their dentist. When an supernumerary tooth does not cause any troubles or aesthetic disorders, its detection is usually accidental during the X-rays examination. Treatment depends on the specific clinical situation. Making a diagnosis and developing an appropriate treatment plan often requires cooperation of many specialists.

Conclusion. Supernumerary teeth may cause aesthetic deformities and functional impediments, therefore early diagnosis and interdisciplinary intervention are important to minimize consequences to the developing dentition.

Key words

hyperdontia, supernumerary teeth, anomaly

INTRODUCTION AND OBJECTIVE

Hyperdontia (supernumerary teeth) is a developmental anomaly of presently unknown aetiology, whereas, according to many authors, it occurs due to the hyperactivity of dental lamina or the tooth bud dichotomy [1]. Hyperdontia is defined in the literature as a tooth malformation characterised by an increased number of dental buds in permanent or primary dentition [2]. Supernumerary teeth may occur at any place in the dental arch [3]; however, their most frequent location is the anterior region of the jaw, and then the region of lower premolars [4]. They may be situated on one side or both sides in a vertical, transverse or inverted position, and may have a typical morphology resembling natural and normal dentition or have the form of odontogenic objects [5]. The incidence of such anomaly fluctuates between 0.3–0.8% in deciduous teeth, and between 1.5–3.9% in permanent teeth. [3, 6, 7, 8]; it has been noted in a Chinese population that the incidence of hyperdontia may reach even up to 7.8% [9]. Such a disorder occurs much more frequently in males than in females in the proportion between 2:1–6:1 [5].

This study aims to review current literature and present the aetiology, prevalence, diagnosis, treatment options and complications of supernumerary teeth.

STATE OF KNOWLEDGE

Classifications and divisions of supernumerary teeth. The literature distinguishes several divisions of supernumerary teeth considering their shape, morphological structure, location and incidence [7, 10, 11]. With regard to their number, they may be divided into single (Fig. 1) and multiple supernumerary teeth (Fig. 2) [11]. Considering the shape of such teeth, Primosch [12] distinguished eumorphic (supplemental) and dysmorphic (rudimentary) types. The eumorphic (invisible) type does not differ in structure and size from normal teeth, whereas the dysmorphic type refers to teeth with abnormal shape and size (Fig. 2) [10, 13].

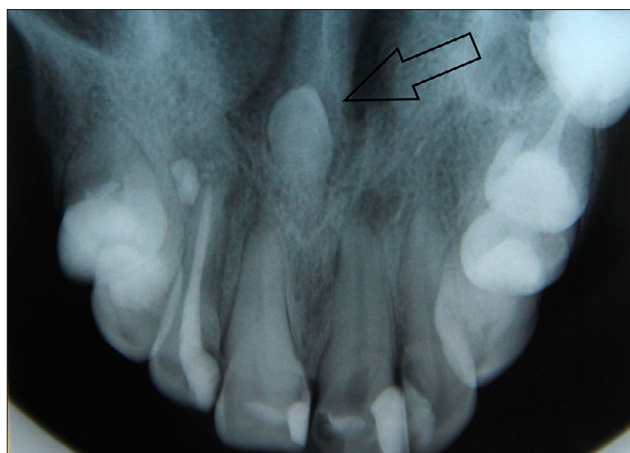

Figure 1. Occlusal radiograph of mesiodens

Address for correspondence: Kamil Tworkowski, Student Research Group “StuDentio” at the Department of Dentistry Propaedeutics, Medical University of Białystok, Poland
E-mail: kamil-tworkowski@wp.pl

Received: 1.02.2020; accepted: 15.03.2020; first published: 31.03.2020

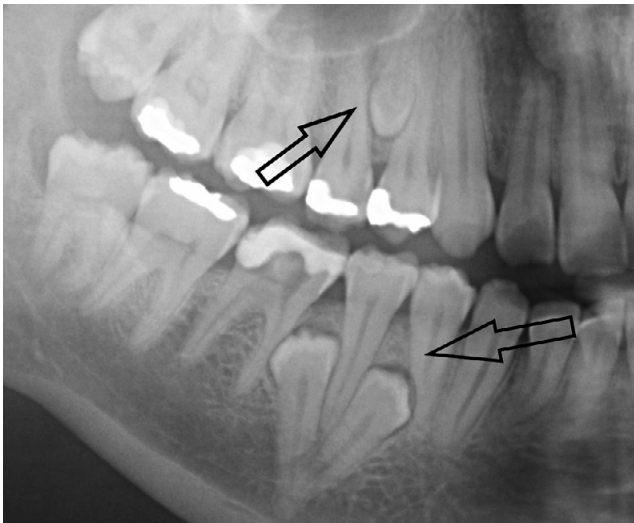


Figure 2. Three paramolars in both jaws on the radiograph, an eumorphic type in mandible, a dysmorphic type in maxilla

Depending on their structure, supernumerary teeth may be divided into several morphological types: conical, tuberculate, supplemental teeth and odontoma [7, 10, 11, 14]. The conical variation (31–75%) occurs most frequently in permanent dentition. Its development begins before or simultaneously with permanent incisors, with a complete apexogenesis of the roots, however, the dental long axis is usually abnormal. It frequently occurs in the form of mesiodens between upper central incisors, most frequently in the palatal location (Fig. 1). The tuberculate variation (12–28%) is bigger than the conical one and comprises one or more tubercles in its structure. Its development is delayed compared to conical teeth, with an incomplete process of apexogenesis or a lack of roots. The tuberculate type seldom occurs singly and is usually located in the region of upper incisors on the palatal side (Fig. 3). The supplemental variation (4–33%) primarily refers to permanent lateral incisors (Fig. 4), less frequently to premolars and molars. In the deciduous dentition, the

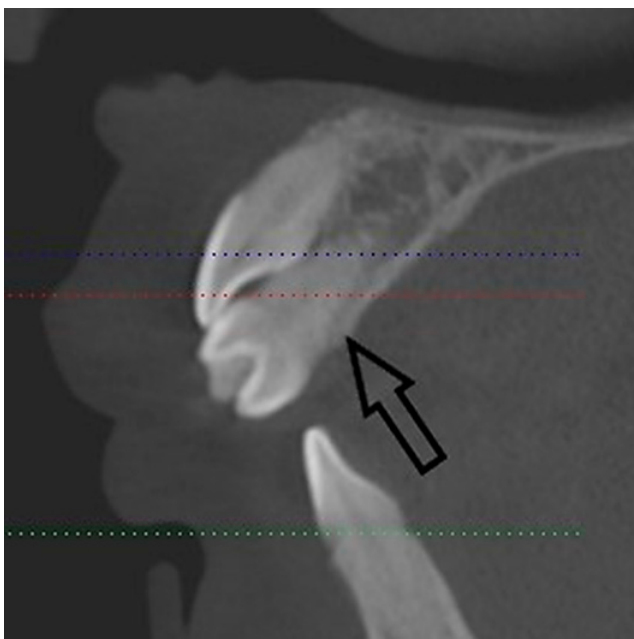


Figure 3. Supernumerary teeth in the anterior region of the jaw – CBCT sagittal plan

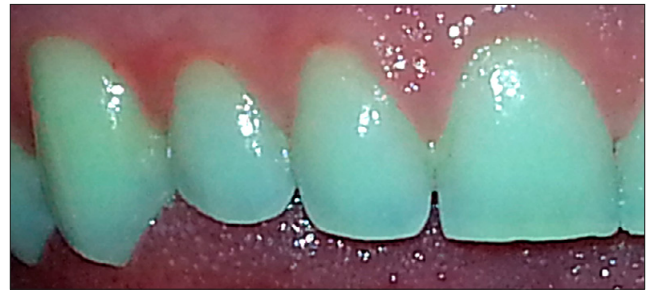

Figure 4. Supplemental upper lateral incisor

supplemental type is one of the most frequent, but these are rarely impacted teeth. The odontoma is a odontogenic tumour composed of the epithelium and the mesothelium, with the presence or the absence of mineralized tissues, comprising numerous odontoids, i.e. processes resembling small teeth or teeth buds [6, 7, 8, 10, 11].

Hyperdontia may also be divided into three categories depending on the location [7, 10, 11, 15, 16, 17, 18]:

- **Mesiodens** – a tooth located between upper central incisors with a conical or peg shape. It may occur as a single tooth or as multiple teeth, unilaterally or bilaterally, both totally erupted and impacted (Figs. 1 and 3).
- **Parapremolar** – a supernumerary tooth located in premolar area. The most frequent form is the supplemental variation.
- **Paramolar** – a supernumerary molar tooth, usually in vestigial form and with a small size, located buccally or palatally/lingually in the region of molars, most often in the interproximal space between upper second and third molars (Fig. 5).
- **Distomolar** – also referred to as fourth molar, situated distally or distolingually to wisdom teeth, it usually occurs in vestigial form and in small size. It rarely hinders or delays the eruption of other teeth (Fig. 6).

They may be situated vertically, transversally or in a rotated form.

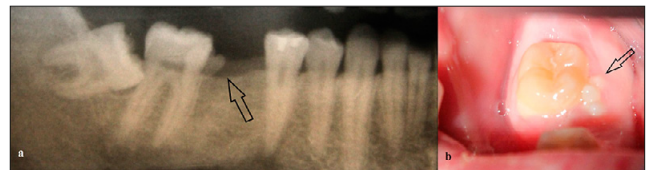


Figure 5. Paramolar near 47; on the radiograph (a); in the oral cavity (b)

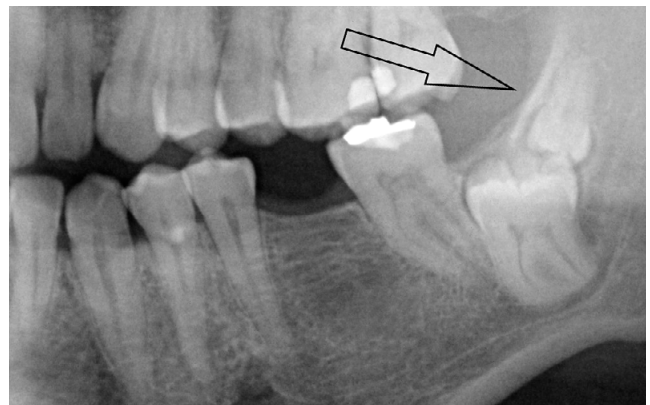


Figure 6. Distomolar in the left part of the lower jaw

Aetiology of supernumerary teeth. Despite numerous research studies, the aetiology of the formation of supernumerary teeth is not yet fully known. In the literature, the theories of atavism, dichotomy, hyperactivity of dental lamina, progress zone, unified aetiology and heredity have been described; however, not all of them are currently accepted [7, 10, 19, 20, 21]. At present, the most probable hypothesis for the development of hyperdontia is the hyperactivity of dental lamina [14]. According to this theory, supernumerary teeth may develop from the preserved remains of epithelial cells of the dental lamina following an incomplete resorption of epithelial cords, causing the development of a dysmorphic form. The eumorphic form may develop from an additional tooth bud formed from epithelial cells as a result of a proliferation in the lingual direction [10, 19, 20]. Factors stimulating an increased activity of the lamina may include circulation disorders, crowded dentition, the translocation of alveolar processes during the organogenesis, and tension of the bone tissue [22, 23].

The theory of dichotomy assumes the division of a tooth bud into two parts which are equal or unequal. The division may be caused by a genetic aberration or a trauma. A complete and equal division would cause the formation of a tooth with a similar size, whereas as a result of an incomplete division, a tooth with natural dimensions and a dysmorphic tooth are formed. Despite the fact that examples of an influence of traumas on the formation of supernumerary teeth have been described in the literature, there is no clear evidence in support of this theory [19].

Numerous authors refer to the cause-and-effect relationship between the heredity and the presence of supernumerary teeth. It may be concluded from conducted research that the heredity is related to the presence of supernumerary teeth, but not according to the simple Mendel's theory of heredity defining the type of heredity or the specific chromosome. So hyperdontia is a disorder related to polygenic inheritance and to the hyperactivity of dental lamina. Supernumerary teeth often constitute an element of developmental syndromes and disorders, such as amelogenesis imperfecta, cleft lip and palate, craniosynostosis, cleidocranial dysplasia, Crouzon syndrome, Franceschetti syndrome, Gardner syndrome, Down syndrome, Noonan syndrome, Rubenstein-Taybi syndrome, Zimmermann-Laband syndrome, Fabry syndrome, Ellis-Van Creveld syndrome, Ehlers-Danlos syndrome III and IV type, incontinentia pigmenti syndrome, oro-facio-digital type I, tricho-rhino-phalangeal syndrome, Rothmund-Thomson syndrome, Nance-Horan syndrome, Robinow syndrome, anophthalmia syndrome and Hallerman-Streiff syndrome [9, 14, 19, 22, 24, 25].

X-ray diagnostics. The basic examinations required for a correct diagnosis are x-ray images. The diagnostics is primarily based on panoramic radiographs, but dental and occlusal radiographs are also useful [3]. A panoramic radiograph is used as a screening aid providing information about the presence and the approximate position of supernumerary teeth. In the diagnostics of medial teeth [7], it is most useful to take two radiographs considering the parallax principle – in this way, the location of a supernumerary tooth (palatal, labial) and relationship to adjacent teeth [6] may be determined.

In recent years, the diagnostics using computed tomography, and in particular cone-beam computed tomography (CBCT) characterised by the accuracy and the

precision of location of supernumerary teeth, has become increasingly popular [7]. The advantages of CBCT include: multidimensional image, lower exposure to X-ray radiation compared to CT, and a shorter time of examination. One CBCT examination provides more information than several standard x-ray images which are bidimensional [11].

Supernumerary teeth which have mineralised at a late stage may cause diagnostic difficulties during X-ray examinations. In X-ray images, they are round translucencies delimited by a poorly mineralized bone crypt of a tooth bud [25].

Treatment. The treatment of hyperdontia depends on a specific patient case. Variables influencing the course of treatment include: type of dentition, degree of eruption of a supernumerary tooth and its influence on the position, and the eruption of permanent teeth. In view of multiple factors modifying the treatment, it should be based on complex planning and treatment. A dentist who diagnosed a case of hyperdontia should consult other specialist: surgeons, orthodontists or paedodontists [6, 7].

The spontaneous eruption of supernumerary teeth is extremely rare. The most frequently spontaneously erupting supernumerary tooth is the mesiodens in which passive eruption is recorded in only 25% of cases. If supernumerary teeth remain unerupted, they often cause a disturbed eruption of permanent teeth. In 75% of cases, permanent incisors erupt only after the extraction of the mesiodens. Therefore, if hyperdontia is diagnosed, the dentist must decide on a treatment plan which will be most advantageous in a specific patient case [6, 11].

In the case of deciduous dentition, the extraction of supernumerary teeth is not recommended. Deciduous supernumerary teeth usually erupt spontaneously [16]. A surgical intervention in such cases increases the risk of damage to permanent tooth buds, and consequently of a disturbed eruption of such teeth [6].

A different situation occurs in the case of mixed dentition during the period of child development in which the most intensive changes in jaw and alveolar process bone restructuring take place. Extractions of supernumerary teeth in this period stimulate the eruption of permanent teeth and favourably influence their position in the arch, which allows the avoidance of future orthodontic treatment [11, 26, 28].

The diagnosis of hyperdontia at the stage of permanent teeth requires surgical, and usually also orthodontic, treatment. At the moment when permanent teeth have an incomplete apexogenesis, the treatment may be limited to the surgical extraction of a supernumerary tooth. After the extraction of the supernumerary tooth, permanent teeth have a chance for a passive eruption and a spontaneous normal position in the dental arch [6, 10, 26].

After the growth period, when permanent teeth have reached the peak of development, the treatment consists of the extraction of a supernumerary tooth, and then the orthodontic positioning of permanent teeth. This usually takes place in the case of mesiodens which cause dental crowding, incorrect inclination, and translocation of upper incisors. In addition, if a supernumerary tooth was diagnosed only at the moment of eruption, after its extraction there remains an extensive space between adjacent teeth, which is also eliminated through orthodontic treatment [7].

There are situations where a supernumerary tooth is discovered in an adult, and its presence is not manifested

by any clinical signs. In such a case, hyperdontia is usually diagnosed accidentally through a panoramic radiograph [10]. If the supernumerary tooth does not result in any displacement of permanent teeth, and is not a cause of apical tissue diseases, the decision on its extraction should be a subject of discussion. In such a case, the extraction of a supernumerary tooth is quite often not necessary [8, 27].

Clinical consequences. Supernumerary teeth are often discovered accidentally, e.g. in control radiographs, in such cases they are asymptomatic. However, they frequently result in abnormalities related to adjacent teeth. In the literature, the most frequently described disorders include: the development of caries, cysts, resorption of roots, and periodontal problems, whereas in children the following disorders may be observed: retention of deciduous teeth or delayed eruption of permanent teeth. Moreover, the pressure of a supernumerary tooth on adjacent teeth may result in dental and occlusal disturbances, such as: dilaceration, rotation, tremas, diastema, and may be a cause of pulpitis by the pressure on the neurovascular bundle [2]. As stated by the authors, apart from the above-mentioned disorders, a dentist may encounter: ectopic eruption, problems with correct occlusion, incorrect position of teeth in the arch, higher retention of dental plaque and aesthetic impairment, or even a decrease of self esteem, especially with the presence of supernumerary teeth in the anterior region. The presence of supernumerary teeth in children may result in persistent deciduous teeth, or in a delayed eruption of permanent teeth [3, 7, 10, 13, 26, 28, 29, 30].

CONCLUSIONS

Supernumerary teeth may cause aesthetic deformities and functional impediments, therefore early diagnosis and interdisciplinary intervention are important to minimize consequences to the developing dentition. The clinicians should be mindful of such signs as delayed eruption, alterations in the eruptive pattern, shift in the midline, or dental crowding.

REFERENCES

1. Szczepkowska A, Osica P, Janas-Naze A. Double teeth overtime in the front stretch of the jaws on the 9-year-old boy – a description of the case. *J Educ. Health Sport.* 2016; 6(5): 111–118. <http://dx.doi.org/10.5281/zenodo.51318>
2. Pietrzak P, Śmiech-Słomkowska G. Postać mnoga zębów nadliczbowych – opis przypadku. *Mag Stomatol.* 2018; 28(1): 48–51.
3. Diaz A, Orozco J, Fonseca M. Multiple hyperodontia: Report of a case with 17 supernumerary teeth with non syndromic association. *Med Oral Patrol Oral Cir Bucal.* 2009; 14(5): 229–231.
4. Gurler G, Delilbasi C, Delilbasi E. Investigation of impacted supernumerary teeth: a cone beam computed tomography (CBCT) study. *J Istanbul Univ Fac Dent.* 2017; 51(3): 18–24. <https://doi.org/10.17096/jiufd.20098>
5. Biedziak B, Kurzawski M, Zabel M. Późne tworzenie zębów nadliczbowych – opis przypadków. *Nowa Stomatologia.* 2006; 4: 170–173.
6. Russell KA, Folwarczna MA. Mesiodens — diagnosis and management of a common supernumerary tooth. *J Can Dent Assoc.* 2003; 69(6): 362–366.
7. Ata-Ali F, Ata-Ali J, Peñarrocha-Oltra D, Peñarrocha-Diago M. Prevalence, etiology, diagnosis, treatment and complications of supernumerary teeth. *J Clin Exp Dent.* 2014; 6(4): 414–418. <https://doi.org/10.4317/jced.51499>
8. Tanaskovic-Stankovic S, Tanaskovic I, Jovicic N, Miletic-Kovacevic M, Kanjevac T, Milosavljevic Z. The mineral content of the hard dental tissue of mesiodens. *Biomed Pap Med Fac Univ Palacky Olomouc Czech Repub.* 2018; 162(2):149–153. <https://doi.org/10.5507/bp.2018.017>
9. Mallineni SK, Jayaraman J, Wong HM, King NM. Dental development in children with supernumerary teeth in the anterior region of maxilla. *Clin Oral Invest.* 2019; 23(7): 2987–2994. <https://doi.org/10.1007/s00784-018-2709-2>
10. Rajab LD, Hamdam MA. Supernumerary teeth: review of the literature and a survey of 152 cases. *Int J Paediatr Dent.* 2002; 12(4): 244–254. <https://doi.org/10.1046/j.1365-263x.2002.00366.x>
11. Garvey MT, Barry HJ, Blake M. Supernumerary teeth--an over-view of classification, diagnosis and management. *J Can Dent Assoc.* 1999; 65: 612–616.
12. Primosch RE. Anterior supernumerary teeth--assessment and surgical intervention in children. *Pediatr Dent.* 1981; 3: 204–215.
13. Janas A. Nadliczbowe zęby środkowe (mezjodensy) przyczyną zaburzeń w prawidłowym wyrzynaniu zębów przyśrodkowych siecznych stałych w szczytce. *Implantoprotetyka.* 2009; 10(1): 41–43.
14. Xi L, Fang Y, Junjun L, Wenping C, Yumei Z, Shouliang Z, Shangfeng L. The epidemiology of supernumerary teeth and the associated molecular mechanism. *Organogenesis.* 2017;13(3): 71–82. <https://doi.org/10.1080/15476278.2017.1332554>
15. Nayak G, Shetty S, Singh I, Pitalia D. Paramolar – A supernumerary molar: A case report and an overview. *Dent Res J (Isfahan).* 2012; 9(6): 797–803.
16. Parolia A, Kundabala M, Dahal M, Mohan M, Thomas MS. Management of supernumerary teeth. *J Conserv Dent.* 2011; 14: 221–4.
17. Shah A, Gill DS, Tredwin C, Naini FB. Diagnosis and management of supernumerary teeth. *Dent Update.* 2008 Oct; 35(8): 510–2, 514–6, 519–20. <https://doi.org/10.12968/denu.2008.35.8.510>
18. Arathi R, Ashwin R. Supernumerary teeth: a case report. *J Indian Soc Pedod Prev Dent.* 2005; 23(2): 103–5. <https://doi.org/10.4103/0970-4388.16453>
19. Anthonappa RP, King NM, Rabie AB. Aetiology of supernumerary teeth: a literature review. *Eur Arch Paediatr Dent.* 2013; 14(5): 279–288. <https://doi.org/10.1007/s40368-013-0082-z>
20. Cho SY, So FH, Lee CK, Chan JC. Late forming supernumerary tooth in the premaxilla: a case report. *Int J Paediatr Dent.* 2000; 10(4): 335–40. <https://doi.org/10.1046/j.1365-263x.2000.00228.x>
21. Anil P. Management of supplemental permanent maxillary lateral incisor: a rare case. *IOSR J Dent Med Sci.* 2012; 1(6): 24–26.
22. Gurdziel K, Minch L, Minch E. Późne powstanie mnogich zawiązków nadliczbowych zębów przedtrzonowych w zuchwie. *Stomatologia Współczesna.* 2014; 21(2): 21–26.
23. Górniak D, Jarczyńska I, Zięba Z. Nadliczbowość zębów – przegląd piśmiennictwa oraz opis trzech leczonych przypadków. *Ortop Szczęk Ortod.* 2001; 1: 17–23.
24. Cammarata-Scalisi F, Avendaño A, Callea M. Main genetic entities associated with supernumerary teeth. *Arch Argent Pediatr.* 2018; 116(6): 437–444. <https://doi.org/10.5546/aap.2018.eng.437>
25. Lubinsky M, Kantaputra PN. Syndromes with supernumerary teeth. *Am J Med Genet A.* 2016; 170(10): 2611–2616. <https://doi.org/10.1002/ajmg.a.37763>
26. Omer RS, Anthonappa RP, King NM. Determination of the optimum time for surgical removal of unerupted anterior supernumerary teeth. *Pediatr Dent.* 2010; 32(1): 14–20.
27. Wędrzychowska-Szulc B, Janiszewska-Olszowska J, Węsierska K, Sporniak-Tutak K. Kliniczny i radiologiczny obraz pacjentów z nadliczbowymi zębami przedtrzonowymi oraz możliwości ich leczenia. *Czas. Stomatol.* 2010; 63(12): 762–772.
28. Aggarwal M, Singh C, Masih U, Kour G. Supernumerary Teeth and their Management – Report of 3 Cases. *Int J Oral Health Med Res.* 2016; 3(1): 143–147.
29. Lee JY. Dentigerous Cyst Associated With a Supernumerary Tooth. *Ear Nose Throat J.* 2020; 99(1): 32–33. <https://doi.org/10.1177/0145561318823638>
30. Bagińska J, Rodakowska E, Piszczatowski S, Kierklo A, Duraj E, Konstantynowicz J. Dens invagination and root dilaceration in double multilobed mesiodentes in 14-year-old patient with anorexia nervosa. *Folia Morphol (Warsz).* 2017; 76(1): 128–133. <https://doi.org/10.5603/FM.a2016.0046>