



World News of Natural Sciences

An International Scientific Journal

WNOFNS 24 (2019) 184-188

EISSN 2543-5426

The Menacing Misfit of the Dentition: A Case of Premolar Molarization

**Geon Pauly^{1,*}, Brilliant Raphael¹, Roopashri Rajesh Kashyap²,
Raghavendra Kini³, Prasanna Kumar Rao⁴, Gowri P. Bhandarkar²**

¹Department of Oral Medicine and Radiology, A J Institute of Dental Sciences, Kuntikana, Mangaluru, Karnataka, India

²Department of Oral Medicine and Radiology, A J Institute of Dental Sciences, Kuntikana, Mangaluru, Karnataka, India

³Professor and Head, Department of Oral Medicine and Radiology, A J Institute of Dental Sciences, Kuntikana, Mangaluru, Karnataka, India

⁴Professor, Department of Oral Medicine and Radiology, A J Institute of Dental Sciences, Kuntikana, Mangaluru, Karnataka, India

*E-mail address: geonpauly@gmail.com

*Tel: +918905102696

ABSTRACT

Morphological variations can occur in human teeth. Developmental dental disorders occur either due to the abnormalities in the differentiation of the dental lamina and the tooth germs (anomalies in number, size and shape) or to abnormalities in the formation of the dental hard tissues (anomalies in structure). When such variations occur, they are more interesting to clinicians, anthropologists, and forensic dentists. Now, fusion and gemination aren't an uncommon finding and affected mostly primary dentition and the permanent maxillary incisors. However, gemination of the posterior teeth is rare; permanent all the more than primary teeth. Gemination of a premolar is one such rare anomaly that arises when a single premolar tooth bud attempts to divide. Here, we present a case of gemination associated with the mandibular second premolar, showing a prodigious and unusual crown and root morphology.

Keywords: Fused Teeth, Bicuspid, Molar, Premolar Molarization

1. INTRODUCTION

Gemination, Twinning or Schizodontism is a developmental anomaly affecting the tooth shape which is often synonymous or confused with macrodontia or fusion.¹ Gemination is defined as an attempt by a single tooth bud to divide, with a resultant formation of either a large tooth with a bifid crown or two completely divided teeth throughout the crown and root.² Gemination rarely occurs in mandibular second premolar region and can cause the appearance of molar like premolar. This anomaly, known as ‘molarization of premolars’, has been described in the dental literature infrequently.³

Such isolated form of gemination induced macrodontia of premolars have rarely been reported. As of 2014, as reported by Mangla et al, only eight cases of isolated macrodontia of second premolars have been reported in the literature; five of which have shown bilateral occurrence making unilateral occurrence an even scarcer entity.⁴ Hereby, we present a case of premolar molarization in a 16-year-old girl who had come for routine dental check-up.

2. CASE REPORT

A 16-year-old female patient was referred to our department from a peripheral camp for routine dental check-up. On clinical examination, the patient had an overall good oral hygiene except the presence of mild extrinsic stains more on the lingual aspects. Incidental finding revealed, macrodontia of the mandibular second premolar on the right side. The crown was wide mesio-distally and its dimensions were almost the size of the adjacent first molar [Figure 1 - A]. No teeth were missing in the quadrant or the arch inclining our diagnosis more towards gemination over fusion. A radiograph taken revealed a broad single root with a single pulp chamber and the crown appeared like two crowns fused together forming a single crown with multiple cusps [Figure 1 - B]. Thus, a final diagnosis of gemination was established. Since, the patient had no discomfort and no findings related to the tooth no treatment was advised for the same. The patient and her parents were educated regarding the anomaly and its future implications and were referred to the department of pedodontics for oral prophylaxis.

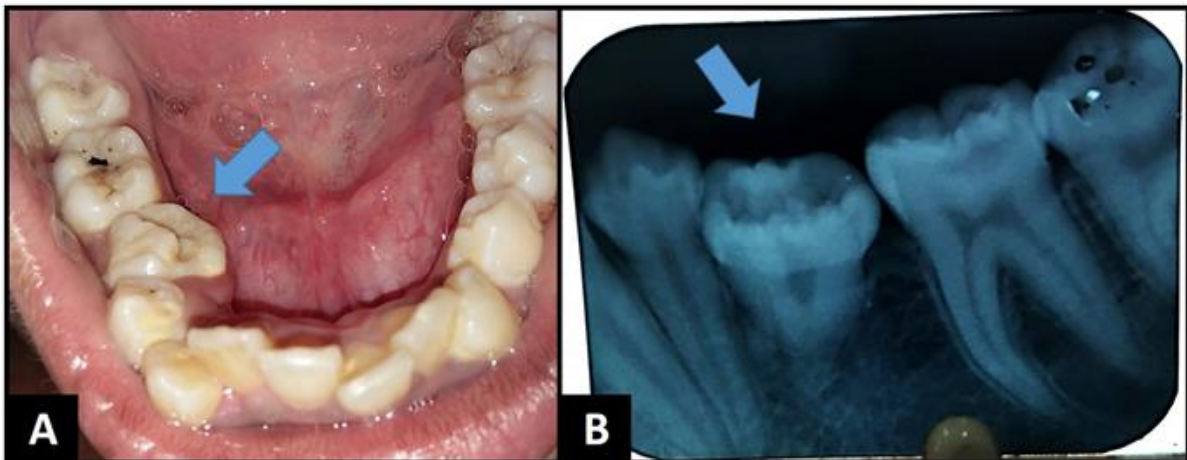


Figure 1. Premolar Molarization: **A** – Clinical View. **B** – Radiographic View.

3. DISCUSSION

A diverse range of conglomeration exists in the genre ‘morphology of the teeth’ amongst the mammalian class. Teeth are particularly used in anthropological research because they have the advantage of preservability (in fossils and forensic records), observability (in the living, skeletons, and fossils), variability (measurement that varies between populations and within a population), and heritability (a strong genetic basis underlying the tooth development and trait expression).⁵

Dental organogenesis disorders manifest as alterations in the number, size or form of teeth. When dental size and anatomy present characteristics that deviate from what is supposed to be accepted range of normality, they are termed anomalies.⁶ Gemination consists of an aborted attempt by a single tooth bud to divide. Neville et al, defined gemination as a single enlarged tooth or joined (double) tooth in which the tooth count is normal when the anomalous tooth is counted as one as was in our case.^{7, 8}

Although environmental factors such as trauma, vitamin deficiencies, systemic diseases and certain genetic predisposition have been suggested as possible causes, the exact cause of gemination is unknown. Grover & Lorton claim that local metabolic interferences, which occur during morpho-differentiation of the tooth germ, may be a probable cause.^{9, 10} Now, most times on clinical examination differentiating a gemination from a fusion can be daunting task, and it is usually confirmed by counting the number of teeth in the area and radiological evaluation.¹¹

Milazzo and Alexander for the purpose of a differential diagnosis have suggested counting of the teeth: A normal number of teeth in the dental arch indicates gemination, while a reduced number points towards fusion. An exception are the cases where there is a normal tooth fused with a supernumerary one, or when there is a gemination with hypodontia. Hence, as in the present case, although the features attribute more towards gemination, fusion as such cannot be completely ruled out as well. Various authors cite that the term “double teeth” can be generally used to mention teeth falling under this category. There have also been suggestions that the term gemination and fusion should be discontinued, and all of these anomalies should be termed twinning.¹²

On the flip side a radiographic evaluation can be far more accurate than the clinical counterpart. The consideration is the difference in root configuration often seen between fusion and gemination. Like, in the case of fusion there are usually two separate root canals, whereas in gemination there is usually one large common root canal.¹¹ Therefore, this case report resembled clinically and radiographically that of gemination of the second premolar; sharing a pulp chamber and root canals, and the presence of two fused crowns giving it an aberrant appearance.

There is a suggested scheme in literature to classify germination. It is given as: Gemination (cleavage of a single tooth germ) - partial cleavage (true-gemination); complete cleavage (twinning) clearly suggesting that our case would fall under the category of twinning.¹³

From a clinical stand point, a geminated tooth in anterior region may blemish aesthetics and the presence of a groove can also cause caries and a high plaque accumulation. An impacted supernumerary tooth can also lead to complications like resorption of adjacent teeth, cystic spaces, and delayed eruption. Hence, a geminated supernumerary tooth is more likely to cause complications due to its atypical anatomy.¹⁴

The clinical problems are more obviously a concern in permanent dentition than in primary for they do not shed away. Particularly if the anterior teeth are involved, problems vary

from tooth malalignment, spacing problems, arch asymmetry, aesthetic problems, periodontal involvement and interference with the eruption of the adjacent tooth. Presence of deep groove in some cases of gemination makes them susceptible to caries and periodontal diseases. In our patient, the anomaly caused decrease in mandibular arch space and thus subsequent crowding of anterior teeth.

However, in permanent dentition, the treatment of choice can be planned as per the patient's need. Cases wherein endodontic treatment followed by surgical division of crown has also reported. In some cases, extraction with prosthetic replacement is advised and also reducing tooth structure mesio-distally and placing a composite restoration to give the tooth a normal appearance. Our patient was not concerned about the aesthetic problems due to macrodontia; therefore, other treatment such as oral prophylaxis was essentially carried out.¹⁵

4. CONCLUSION

As renowned philosopher, psychologist and physician William James had once remarked – “To study the abnormal is the best way of understanding the normal.” Clearly, the professionals need to have a thorough knowledge of these anomalies for accurate diagnosis and executing the right treatment plan, for a multidisciplinary approach is required comprising of conservative, endodontic, prosthodontics, periodontic and orthodontic for the successful management of these cases.

References

- [1] Pauly G, Kashyap RR, Rao PK, Kini R, Bhandarkar GP. The Twin Teeth – A Case of Gemination. *J Dent Oral Biol.* 2017; 2(11): 1072
- [2] Rajesh Ebenezer AV, Venkatesh A, Mary AV, Mohan AG. An Unusual Occurrence of Bilaterally Geminated Mandibular Second Premolars Resulting in Premolar Molarization: A Case Report. *J Conserv Dent.* 2013; 16: 582-584
- [3] Canut JA, Arias S. Molarization of The Lower Second Premolars. *Angle Orthod.* 1999; 69: 380-381
- [4] Mangla N, Khinda VIS, Kallar S, Brar GS. Molarization of Mandibular Second Premolar. *International Journal of Clinical Pediatric Dentistry* 2014; 7(2): 137-139
- [5] Nagaveni NB, Umashankara KV, Radhika NB, Mohan M. Molarization of the Mandibular Second Premolar in an Indian Patient: Report of a Rare Case. *Ann Bioanthropol* 2015; 3: 33-35
- [6] Mora MCM, Carmona MVB, Lujan MTB. Molarization and Development of Multiple Supererary Teeth in the Premolar Region. *J Dent Child* 2004; 71(2): 171-174
- [7] Neville BW, Damm DD, White DH: Color Atlas of Clinical Oral Pathology. 2nd Ed. Ontario: BC Decker, 2003: 62.
- [8] Vijay G, Raghavan V. Premolar Gemination: Report of a Rare Case. *Libyan Dent J.* 2013, 3: 1-3

- [9] PS Gover, L Lorton. Gemination and Twinning in Permanent Dentition. *Oral Surg Oral Med Oral Pathol.* 1985; 59: 313-318
- [10] Nandini DB, Deepak BS, Selvamani M, Puneeth HK. Diagnostic Dilemma of a Double Tooth: A Rare Case Report and Review. *J Clin Diagn Res.* 2014; 8(1): 271-272
- [11] Camargo AJ, Arita ES, Watanabe PCA. Fusion or Gemination? An Unusual Mandibular Second Molar. *Int J Surg Case Rep.* 2016; 21: 73-77
- [12] Venkatesh A, Goel S, Wadhwan V, Bansal V. Gemination of a Mandibular Third Molar: A Rare Case Report. *SRM J Res Dent Sci.* 2016; 7: 121-123
- [13] Jain AA, Yeluri R, Munshi AK. Gemination or Fusion? A Diagnostic Dilemma. *Dentistry* 2014; 4(2): 1-2
- [14] Soin A, Sharma G, Soin G, Raina A, Mutneja P, Nagpal A. Multiple Geminated Supernumerary Premolars: A Rare Case Report. *Case Reports in Dentistry* 2015; 3(1): 1-4
- [15] Rao PK, Veena KM, Chatra L, Shenai P. Twin Tooth on Either Side: A Case Report of Bilateral Gemination. *Ann Med Health Sci Res.* 2013; 3(2): 271-273