

# Pathologic fractures in the course of a primary hyperparathyroidism

Arun Prashar<sup>1</sup>, Wioletta Dudek<sup>2</sup>, Andrzej Prystupa<sup>2</sup>, Ewa Kurys-Denis<sup>3</sup>, Witold Krupski<sup>3</sup>,  
Jadwiga Sawa-Sierocińska<sup>4</sup>, Jerzy Mosiewicz<sup>2</sup>

<sup>1</sup> Scientific Society of Students, Medical University, Lublin, Poland

<sup>2</sup> Department of Internal Medicine, Medical University, Lublin, Poland

<sup>3</sup> Department of Radiology, Medical University, Lublin, Poland

<sup>4</sup> Department of Histopathology, Medical University, Lublin, Poland

Prashar A, Dudek W, Prystupa A, Kurys-Denis E, Krupski W, Sawa-Sierocińska J, Mosiewicz J. Pathologic fractures in the course of a primary hyperparathyroidism. *J Pre-Clin Clin Res.* 2012; 6(1): 64-67.

## Abstract

A 49-year-old patient initially presented to the hospital with fractures seemingly suffered from relatively minor trauma. Imaging and laboratory tests showed abnormalities consistent with dysfunctional mineralization of bone. Computed tomography revealed a mass localized in the inferior parathyroid glands that was removed during a subtotal parathyroidectomy. Follow-up with histopathological studies determined the mass to be a parathyroid adenoma; subsequently, the diagnosis of osteitis fibrosa cystica as a sequela of advanced primary hyperparathyroidism was ascertained. The presented report discusses an extremely severe/advanced case of primary hyperparathyroidism that caused extensive bone demineralization in which several pathologic fractures occurred.

## Key words

primary hyperparathyroidism, parathyroid adenoma, osteitis fibrosa cystica, pathologic fracture

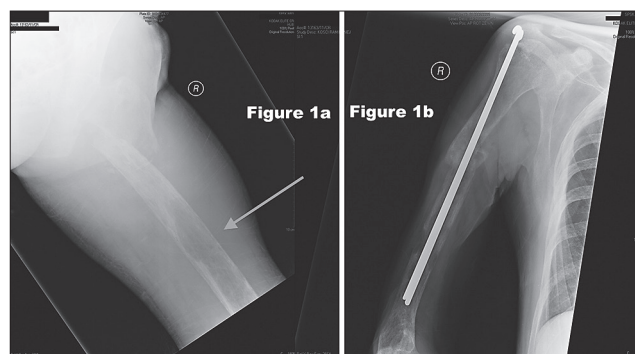
## INTRODUCTION

Primary hyperparathyroidism occurs as a result of a parathyroid adenoma in 85% – 90% of cases. In the residual cases, less than 15% are due to hyperplasia of 2 glands or more, and cancer as a cause in less than 1% of cases [1, 2]. Manifestations of this disease are mainly due to calcium and phosphate imbalances that occur as a result of excessive parathyroid hormone produced by chief cells of the parathyroid gland. Parathyroid hormone functions to increase serum calcium and decrease serum phosphate by physiologically manipulating intestinal absorption, renal ion transport and reabsorption, levels of Calcitriol [1,25 (OH)<sub>2</sub> D], and by increasing bone resorption. When there is an imbalance in these hormones and processes, very severe consequences may occur, such as pathologic fractures. This skeletal manifestation of advanced hyperparathyroidism is known as osteitis fibrosa cystica (also known as Von Recklinghausen disease of bone). In osteitis fibrosa cystica (OFC) the excessive osteoclastic activity from the increased parathyroid hormone causes rarefaction of bone with fibrous bone degeneration, as well as cyst and fibrous nodule formation [1].

There are a multitude of causes that may lead to dysfunctional bone remodeling and fractures, the pathophysiology of which is often similar, and as a result they frequently mimic each other clinically. Therein lies the difficulty in economically and efficiently discerning accurately between a wide spectrum of possibilities. The presented paper concentrates on providing a salient and clinically applicable insight.

## CASE REPORT

A 49-year-old patient was initially admitted to the trauma department in a hospital for injuries incurred during a sudden collapse. The patient was writhing in pain, complaining of sustained and sharp pains in the right arm and right leg. Based on physical examination, the physicians surmised that the patient had fractures of the right humeral shaft and right femoral trochanter. As expected, x-rays confirmed that the injuries the patient sustained were indeed fractures, although it was slightly confounding to find the presence of cystic changes in bone (Fig.1). Chest x-rays were unremarkable with a normal appearing hilum and mediastinum. It no longer seemed tenable that the patient's fractures were exclusively the result of trauma, but were more plausibly pathologic in nature. This prompted examination of the patient's blood. Laboratory tests revealed elevated levels of parathyroid hormone (PTH) of 1900 pg/mL (normal = 14-72 pg/mL),



**Figure 1a.** Fractured neck of the right femur. Exhibits generalized osteoporosis, right humerus after internal fixation, periosteal resorption of bone, and a large tumor at metaphysis (arrow)  
**Figure 1b.** Fractured shaft of the femur. Exhibits generalized osteoporosis, and multiple tumors are prevalent

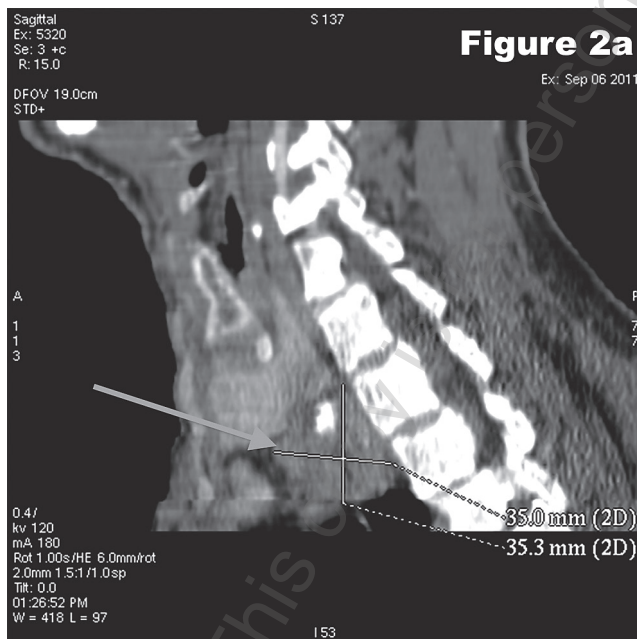
Address for correspondence: Arun Prashar Department of Internal Medicine, Medical University, Staszica 11, 20-081 Lublin, Poland.  
E-mail: prasharmd@gmail.com

Received: 20 April 2012; accepted: 14 June 2012

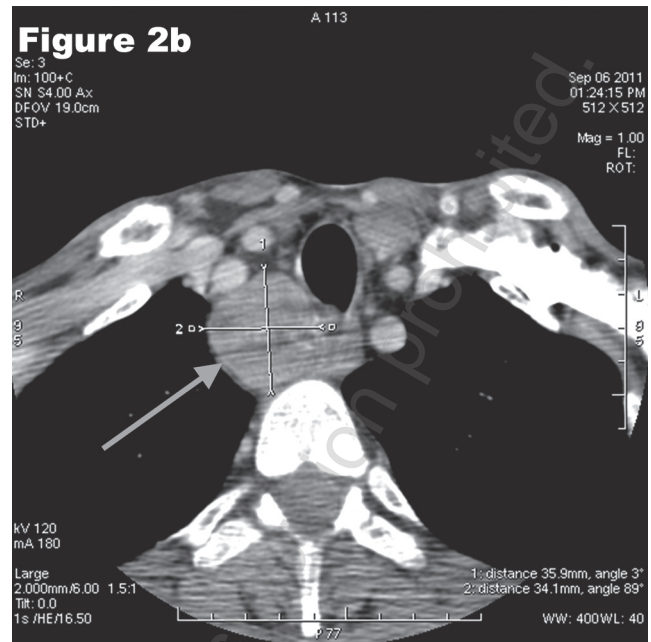
calcium of 3.30 (normal 2.15-2.50 mmol/L), and alkaline phosphatase (ALP) of 473 U/L (normal = 40-129 U/L), but normal levels of prostate-specific antigen (PSA) of 0.877 (age adjusted normal range is less than 2.5 ng/mL for 49-year-olds). Free serum thyroid hormone levels were also measured and found to be normal: T3 – 4.20 pmol/L (normal 4.0-8.3 pmol/L), T4 – 18.59 pmol/L (normal 9.0-20.0 pmol/L). The patient was also found to have normocytic anemia with hemoglobin levels of 9.7 g/dL and mean corpuscular volume of 96 fl. It was conjectured that hyperparathyroidism was the underlying mechanism causing these changes.

Further investigation was conducted using computed tomography with contrast (in 2 mm sections) from the sphenoid bone to the level of T4. A well-demarcated, pathologic mass (Fig.2) was found on the posteroinferior aspect of the right lower lobe of the parathyroid glands. The mass was hypodense relative to the adjacent thyroid parenchyma with focally located calcifications. Primary hyperparathyroidism due to a parathyroid adenoma seemed most probable at this point. It is also noteworthy that during ultrasonography, the patient was found to have an enlarged liver and prostate, as well as findings suggestive of a polycystic left kidney. The patient's liver was assessed to be functioning properly, with blood levels of ALT at 10.0 U/L and AST at 11.9 U/L. Kidney function was ascertained as normal, with blood creatinine levels at 1.4 mg/dL, even in light of a slight elevation in blood levels of urea at 52.2 mg/dL (normal 19-44 mg/dL). Both fractures were repaired by open reduction with internal fixation.

After one month of post-operative in-patient care, the patient recuperated and was transported to the hospital's Department of Surgery to undergo a subtotal parathyroidectomy. Chest x-rays were again conducted and were unremarkable with normal appearing lung parenchyma, mediastinum, and hilum of the lungs. Upper endoscopy was also performed which was remarkable for the presence of inflammation in the lower third of the esophagus, numerous gastric erosions, and the presence of an ulcer on the posterior



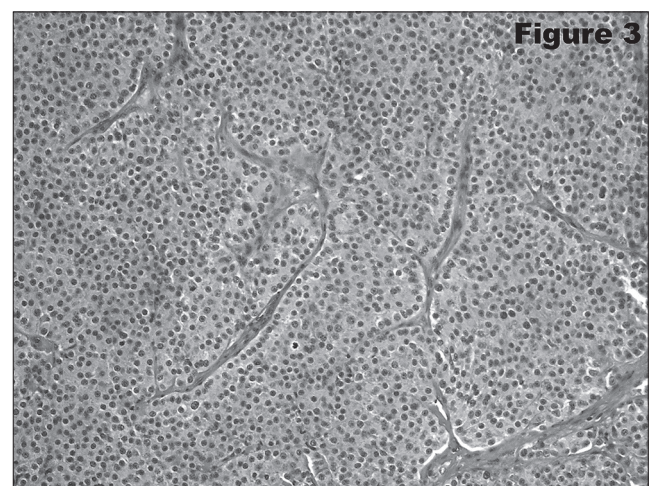
**Figure 2a.** Multiplanar reconstructed image from a computed tomography scan showing the dimensions of the parathyroid tumor (arrow) located at the posteroinferior aspect of the right lobe of the thyroid gland



**Figure 2b.** Axial image from a computed tomography scan showing the tumor (arrow) compressing the trachea

wall of the duodenum surrounded by inflamed mucosa. Blood examinations conducted preoperatively showed a sodium level of be 135.0 mmol/L, potassium – 3.75 mmol/L, calcium – 3.30 (normal 2.15-2.50 mmol/L), and phosphate – 0.84 mmol/L (normal 0.84-1.45 mmol/L). During the procedure, the surgeons enucleated an encapsulated mass from the right lobe of the inferior parathyroid glands.

After the procedure, the excised mass was sent for further histopathologic examinations, where the presence of chief cells was found. Furthermore, the mass was determined to be a parathyroid adenoma, and the diagnosis of primary hyperparathyroidism; subsequent development of osteitis fibrosa cystica was ascertained (Fig.3). After the surgery, the patient developed hungry bone syndrome, evidenced by blood examinations that showed hypocalcaemic and hypophosphataemic levels of 1.690 mmol/L and 0.48 mmol/L, respectively.



**Figure 3.** Histopathological section of the biopsied tissue prepared with hematoxylin and eosin staining. Histopathological section shows the predominance of chief cells within the parathyroid adenoma.



The patient was then transferred to the Department of Internal Medicine to treat the post-operative hypocalcaemia. Upon arrival, the patient visibly seemed emaciated and cachectic (patient's weight could not be measured due to the patient's fragile and delicate state). The patient was also experiencing extremely painful episodes of tetany. Initial examination of the patient's blood showed hypocalcaemia (calcium of 1.740 mmol/L) and hypophosphataemia (phosphate of 0.55 mmol/L). It was also around this time that the patient also began to complain of pain and numbness in their extremities. Upon further physical examination it was deduced that the patient had a new onset of pathologic fractures. Radiography confirmed that a fracture had occurred in the shaft of the left humerus, as well as another fracture inferiorly to the lesser trochanter of the left femur. The phenomenon of generalized hypodensity of bones was also witnessed to be still prevalent.

While in the Department of Internal Medicine, the patient underwent palliative treatment to relieve the pain, with regimens consisting of Ketonallem (Ketoprofen), Poltram (Tramadol), Durogesicpachts (Fentanyl). The patient's overriding problem of low levels of calcium was aggressively managed to rectify the levels of calcium and PTH through manipulation of the patient's urine output. This was achieved in combination with treatment using varying regimens of calcium and vitamin D supplements. This consisted of Calperos 1000 (oral calcium supplement), Alfadiol (Vitamin D3 supplement), Calcium Chloratum (intravenous calcium supplementation). The patient was also administered Clexane (enoxaparin) and Intravenous magnesium sulfate as prophylactic measures to counteract the development of a deep vein thrombosis (from prolonged immobilization) and hypomagnesia (from low levels of PTH), respectively. After obtaining normal levels of calcium of 2.204 mmol/L and PTH of 64 pg/mL (normal range of PTH 11-67 pg/mL) the patient was transferred to the Orthopedic Department to treat the new onset of fractures.

## DISCUSSION

Fractures are cracks in bones commonly presenting with pain, swelling, ecchymosis, crepitation, deformity, and abnormal motion. Most fractures result from a single application of significant force to otherwise normal bone [1]. However, pathologic fractures are injuries where the force applied is disproportionately small relative to their severity as the result of some disease process weakening the bone. Regardless of the cause or the underlying mechanism, the protocol for the treatment of the fractures is uniform. Principally, it involves closed or open reduction (surgical correction), together with cast-mediated immobilization to restrict bearing of weight and facilitate proper healing [3]. It would also be judicious to treat the underlying cause of the pathologic fractures to prevent future occurrences.

In making the assertion that fractures are pathologic in nature, it would therefore be facile to start with standard radiography or even dual-emission x-ray absorptiometry (DXA) techniques to assess and analyze bone mineral density [4]. If anomalies arise consistent with one's suspicions it may be worthwhile to pursue ancillary measures to assist with corroboration with the visual evidence. This may include determining the levels of serum electrolytes (primarily

calcium and phosphate) and hormones involved in the formation and resorption of bone. This generally includes the parathyroid hormone (PTH), estrogen (especially in females), calcitriol (vitamin D), and possibly calcitonin. To further substantiate one's claim, it may be prudent to probe for biochemical markers related to bone turnover [5, 6]. This includes (but is not limited to) serum bone specific alkaline phosphatase (ALP), osteocalcin, carboxy terminal telopeptide of type I collagen, as well as urinary deoxypyridinoline cross-links (DXP), urinary DXP to urinary creatinine ratio, urinary calcium to urinary creatinine ratio, transforming growth factor beta (TGF- $\beta$ ), insulin-like growth factors I & II (IGF-1, IGF-2), fibroblast growth factors, and platelet-derived growth factors [7, 8].

Tumour markers, such as CEA, CA 15-3, CA 125, ALP, and prostate-specific antigen (PSA), are all also effective in this capacity [1, 9]. Unfortunately, these markers are not very specific and that information alone may be too ambiguous; however, used adjunctively with other laboratory examinations, it may provide a clearer trajectory. As more evidence was gathered by using the aforementioned methods, confidence in the diagnosis as being correct increased and the notion was subsequently entertained that a neoplastic growth was culpable. This highly plausible notion was duly confirmed by using computed tomography (and also later histopathologic examination).

Neoplasms have long been implicated in the development of pathologic fractures, the mechanisms of which are frequently the results of direct effects by primary bone tumors or metastases to bone, or are a consequence of excessive secretion of hormones/hormone-like substances by neoplastic cells [10, 11, 12]. In primary hyperparathyroidism, excessive levels of parathyroid hormone mediate the formation of pathologic fractures. Primary hyperparathyroidism occurs as a result of a parathyroid adenoma in 85% to 90% of cases. Osteitis fibrosa cystica (OFC) is the skeletal sequela of advanced primary hyperparathyroidism [1, 2]. The World Health Organization under its ICD-10 classification system has listed OFC under category E21.0 – 'Primary hyperparathyroidism' [13]. The presence of excessive parathyroid hormone overstimulates osteoclasts which, in turn, leads to an increase in bone turnover with bone resorption predominating over bone formation, resulting in the rarefaction of bone. The changes in bone are substantial with the cortical thickness decreasing and cortical porosity increasing, along with the occurrence of cystic and fibrous nodule formations. The latter mentioned change is commonly referred to as to the formation of 'brown tumours'. Osteoclasts and blood pigments accumulate and line the cysts, imparting a reddish-brown hue. This designation as a tumour is a misnomer as it is not a true neoplasm. The marrow may be replaced by vascularized fibrous tissue and osteoclast-like giant cells. There may be multiple brown tumours that may arise in the pelvis, ribs, clavicles, spine, and extremities. The summation of these abnormalities compromises the architecture and (subsequently) strength of bone, which prompts its increased fragility [1, 14, 15]. Clinically, it can present with ostealgia, bone fractures (most commonly in the arms, legs, or the spine), kidney stones, constipation, and lethargy. Laboratory examinations of blood characteristically exhibit high serum levels of calcium, parathyroid hormone, and ALP, but low serum levels of phosphate [5, 11]. Imaging used for localization of hypercellular parathyroid glands in

benign parathyroid disease is helpful for visualization when surgical resection is indicated; they include ultrasonography, sestamibiscintigraphic scan, computed tomography, and magnetic resonance imaging. Technetium Tc 99m sestamibi is a radionuclide with a high affinity for the mitochondria of parathyroid tissue and is the localization method most commonly used for primary hyperparathyroidism [2]. Effective treatment options for primary hyperparathyroidism include varying regimens of vitamin D, bisphosphonates, estrogen hormone replacement therapy, and surgical resection of adenoma-containing glands [16, 17, 18, 19].

## CONCLUSION

This was an extraordinary case due its extreme nature and the extent to which it had progressed, as inordinate injuries were suffered relative to the trauma. Using radiography, cystic changes in bone consistent with osteolytic lesions along with sites of fracture were discovered. Laboratory examinations revealed elevations of the patient's serum calcium, PTH and ALP, as well as the low levels of phosphate. Using CT, a mass was detected that was later surgically enucleated, sent for histopathologic examinations, and revealed to be a parathyroid adenoma. Using these methods, the diagnosis was confirmed of primary hyperparathyroidism due to a PTH-secreting adenoma, that also developed osteitis fibrosa cystica.

## REFERENCES

- Lewis JL, Daly PA, Landsberg L. The Merck Manual of Medicine. 19th rev. ed. Whitehouse Station (NJ): Merck & Co., Inc. 2011; 837-54: 909-14.
- Fang SH, Lal G. Parathyroid Cancer. *Endocrine Practice*. 2011; 17(1S): 36-43.
- Ceroni D, Martin X, Delhumeau C, Rizzoli R, Kaelin A, Farpour-Lambert N. Effects of Cast-Mediated Immobilization on Bone Mineral Mass at Various Sites in Adolescents with Lower-Extremity Fracture. *J Bone Joint Surg Am*. 2012; 94(3): 208-16.
- Looker AC, Orwoll ES, Johnston CC Jr, Lindsay RL, Wahner HW, Dunn WL, et al. Prevalence of low femoral bone density in older U.S. adults from NHANES III. *J Bone Miner Res*. 1997; 12(11): 1769-71.
- Lee J, Vasikaran S. Current recommendations for laboratory testing and use of bone turnover markers in management of osteoporosis. *Ann Lab Med*. 2012; 32(2): 105-12.
- Thomas T, Burguera B, Melton III LJ, Atkinson EJ, O'Fallon WM, Riggs BL, Khosla S. Role of serum leptin, insulin, and estrogen levels as potential mediators of the relationship between fat mass and bone mineral density in men versus women. *Bone*. 2001; 29(2): 114-20.
- Hadidy EH, Ghonaim M, Gawad SS, Atta MA. Impact of severity, duration, and etiology of hyperthyroidism on bone turnover markers and bone mineral density in men. *BMC Endocrine Disorders*. 2011; 11: 15.
- Roodman GD. Review Article: Mechanisms of Bone Metastasis. *N Engl J Med*. 2004; 350: 1655-64.
- Meydan N, Barutca S, Guney E, Boylu S, Savk O, Culhaci N, Ayhan M. Brown tumors mimicking bone metastases. *J Natl Med Assoc*. 2006; 98(6): 950-3.
- Pathological fractures due to bone metastases. *Br Med J*. 1981; 283(6294): 748.
- Bringhurst FR, Demay MB, Kronenberg HM, Wysolmerski JJ, Insogna KL. In: Kronenberg HM, Schlomo M, Polansky KS, Larsen PR, (Eds.). *Williams Textbook of Endocrinology*. 11th ed. St. Louis, Mo: WB Saunders; 2008: chap. 27, 266.
- Chandrasekar CR, Grimer RJ, Carter SR, Tillman RM, Abudu AT, Jeys LM. Outcome of pathologic fractures of proximal femur in nonosteogenic primary bone sarcoma. *Eur J Surg Oncol*. 2011; 37(6): 532-6.
- Chapter 4: Endocrine, nutritional, and metabolic diseases. World Health Organization. WHO. 2006 Dec. <http://apps.who.int/classifications/icd10/browse/2010/en>. Accessed Feb 3, 2012
- Chavassieux P, Seeman E, Delmas PD. Insights into Material and Structural Basis of Bone Fragility from Diseases Associated with Fractures: How Determinants of the Biomechanical Properties of Bone Are Compromised by Disease. *Endo Reviews*. 2007; 28(2): 151-64.
- Rubin MR, LiVolsi VA, Bandeira F, Caldas G, Bilezikian JP. Tc99m-Sestamibi Uptake in osteitis fibrosa cystica Simulating Metastatic Bone Disease. *J Clin Endocrinol Metab*. 2001; 86(11): 5138-41.
- Arabi A, Khoury N, Zahed L, Birbari A, Fuleihan GE. Regression of Skeletal manifestations of hyperparathyroidism with oral vitamin D. *J Clin Endocrinol Metab*. 2006; 50(4): 657-63.
- Silverberg SJ, Shane E, Jacobs TP, Siris E, Bilezikian JP. A 10-Year prospective study of primary hyperparathyroidism with or without parathyroid surgery. *N Engl J Med*. 1999; 341: 1249-55.
- Khan AA, Bilezikian JP, Kung AW, Ahmed M, Dubois SJ, Ho AY, et al. Alendronate in primary hyperparathyroidism: a double-blind, randomized, placebo-controlled trial. *J Clin Endocrinol Metab*. 2004; 89(7): 3319-25.
- Selby PL, Peacock M. Ethinyl estradiol and norethindrone in the treatment of primary hyperparathyroidism in postmenopausal women. *N Engl J Med*. 1986; 314: 1481-5.

