

DOI 10.2478/pjvs-2014-0070

Original article

Sonoelastography in differentiation of benign and malignant testicular lesion in dogs

K. Glińska-Suchocka¹, M. Jankowski¹, K. Kubiak¹, J. Spuzak¹, S. Dzimira²

¹ Department of Internal Diseases with Clinic of Horses, Dogs and Cats, Faculty of Veterinary Medicine, Wrocław University of Environmental and Life Sciences, pl. Grunwaldzki 47, 50-366 Wrocław, Poland

² Department of Pathology, Faculty of Veterinary Medicine, Wrocław University of Environmental and Life Sciences, C.K. Norwida 31, 50-375 Wrocław, Poland

Abstract

Present study aimed to evaluate the elasticity of tumorous testicular lesions and usefulness of the elastographic examination for diagnosing lesions in the testes. The study was carried out on nine dogs in which tumorous testicular lesions had been found in the ultrasonographic examination. In all the animals examined, the elastographic examination of the lesions was performed and then castration and the histopathological examination of specimens in order to determine the type of the changes. On the basis of the results of the histopathological examination the dogs were divided into two groups: group I – consisted of three dogs in which nonneoplastic testicular lesions were found and group II comprised six dogs in which neoplastic lesions that began in testicular interstitial cells (Leydigoma) were detected. The lesions observed in dogs of group I showed low stiffness (average 11.25 kPa, range 6.1 to 16.4 kPa), whereas the lesions found in dogs of group II were characterized by high stiffness (average 91.85 kPa, range 52.3 to 131.4 kPa). On the basis of a scale proposed by Goodie et al. (2012), the lesions in group I were in the range of SC1, and in turn, the lesions in group II were in the range of SC 3 inverted. Based on the results obtained, it can be stated that the sonoelastographic examination is useful method for the screening diagnostics of testicular lesions.

Key words: sonoelastography, dog, testicles

Introduction

Since the 40s of the 20th century, a dynamic development in the ultrasonographic examination has taken place. The examination started to find more and more widespread application in medicine and, in a lot of cases, it has become a “golden standard” in diagnosing diseases of organs and tissues. Over the years, the ultrasonographic examination technique

has been subject to rapid evolution. New techniques such as a real-time examination, Color and Power Doppler, 3D and 4D imaging, a harmonic examination, and a contrast ultrasonography examination (CEUS) have been introduced. The introduction of new techniques has significantly influenced the examination quality and accuracy in differentiation of diseases of particular organs. In 1987, Krouskop et al. described for the first time elastography – a new ultra-

Correspondence to: K. Glińska-Suchocka, e-mail: kamilaglinska@o2.pl

sonographic technique (Ophir et al. 2000). From this moment on, the technique has been subject to a rapid development and the examination results obtained have become repetitive and credible.

The sonoelastographic examination (SE) has found more and more widespread applications in human medicine in recent years. At the beginning, it was used for differentiation of benign and malignant lesions in female breasts (Itoh et al. 2006, Athanasiou et al. 2010, Dobruch-Sobczak et al. 2010). Currently, it finds application in a lot of areas of medicine, including diagnostics of diseases of thyroid, lymph nodes, liver, prostate, testicles, muscles, and in oncology (Ophir et al. 1991, Shiina et al. 2002, Bercoff et al. 2004, Pallwein 2006, Itoh et al. 2006, Shah 2009, Grasso 2010). In the elastographic examination, a color scale which describes hardness of particular areas of a lesion is put on a black and white image obtained during the ultrasonographic examination. Each degree of hardness is coded with the use of a different color. In human medicine, the results obtained are interpreted on the basis of Tsukub scale, which enables classification of a given lesion into the group suspected to be of malignant character (Ophir et al. 1991).

The present study aims at the evaluation of elasticity of tumorous testicular lesions and evaluation of usefulness of the elastographic examination for diagnosing lesions in this organ.

Materials and Methods

The study was carried out on nine male dogs of different breeds (four Alsatian dogs, three boxer dogs, two mongrels) at the age of 7 to 14 in which tumorous testicular lesions were found in the ultrasonographic examination. In all the animals the elastographic examination of testicular lesions was performed and, then, castration and the histopathological examination in order to evaluate a type of lesions.

The ultrasonographic examination together with elastography were carried out with the use of Aixplorer ultrasound system apparatus (SuperSonicImagine, Aix en Provence, France). The probe used for the greyscale and shear wave elastography had a frequency range of 7.5 to 15 MHz, which at -6 dB gave axial resolution of 0.3 to 0.5 mm and lateral resolution of 0.3 to 0.6 mm. The results were displayed on a color scale according to elasticity expressed in kPa. The examination was performed in patients placed in the supine position. During the examination, no pressure was exerted by means of a head on an area examined. Three measurements of tissue elasticity were carried out in each patient. The

results obtained were evaluated on the basis of color-coded elastographic score (SC 1 to 5) suggested by Itoh et al. (2006) for breast disease and modified by Goddi et al. (2012) for testicular lesion assessment. In this scale:

SC 1 – covers those lesions (an area) which are subject to complete deformation during the B-mode examination and are displayed on elastogram as the color identical with the color of the surrounding gland tissues in the course of elastography.

SC 2 – covers those lesions (an area) most of which are subject to deformation. They are displayed as a color mosaic on elastogram.

SC 3 – covers hypoechoogenic lesions (an area) which are subject to deformation in their circumferential parts but not in their central part.

SC 3 inverted – covers those lesions (an area) which are subject to deformation in their central part but not in their circumferential parts.

SC 4 – indicates those lesions (an area) which, as a whole, are not subject to deformation. This is a pattern that indicates a malignant lesion.

SC 5 – is determined when a whole lesion detected in the B-mode examination as well as the surrounding tissues are not subject to deformation.

After castration, the material collected was fixed in 10% buffered formalin solution. Following the fixation, specimens were immersed in paraffin and cut into scrapes with a thickness of less than 4-6 μm . Then, staining with hematoxylin and eosin (H-E) was carried out.

Results

On the basis of the results of the histopathological examination, the dogs were divided into two groups: group I covered three dogs in which nonneoplastic testicular lesions were found (hematoma – 1 case, inflammatory changes – 2 cases), whereas group II covered six dogs in which neoplastic lesions that began in testicular interstitial cells (Leydigoma) were detected. In group II all the changes characterized low mitotic index. All the changes was benign.

On the basis of the elastographic examination, the lesions in the testicles of dogs qualified for group I were in the range of SC1 of a scale created for the evaluation of testicles suggested by Goodi et al. 2012; (Fig. 1). In turn, the lesions in the testicles of dogs qualified for group II were in the range of SC 3 inverted of the above-mentioned scale (Fig. 2).

In the study conducted, the lesions in dogs of group I showed low stiffness (average 11.25 kPa, range 6.1 to 16.4 kPa), whereas the lesions in dogs of group II were characterized by high stiffness (average 91.85 kPa, range 52.3 to 131.4 kPa).

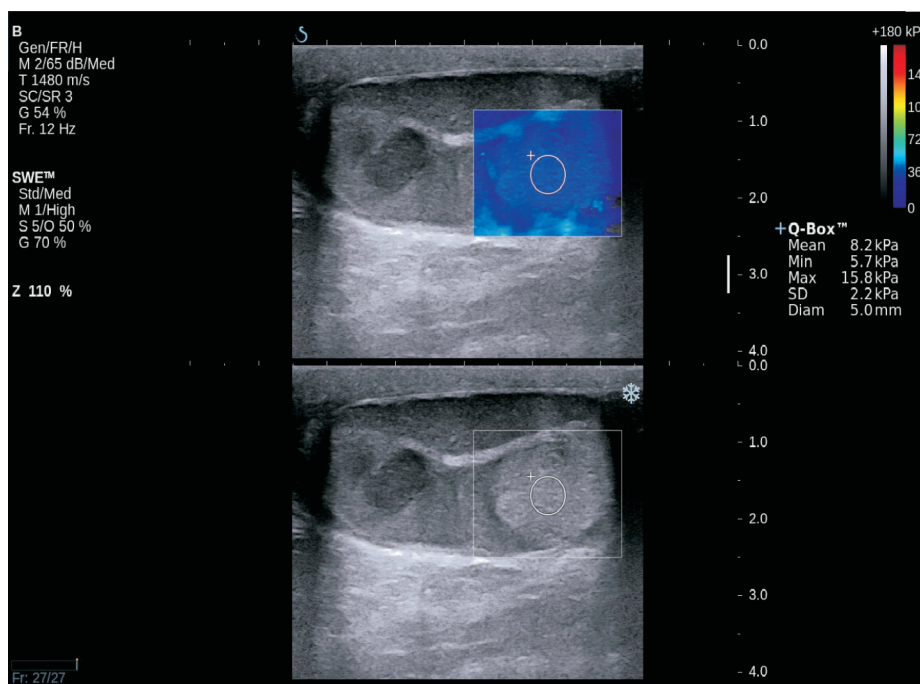


Fig 1. Multiple hypochoic and hyperechogenic testicular nodules at ultrasound, with homogeneous elasticity at sonoelastography.

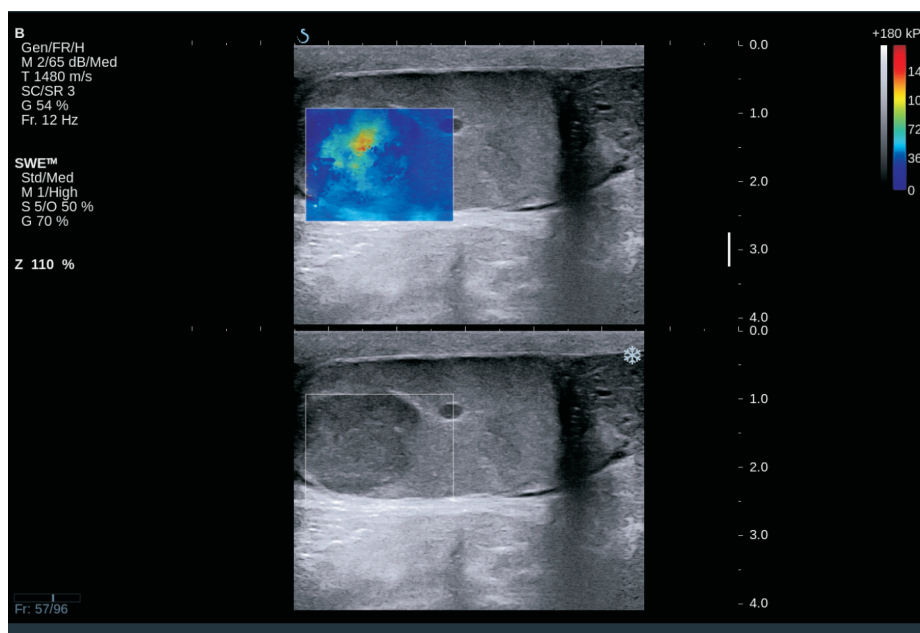


Fig 2. Hypochoic testicular nodules at ultrasound. At sonoelastography classified as SC 3 inverted.

Discussion

Testicular neoplasms are relatively frequent neoplasms which occur in males of this species. They are observed mainly in older male dogs at the average age of about 10 years. Frequency of their occurrence is estimated, according to different sources, at 6 to 27% and a lot of them are only detected during the post-mortem examination (Cooley and Waters 2001).

Three most frequently occurring types of neoplasms: sertolioma, seminoma, and leydigoma, which may occur on one side or both sides, show a different origin, respectively from Sertoli cells, from reproductive epithelium cells, and from Leydig interstitial cells (MacLachlan and Kennedy 2002, Sapierzyński 2006). Their etiology, like in almost each type of spontaneous neoplasm, is not definitely determined, yet, position of testicles outside the scrotum has a considerable

impact on the development of cancer. In the studied group, none of the dogs was a cryprochid, however, there were breeds which were predisposed to testicular neoplasms i.e. Alsatian and boxer dogs.

According to WHO, testicular neoplasms are classified as: stromal cell neoplasms i.e. sertolioma and leydigoma, and reproductive cell neoplasms i.e. seminoma, teratoma, and embryonal carcinoma. Other possible testicular neoplasms are metastatic neoplasms, seminal vesicle neoplasms, and epididymal neoplasm.

In the present study, nonneoplastic lesions in the testicles were found in group I, whereas neoplastic lesions that began in Leydig cells were diagnosed in group II.

Leydigoma are neoplasms which are smaller than other neoplasms (sertolioma, seminoma) with a diameter of approx. 2-3 cm, surrounded by a thin connective tissue capsule of soft consistency and a dark yellow to orange color at cross-section. More or less numerous tiny cysts filled in with serous or serosanguineous fluid can often be observed at the cross-section. Histologically, three types of tumour structure may be distinguished: a solid and infiltrating tumour, a cystic and vascular tumour (called an angiomatoid tumour), and a pseudoglandular tumour (Ciaputa et al. 2012).

The classic ultrasonographic examination is a very sensitive method for detecting neoplastic testicular lesions, however, in many cases, it is impossible to assess the type of lesion on the basis of the examination. Sonoelastography is a new technique that enables determination of a degree of tissue hardness. The technique is based on a principle according to which soft tissues become deformed more easily compared to hard tissues, which enables semiquantitative determination of tissue elasticity (Iton et al. 1991). In the elastographic examination, an image of the tissue elasticity measurement is put on the B-mode image, which enables performance of tissue elasticity measurement in the real time. Tissue stiffness is displayed in the form of colorful maps from the red color (which describes the most rigid tissues in our study) to the blue color (which describes the soft tissues in our study) (Glińska-Suchocka et al. 2013).

In the present study, neoplastic lesions which began in the seminiferous epithelium cells were within SC1, in turn, lesions that derived from Leydig cells were classified as SC 3 inverted. An image received in the elastographic examination was determined by the histological structure of a tumour. Similar results were obtained in the human medicine in the study carried out by Aigner et al. (2012). They found that the elastographic examination used in the testicular neoplasm diagnostics is characterized by 100% sensitivity, 81% specificity, and 91% accuracy. On the basis of the stu-

dies carried out by Goddi et al. (2012) in 1617 patients in which testicular tumours occurred, SC 1 lesions were classified as benign and lesions SC 2 (soft lesions showing single rigid areas compared to regular tissue) – as suspected of neoplasia and to be monitored. However, they did not find any lesions classified as SC 3. The authors have explained this by two main factors: 1) SC classification was created on the basis of the Itoh classification used for the evaluation of breast lesions, 2) tumorous lesions in the mammary gland have a different histological structure compared to tumorous lesions in testicles (Goddi et al. 2012).

Based on numerous elastographic examinations and the histological structure, Goddi et al. (2012) introduced a SC 3 range to the scale, which is typical of Leydig tumours. In our study, Leydig tumours were just in this range of SC scale.

The present study has revealed that elastography is a safe and very useful diagnostic technique which serves in detection of neoplastic lesions in testes. In spite of the fact that elastography in the veterinary medicine is rarely applied in for neoplastic disease diagnostics, it raises hope that, in the future, it will be included in the standards of non-invasive oncological diagnostics of testicle diseases as a screening examination. However, carrying out a greater number of studies is required in order to determine lesions in elasticity in particular testicular neoplasms and to precisely assess a degree of their stiffness. The present preliminary research has revealed the effectiveness of the elastographic examination in differential diagnostics of Leydig tumours, however, in order to fully assess a usefulness of this diagnostic method, it is necessary to evaluate it for other types of neoplasms.

References

- Aigner F, De Zordo T, Pallwein-Prettner L, Junker D, Schäfer G, Pichler R, Leonhartsberger N, Pinggera G, Dogra VS, Frauscher F (2012) Real-time sonoelastography for the evaluation of testicular lesions. *Radiology* 263: 584-589.
- Athanasiou A, Tardivon A, Tanter M, Sigal-Zafrani B, Bercoff J, Deffieux T, Gennisson JL, Fink M, Neuenchwander S (2010) Breast lesions: quantitative elastography with supersonic shear imaging – preliminary results. *Radiology* 256: 297-303.
- Bercoff J, Tanter M, Fink M (2004) Supersonic shear imaging: a new technique for soft tissue elasticity mapping. *IEEE Trans Ultrason Ferroelectr Freq Control* 51: 396-409.
- Ciaputa R, Nowak M, Kielbowicz M, Antończyk A, Błasiak K, Madej JA (2012) Seminoma, sertolioma, and leydigoma in dogs: Clinical and morphological correlations. *Bull Vet Inst Pulawy* 56: 361-367.
- Cooley DM, Waters DJ (2001) Tumors of the male reproductive system. In: Withrow SJ, MacEwen EG (eds),

- Small animal clinical oncology. 3rd ed., Philadelphia, PA WB Saunders Company, pp 478-489.
- Dobrućh-Sobczak K, Sudol-Szopińska I (2010) Real time elastography – the role in differential diagnosis of focal breast lesions. *Acta Bio-Optica et Informatica Medica* 16: 352-354.
- Głinska-Suchocka K, Jankowski M, Kubiak K, Spuzak, J, Dzimira S, Nicpon, J (2013) Application of shear wave elastography in the diagnosis of mammary gland neoplasm in dogs. *Pol J Vet Sci* 16: 477-482.
- Goddi A, Sacchi A, Magistretti G, Almolla J, Salvatore M (2012) Real-time tissue elastography for testicular lesion assessment. *Eur Radiol* 22: 721-730.
- Grasso M, Blanco S, Raber M, Nespoli L (2010) Elastography of the testis: preliminary experience. *Arch Ital Urol Androl* 82: 160-163.
- Itoh A, Ueno E, Tohno E, Kamma H, Takahashi H, Shiina T, Yamakawa M, Matsumura T (2006) Breast disease: clinical application of US elastography for diagnosis. *Radiology* 239: 341-350.
- MacLachlan NJ, Kennedy PC (2002) Tumors of the genital-systems. In: Meuten DJ (ed) *Tumors in domestic animals*, 4th ed., Iowa State University Press, Ames, pp 547-573.
- Ophir J, Céspedes I, Ponnekanti H, Yazdi Y, Li X (1991) Elastography: a quantitative method for imaging the elasticity of biological tissues. *Ultrason Imaging* 13: 111-134.
- Pallwein L, Pallwein E, Schurich M, Fischbach V, Steiner H, Frauscher F (2006) Sonoelastography of the testicles: preliminary results in the diagnosis of different pathological processes, 5th International Conference on the Ultrasonic Measurement and Imaging of Tissue Elasticity, Snowbird.
- Sapierzyński R (2006) Neoplasms of the urinary and genital system in dogs and cats. Part II. Tumors of testes, prostate, penis and prepuce. *Życie Wet* 81: 805-811.
- Shah A, Rajayogeswaran B, Sellars ME, Sidhu PS (2009) Imaging the testis using real-time tissue elastography – seeing what you feel? A pictorial review. *Proceedings of the 21st Euroson Congress, Edinburgh.*
- Shiina T, Nitta N, Ueno E, Bamber JC (2002) Real time tissue elasticity imaging using the combined autocorrelation method. *J Med Ultrasonics* 29: 119-128.