

DOI 10.2478/pjvs-2014-0104

*Short communication*

# Electroencephalography recording analysis in monitoring of canine idiopathic epilepsy treated with phenobarbital. Pilot study

A. Bocheńska<sup>1</sup>, M. Kwiatkowska<sup>1</sup>, A. Pomianowski<sup>1</sup>, T. Monowid<sup>1</sup>,  
Z. Adamiak<sup>2</sup>

<sup>1</sup> Department of Internal Medicine

<sup>2</sup> Department of Surgery and Radiology, Faculty of Veterinary Medicine  
University of Warmia and Mazury in Olsztyn, Oczapowskiego 14, 10-957 Olsztyn, Poland

## Abstract

EEG recording is used in veterinary medicine as a diagnostic tool to support clinical diagnosis of idiopathic epilepsy and to identify focal seizure activity. This retrospective study was designed to compare EEG procedures in 23 dogs with idiopathic epilepsy before and after phenobarbital treatment. Differences among standard deviations for particular bands were significant. During phenobarbital treatment the delta band decreased.

**Key words:** EEG, electroencephalography, idiopathic epilepsy, phenobarbital

## Introduction

Idiopathic epilepsy is the most common cause of recurrent seizures in dogs. Idiopathic epilepsy may be diagnosed based on clinical history, seizure incidents and exclusion of inflammatory diseases and central nervous system tumors (Jaggy and Bernardini 1998). Typically, affected dogs exhibit generalized tonic-clonic seizures but we also see other forms such as tonic, clonic, myoclonic and atypical absence seizures, atonic (Jaggy and Bernardini 1998, Licht et al. 2002). Most patients have generalized type seizure activities but some patients have focal seizure signs with tremor and salivation without loss of consciousness (Berendt et al. 1993, Jaggy and Bernardini 1998, Durmuller et al. 2007).

Research has shown showed that about 65% of dogs with idiopathic epilepsy have abnormal activity interictal in EEG (Itamoto et al. 2002). The aim of our study was to define EEG differences between untreated epileptic dogs and patients on phenobarbital monotherapy.

## Materials and Methods

The 23 dogs with idiopathic epilepsy were referred to the Department of Internal Medicine UWM in 2011. The diagnosis of idiopathic epilepsy was based on a detailed interview with the owner and clinical and neurological examination. Every patient was checked with abdominal ultrasound and chest X-ray,

---

Correspondence to: A. Bocheńska, e-mail: aneta.bochenska@uwm.edu.pl

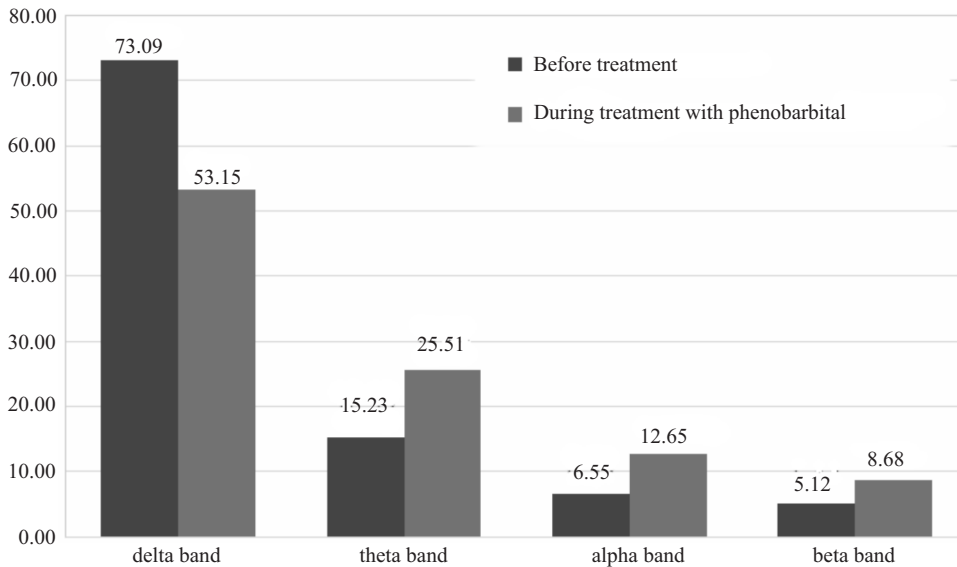


Fig. 1. Percentage distribution of particular band activities.

blood analysis (CBS panel and biochemistry) urine analysis and cerebrospinal fluid was collected. The CSF was taken from the atlanto-occipital cistern. MRI imaging was performed in 8 dogs. Pre-medication was performed with medetomidine at a dose of 40 – 60  $\mu\text{g}/\text{kg}$  of body weight. Anesthesia was induced with an intravenous bolus dose of propofol with 1 mg/kg b.w. and anesthesia was maintained with 2 mg of propofol/ kg/h. Propofol was used in low doses because paradoxically it enhances the epileptiform phenomena. The patients were positioned in sternal recumbency. The EEG was performed on a 19 channel electrode setting (Frontal, Central, Parietal, Temporal, Occipital – F7, F3, F4, F8, T3,T5, C3, Cz, C4, T4,T6, P3, Pz, P4, O1, O2) based on the international 10-20 system for humans. Disposable intra-dermal needle electrodes were inserted. The recording was made with the nasal references electrode. The filter range was set at 0.3 Hz-70 Hz, sensitivity 10  $\mu\text{V}/\text{mm}$ . Paper speed was 30 mm/s. The impedance did not exceed 5 kOm. Monopolar and bipolar EEG recordings were performed. EEG was performed for 20 minutes on each patient. For our study we chose and analyzed 2 minute artefact free periods. The analysis included Fast Fourier Transform (FFT) and Student's *t*-distribution test. For this study the spectral bands of delta, theta, alpha and beta were considered as relative power. This means the relative power percentage of power in any band compared with the total power in the patient's EEG. EEG recording was performed in this anesthetic protocol twice: initially before phenobarbital treatment and then after a minimum of 4 weeks anticonvulsant therapy. For therapy phenobarbital was used with doses of 3 mg/kg of body weight twice per day.

## Results and Discussion

Twenty-three dogs were diagnosed with idiopathic epilepsy without previous treatment. The mean time onset of seizures was at 18 months of age and the range time from onset to EEG recording was 3 months. Average frequency of seizures was 3 incidents per month, 8 dogs presented a generalized seizure type, and 6 dogs presented focal seizures. All patients had results within the normal range and normal neurological examination. Analysis of CSF did not present any abnormalities; MRI imaging also presented no abnormalities.

Changes in EEG recording were observed in 14 dogs (60.86%) and this group qualified for next the stage of research. The second EEG examination was carried out when phenobarbital serum therapeutic concentration was achieved (therapeutic concentration from 10 to 40  $\mu\text{g}/\text{ml}$ ). The average phenobarbital serum concentration was about 20.2  $\mu\text{g}/\text{ml}$  (Durmuller et al. 2007). Each EEG was visually analyzed and calculated before and during the phenobarbital treatment. During the visual analysis epileptiform findings such as: sharp waves, slow waves and focal spikes were noticed. The patients also showed findings unrelated to epilepsy: sleep spindles and K-complexes (Jeserevics et al. 2007). In 10 dogs (71%) high amplitude (20-90  $\mu\text{V}$  and low frequency 1-2.5Hz EEG background activity were presented and 4 dogs (29%) presented low amplitude (4-15  $\mu\text{V}$ ) and high frequency EEG background activity. Similar outcomes are reported in the literature (Itamoto et al. 2002). Statistical analysis showed significant changes in percentage distribution in particular bands. In our study we noticed that the main differences were in delta

background activities. Changes in theta, alpha and beta activity were also statistically significant. During phenobarbital treatment the delta band decreased from 73.08% to 53.15% ( $P \leq 0.1$ ). We noticed increased theta activity of about 10% to 28% ( $P \leq 0.5$ ). The alpha and beta activity also increased compared to EEG before phenobarbital treatment, but the results were not statistically significant. Jeserevics et al. (2007) in their study conducted on Finnish Spitz with epilepsy noticed that phenobarbital treatment increased alpha, beta and theta bands and decreased the delta band compared to untreated dogs. In 12 dogs (85.71%) fewer seizure episodes were observed. In just 2 dogs with partial seizures, despite changes in EEG pattern, the clinical status did not improve.

### Conclusion

EEG recording seems to be a useful tool for monitoring the subclinical effect of treatment.

### References

- Berendt M, Hogenhaven H, Flagstad A, Dam M (1999) Electroencephalography in dogs with epilepsy: similarities between human and canine findings. *Acta Neurol Scand* 99: 276-283.
- Durmuller N, Guillaume P, Lacroix P, Porsolt RD, Moser P (2007) The use of the dog electroencephalogram (EEG) in safety pharmacology to evaluate proconvulsant risk. *J Pharmacol Toxicol Methods* 56: 234-238.
- Itamoto K, Taura Y, Wada N, Takuma T, Une S, Nakaichi M, Hikasa Y (2002) Quantitative electroencephalography of medetomidine, medetomidine-midazolam, and medetomidine-midazolam-butorphanol in dogs. *J Vet Med A* 49: 169-172.
- Jaggy A, Bernardini M (1998) Idiopathic epilepsy in 125 dogs: a long – term study. Clinical and electroencephalographic findings. *J Small Anim Pract* 39: 23-29.
- Jeserevics J, Viitmaa R, Cizinauskas S, Sainio K, Jokinen TS, Snellman M, Bellino C, Bergamasco L (2007) Electroencephalography findings in healthy and Finnish Spitz dogs with epilepsy: visual and background quantitative analysis. *J Vet Intern Med* 21: 1299-1306.
- Licht BG, Licht MH, Harper KM, Lin S, Curtin JJ, Hyson LL, Willard K (2002) Clinical presentations of naturally occurring canine seizures: similarities to human seizures. *Epilepsy Behav* 3: 460-470.