

## Case reports

# Disseminated skin rash and blood eosinophilia in a Polish traveler diagnosed *Strongyloides stercoralis*, *Trichuris trichiura*, *Schistosoma* sp. and *Blastocystis* sp. coinfection

Łukasz Pielok<sup>1</sup>, Krystyna Frąckowiak<sup>2</sup>, Matylda Kłudkowska<sup>2</sup>

<sup>1</sup>Department of Tropical and Parasitic Diseases, Karol Marcinkowski University of Medical Sciences, ul. Przybyszewskiego 49, 60-355 Poznań, Poland

<sup>2</sup>Central Microbiology Laboratory, Heliodor Święcicki University Hospital, ul. Przybyszewskiego 49, 60-355 Poznań, Poland

Corresponding Author: Łukasz Pielok; e-mail: lpielok@ump.edu.pl

**ABSTRACT.** Traveling to tropical countries make very often for travelers a danger of illnesses, which do not exist or exist very rarely in temperate climate. Imported parasitic disease cases are inevitable and have been reported increasingly as a result of enhanced globalization. The most common infections in endemic areas are caused by soil transmitted helminths. Symptoms of many invasions occurred even several weeks after returning from endemic areas (schistosomiasis, strongyloidosis, leishmaniasis). In this work we described a case of a young Polish traveler, who came back to Poland, from two months touristic journey in Democratic Republic of the Congo, Africa, who was diagnosed *Schistosoma* sp., *Trichuris trichiura*, *Strongyloides stercoralis* and *Blastocystis* sp. coinfection. Parasitic infections should be taken under consideration in differential diagnosis in patients suffering from disseminated skin changes and eosinophilia syndrome specially in individuals returning from endemic areas.

**Key words:** coinfection, skin rash, eosinophilia, *Strongyloides*, traveler

## Introduction

Traveling to tropical and subtropical regions can become a threat for travelers, because of exposure to illnesses and pathogens which do not exist or exist very rare in temperate climate [1]. Importation of parasitic disease is sometimes inevitable and the cases are reported increasingly because of enhanced globalization [2]. The infections in endemic areas are most often caused by soil-transmitted helminths [3].

The first clinical symptoms of many parasitic infections occur even several weeks after returning from endemic areas. The group of neglected tropical diseases (e.g. schistosomiasis, strongyloidosis, leishmaniasis) is largely underdiagnosed because it is considered of lower public health relevance. However, these parasitic infections have been demonstrated to cause significant morbidity and even mortality globally, particularly among people

living in poor settings [4]. Long incubation period of imported illnesses and delay in appropriate diagnosis often correlates with later beginning of suitable, specific antiparasitic treatment and have relationship with life-threatening multiorgan complications [2–4].

Symptoms of parasitic infections are nonspecific and heterogeneous. Some of them are connected to mutual correlations between the host and the parasite resulting from activation of immunological mechanisms [5]. Their adequate diagnosis requires performing many laboratory tests and specialized microscopic examinations. Results of primary tests, performed often during patient's admission in emergency department, together with careful epidemiological history, give important information, suggesting a type of parasitic infection and show necessity to widen diagnostics [5]. Diagnosis of parasitic infections can be confirmed by identification of parasites' life stages, e.g. eggs,

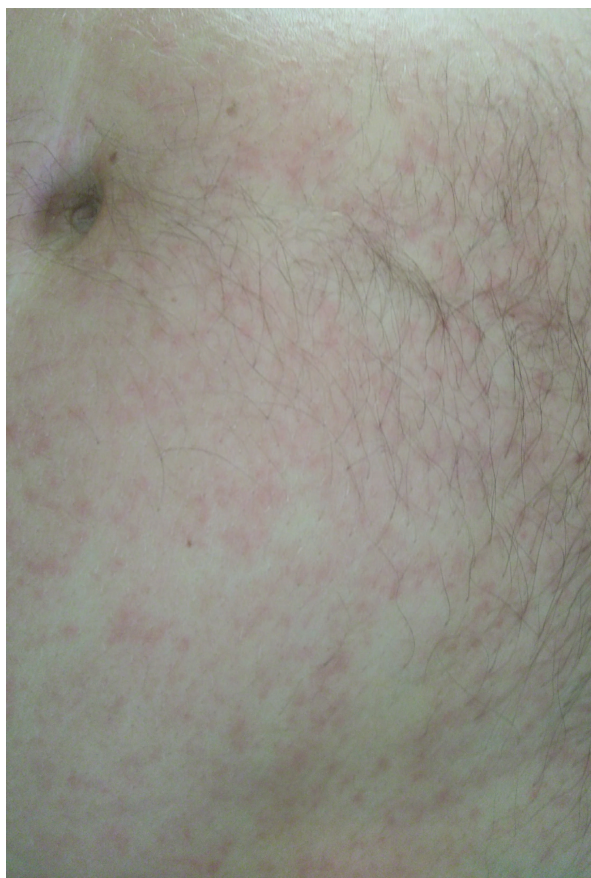

Fig. 1. Disseminated spotted skin rash

larvae, cysts. This gold standard can only be achieved only by repeated examinations [6].

In this work we described a case of a young Polish traveler after returning to Poland from the trip to Democratic Republic of the Congo, Africa, infected with *Schistosoma* sp., *Trichuris trichiura*, *Strongyloides stercoralis* and *Blastocystis* sp.

### Case presentation

44-year-old man was admitted to the Department of Tropical and Parasitic Diseases, Poznań, Poland, because of the fever and skin rash (Fig. 1), which appeared after returning from a journey to the Democratic Republic of the Congo (Africa) where he spent two months (January–March, 2018). During the trip he reported one day diarrheal episode. The living conditions during the trip were usually poor. He slept in a tent. In Congo he traveled by motorbike from Kisangani to Isange Village

(Salonga National Park), where he spent three days in the jungle, walking and swimming in a small boat along Lokoro and Momboyo rivers. He was swimming in the river. He used filtered water but sometimes he drunk water directly from Lokoro river. He ate fishes, manioc and vegetables prepared by local citizens. After returning to Poland high fever and disseminated skin spotted-rash appeared. In emergency Infectious Diseases Department, HIV infection (4th generation HIV-test) and measles were excluded. He was admitted to the Department of Tropical and Parasitic Diseases with a suspicion of acute parasitic illness because in the peripheral

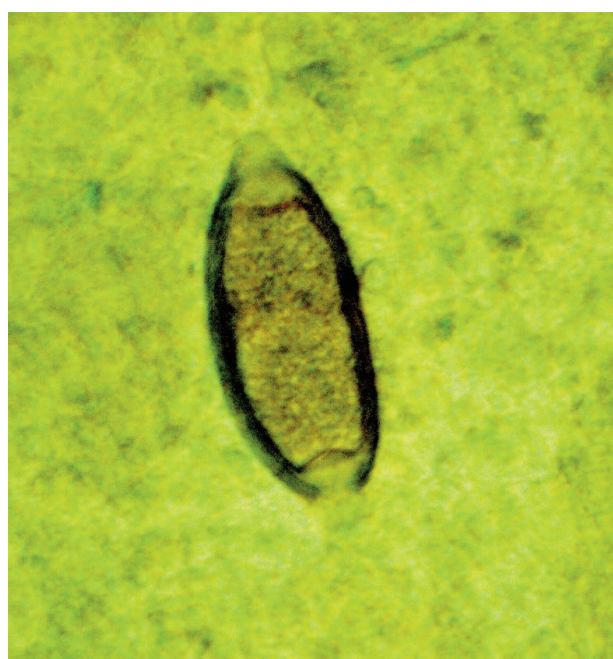

Fig. 2. *Trichuris trichiura*; egg

blood smears based on the Schilling formula hyper eosinophilia was diagnosed (17%). During hospitalization (19.03.-30.03.2018) repeated hyper eosinophilia was detected (Table 1).

Taking under consideration the epidemiological data, ELISA-*Schistosoma mansoni* IgG (NovaTec) test was performed. Obtained positive result (14 NTU) was confirmed by the Western blot procedure (LDBIO Diagnostics, Lyon, France). *Toxocara* spp. infection was excluded.

The parasitic stool examination was performed based on a direct thin smear in 0.9% NaCl and a

Table 1. Values of eosinophils

Day	20.03	22.03	23.03	26.03	27.03	18.04	23.04
Eosinophilia	1600	2400	4300	14300	7500	8600	3900

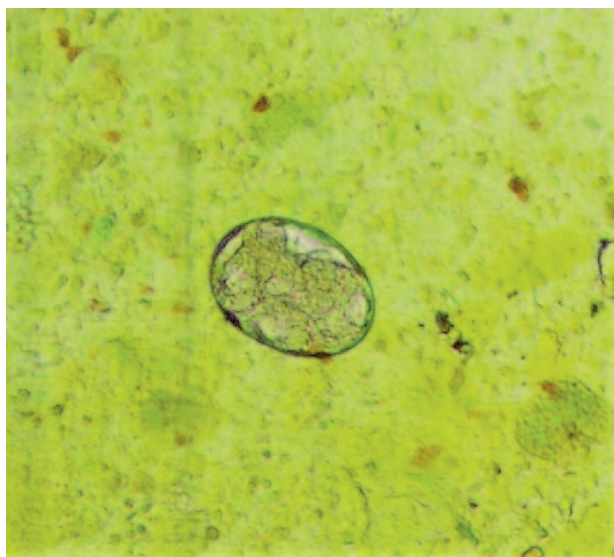


Fig. 3. *Strongyloides stercoralis*; egg

thick smear by Kato-Miura method. The presence of *Trichuris trichiura* eggs (Fig. 2), *Strongyloides stercoralis* eggs (Fig. 3) and rhabditiform larvae (Harada-Mori stool culture, Fig. 4) and *Blastocystis* sp. vacuolar forms and cysts was confirmed.

The *Schistosoma* eggs were not found in the urine and stool multiple examinations. The *Schistosoma* sp. infection was established according to epidemiological data, high eosinophilia and serological results (ELISA/Western blot). Therefore, the co-infection with *Schistosoma* sp., *Strongyloides stercoralis*, *Trichuris trichiura* and *Blastocystis* sp. was diagnosed.

The patient was treated with praziquantel (2400 mg in one daily dose) and albendazole (2×400 mg per day for 2 weeks). The follow-up examination (18.04–23.04.2018) showed decreased eosinophils level and elimination of parasites.

## Discussion

An estimated 3,5 billion people worldwide are infected with soil transmitted helminths, especially in tropical and subtropical regions. The infected persons are most often asymptomatic and eosinophilia can be the only laboratory finding. Sometimes parasites can cause different cutaneous, gastrointestinal or pulmonary symptoms [7].

Skin rash is one of the symptoms suggesting parasitic infections. Allergic manifestations in the clinical course of strongyloidosis and schistosomiasis have been described [8]. It is connected to parasites circulation within the host organism as well as host immunological response [9,10]. These

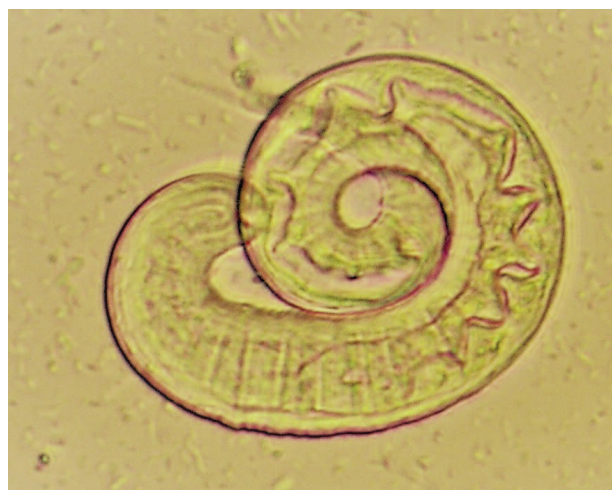

Fig. 4. *Strongyloides stercoralis*; larva (Harada-Mori stool culture)

type of infections are mainly detected in tropical and subtropical areas or in travelers and immunocompromised individuals returning from endemic areas [11–13]. Thus, the travelers and immigrants from endemic areas should be tested for parasitic diseases [14]. First detectable laboratory abnormalities is blood hyper eosinophilia which appears even before clinical signs and predict possibility of parasitic infection [15–18].

The cause of eosinophilia varies depending on the patient group and visited region. Eosinophilia is often higher in travelers infected during the trip than in chronic infected persons. It is important to find the pathology connected to eosinophilia in returning travelers. Some of the helminths' infections have self-limiting course and cause mild symptoms, but occasionally they may cause long-term health problems. Strongyloidosis can result in a dangerous hyperinfection syndrome and schistosomiasis is occasionally associated with bladder carcinoma [19]. Moreover, *Strongyloides stercoralis* hyperinfection syndrome and disseminated disease may occur due to the ability of the parasite to reproduce within the host [20].

Parasitic infections should be taken under consideration in differential diagnosis in patients suffering from disseminated skin changes and eosinophilia syndrome especially in individuals returning from endemic areas.

## References

- [1] Angelo T., Buze J, Kinunghi SM. 2018. Geographical and behavioral risk associated with *Schistosoma haematobium* infection in an area of complex

- transmission *Parasites and Vectors* 11: 481.  
doi:10.1186/s13071-018-3064-5
- [2] Ishida K., Hsick MH. 2018. Understanding urogenital Schistosomiasis-related bladder cancer: An update. *Frontiers in Medicine (Lausanne)* 5: 223.  
doi:10.3389/fmed.2018.00223
- [3] Hajjar W.M., Alsheikh A.M., Alhumaid Y.U. 2018. Pulmonary schistosomiasis in a young male. A case report and review of the literature. *Annals of Thoracic Medicine* 13: 180-192.  
doi:10.4103/atm.ATM\_300\_17
- [4] Myint A., Chapman C., Almira-Suarez J., Mekta N. 2017. *Strongyloides* hyperinfection syndrome in an immunocompetent host resulting in bandemi and death. *BMJ Case Reports* 2017.  
http://dx.doi.org/10.1136/bcr-2016-217911
- [5] Pawłowski Z.S. 2004. Badania laboratoryjne w parazytologii. Parazytologia kliniczna w ujęciu dyscyplinarnym, PZWL (in Polish).
- [6] Martinez-Perez A., Roure-Dier S., Bethassen-Garua M. et al. 2018. Management of severe strongyloidiasis attended at reference centers in Spain, *PLOS Neglected Tropical Diseases* 12: e0006272.  
https://doi.org/10.1371/journal.pntd.0006272
- [7] Ardic N. 2009. An overview of *Strongyloides stercoralis* and its infections. *Mikrobiyoloji Bulteni* 43: 169-177.
- [8] Caraballo L., Coronada S. 2018. Parasite allergens. *Molecular Immunology* 100: 113-119.  
https://doi.org/10.1016/j.molimm.2018.03.014
- [9] Duguenne J., Mabalukwe J., Clavo E., Michaux C., Staub T. 2018. A disseminated strongyloidosis in a non immunocompromised patient. *Revue Medicale de Liege* 73: 383-386.
- [10] Wang X., Fu Q., Song R. 2018. Antinuclear antibodies and interleukin responses in patients with *Schistosoma japonicum* infections. *Parasite Immunology* 40: e12577. doi:10.1111/pim12577
- [11] Gonzalez A., Gallo M., Valls M.E. et al. 2010. Clinical and epidemiological features of 33 imported *Strongyloides stercoralis* infections. *Transactions of The Royal Society of Tropical Medicine and Hygiene* 104: 613-616.
- [12] Jagadeesan R., Jain R., Karnik T., Sudararajan T., Ardesonov Z., Sidorenko E. 2018. *Strongyloides* duodenitis in an immunosuppressed patient with Lupus Nephritis. *Kansas Journal of Medicine* 11: 8-10.
- [13] Overbosch F.W., van God T., Matsers A., Sonder G.J.B. 2018. Low incidence helminth infections (schistosomiasis, strongyloidiasis, filariasis, toxocarosis) among Dutch long-term travelers: A prospective study, 2008-2011. *PLOS ONE* 30: e019770.
- [14] Akiyama M.J., Brown J.D. 2018. Human strongyloidiasis in Hawaii: A retrospective review of Enzyme Linked Immunosorbent Assay Serodiagnostic Testing. *The American Journal of Tropical Medicine and Hygiene* (99/2): 370-374.  
doi:10.4269/ajtmh.18-0157
- [15] Yamanashi H., Kambara S., Murasa K., Maede T. 2018. Eosinophilia, a marker of asymptomatic *Strongyloides* infection in a young patient with extrapulmonary tuberculosis. *BMJ Case Reports* 42018 pii:2017-223208.
- [16] Segarra-Nenham H. 2007. Manifestations, diagnosis and treatment of *Strongyloides stercoralis* infection. *Annals of Pharmacotherapy* 41:1992-2001.
- [17] Suzuki Y., Nakamura T., Tokoro M., Togano T. et al. 2010. A case of giardiasis expressing severe systemic symptoms and marked hyper eosinophilia, *Parasitology International* 59: 487-489.  
https://doi.org/10.1016/j.parint.2010.06.006
- [18] Osiro S., Hamula C., Glaser A., Roma M., Dunn D., 2018. A case of *Strongyloides* hyperinfection syndrome in the setting of persistent eosinophilia but negative serology, *Diagnostic Microbiology and Infectious Diseases* 88: 168-170.  
https://doi.org/10.1016/j.diagmicrobio.2017.02.016
- [19] Magill A.J., Ryan E.T., Hill D.R., Solomon T. 2013. Hunter's tropical medicine and emerging infectious diseases. Elsevier, 9th ed.

Received 23 October 2018

Accepted 06 January 2019