

OCCURRENCE OF HARD TICKS IN DOGS FROM WARSAW AREA

Wojciech Zygnier, Halina Wędrychowicz

Division of Parasitology, Department of Preclinical Sciences, Faculty of Veterinary Medicine, Warsaw Agricultural University, Warsaw, Poland

Zygnier W, Wędrychowicz H: Occurrence of hard ticks in dogs from Warsaw area. *Ann Agric Environ Med* 2006, **13**, 355–359.

Abstract: Ticks are known as a vector of many viral, bacterial, rickettsial and protozoan infections of dogs. The threat with particular tick-transmitted disease depends very much on the tick species which feeds on the dog. In this paper we present results of research designed to identify tick species which attack dogs in the Warsaw area. Ticks were collected from dogs presented for medical examination in veterinary clinics in different parts of Warsaw. All of 590 tick specimens found on dogs belonged to the family Ixodidae (hard ticks). The majority (64.6%) of the collected ticks were identified as *Dermacentor reticulatus* – vector of *Babesia canis*. The other tick species found on examined dogs was *Ixodes ricinus*. The male to female ratio was more than 3 times higher in *D. reticulatus* than in *I. ricinus*.

Address for correspondence: Wojciech Zygnier, Zakład Parazytologii i Inwazyjologii, Katedra Nauk Przedklinicznych, Wydział Medycyny Weterynaryjnej SGGW, ul. Ciszewskiego 8, 02-786. Warszawa. E-mail: wojciechzygnier@o2.pl

Key words: ticks, dogs, *Dermacentor reticulatus*, *Ixodes ricinus*, Warsaw, Poland.

INTRODUCTION

Ticks are obligatory ectoparasites of humans and animals which are distributed worldwide. They are vectors of a broad range of viral, rickettsial, bacterial and protozoan pathogens [11]. Hard ticks are hematophagous arthropods, which need 4–10 days to feed to repletion. The blood meal is necessary for the female to lay eggs and for developmental stages (larvae and nymphs) to shed their cuticular layer [5].

The invasion of ixodid ticks implicates the risk of canine tick-borne diseases, especially canine ehrlichiosis and babesiosis. *Ehrlichia* species is transmitted by *Ixodes ricinus* and *Rhipicephalus sanguineus*. Canine ehrlichiosis can be caused by infection with *Ehrlichia canis*, *E. chaffeensis*, *E. platys*, *E. phagocytophila* and *E. ewingii*. Symptoms of canine ehrlichiosis can include lethargy, weight loss, anorexia, lymphadenomegaly and splenomegaly [2, 17, 19, 21]

E. canis is the agent causing canine monocytic ehrlichiosis. Canine granulocytic ehrlichiosis is caused by

an agent of which nucleotide sequence of the 16S rRNA gene appeared similar to both *Ehrlichia equi* and *E. phagocytophila* [30]. In Europe, canine ehrlichiosis has been reported from Italy [7, 32], UK [15], Switzerland [26], Portugal [3], Sweden [10], Germany [14], The Netherlands [33], Greece [23], Spain [1] and from Poland [25]. As far as we know there have been no studies of prevalence of *Ehrlichia* species in dogs or ticks in the Warsaw region.

Babesia canis is transmitted by *Dermacentor reticulatus* and *Rhipicephalus sanguineus*. Canine babesiosis is manifested by fever, jaundice, hemoglobinuria and anemia, and the disease can result in death [18, 21]. Canine babesiosis is caused by the protozoal agent *Babesia canis canis* (which is found in tropical and semitropical areas worldwide), *B. canis vogeli* (has worldwide distribution in tropical and semitropical areas), *B. canis rossi* (found in Southern Africa) and *B. gibsoni* (found in Africa, Asia, USA, southern Europe and the Middle East) [27]. In Europe canine babesiosis has been found in: Hungary [12, 13],

The Netherlands [33], Slovenia [9], France [22], Germany [4], Spain [8], Croatia, Italy and Poland [6, 16, 31].

Twenty tick species from the order of *Ixodida* may occur in Poland. Most of these species belong to family *Ixodidae*. The ticks from this family are known as hard ticks. On dogs in Poland there may feed 4 species native for our country: *Ixodes crenulatus*, *Ixodes hexagonus*, *Ixodes ricinus*, *Dermacentor reticulatus*, and in addition, 1 species often imported by leaving wild animals - *Rhipicephalus sanguineus*. There are 2 peaks of activity of these ectoparasites in Poland. The first is higher and occurs in spring and the second, lower, occurs in autumn. Dogs may acquire ticks in the city areas in parks and housing estates [28]. To our knowledge, the prevalence of particular species of ticks in dogs in central Poland has not yet been investigated. In the present study, we aim to identify the hard tick species infecting domestic dogs in the urban part of Warsaw.

MATERIALS AND METHODS

During two years, from March 2003-March 2005, ticks were collected in veterinary clinics from dogs which were presented for veterinary care. In total, 6 veterinary clinics submitted 590 ticks found on 316 domestic dogs. The clinics are situated both on the left and right banks of the Vistula river in Warsaw.

The ticks were examined under stereomicroscope (Nikon SMZ-10A) and identified using standard taxonomic keys [28]. Photographs were taken using a digital camera (Panasonic GP-KR222), and a computer programme utilized (Lucia G Version 4.61).

The median, arithmetical mean, minimum, maximum and standard deviations were calculated for quantity of ticks obtained from examined dogs. The values were calculated using standard mathematical formulae for these statistics.

RESULTS

Among all collected ticks, 209 obtained from 108 dogs were identified as a species *Ixodes ricinus*, belonging to subfamily *Ixodine*. The vast majority of them (193) were females. Only 16 males were identified. In most cases, 1 dog was infected with 1-2 ticks (Fig. 1) and the arithmetical mean amounted to $\bar{x} = 1.9$ of tick for 1 dog

Table 1. Quantity of ticks feeding on dogs.

	Minimal value	Maximal value	Median	Arithmetical mean	Standard deviation
No. of <i>I. ricinus</i> found in 108 dogs	1	12	1.0	1.9	1.9
No. of <i>D. reticulatus</i> found in 208 dogs	1	16	1.0	1.8	2.1

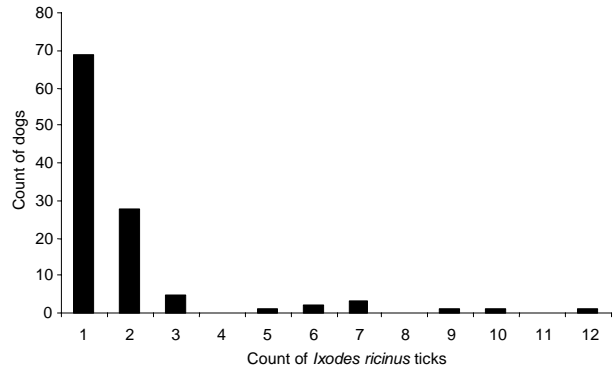


Figure 1. No. of *Ixodes ricinus* ticks feeding on dogs.

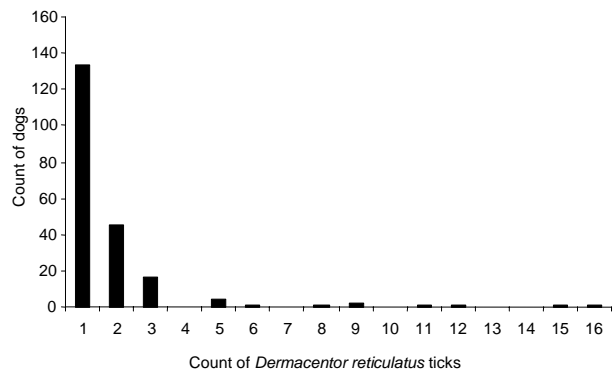


Figure 2. No. of *Dermacentor reticulatus* ticks feeding on dogs.

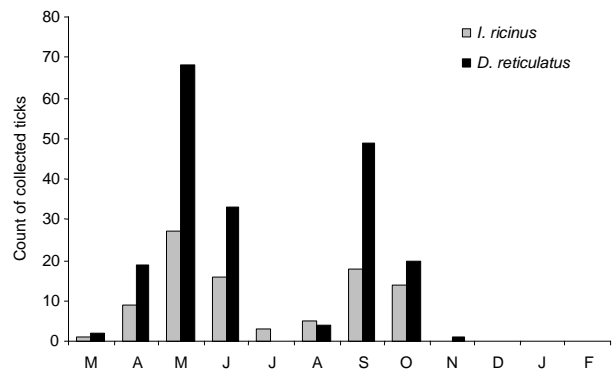


Figure 3. Seasonal activity of ticks feeding on dogs 2003-2004.

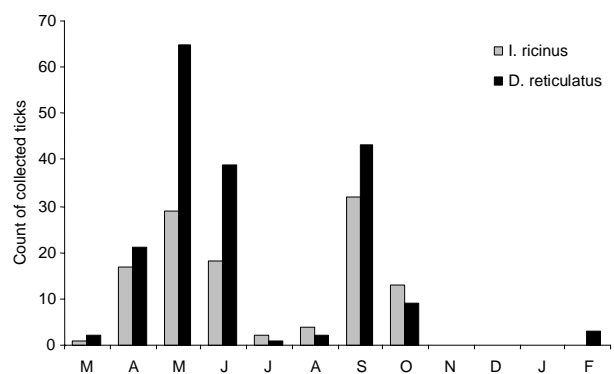


Figure 4. Seasonal activity of ticks feeding on dogs 2004-2005.

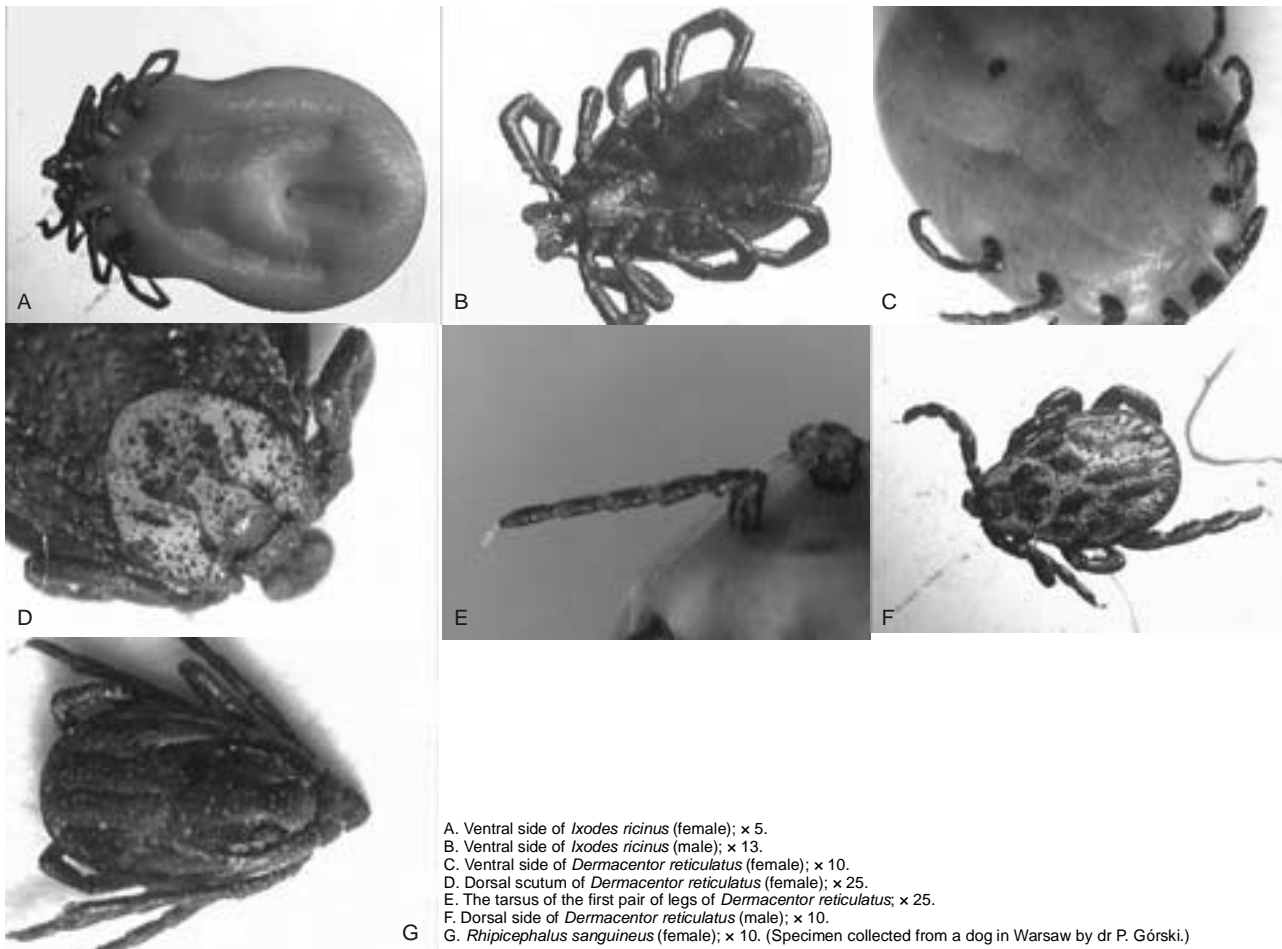


Figure 5. Tick species Photos: Wojciech Zygnier, Warsaw.

with standard deviation $s = 1.9$. Maximally, 1 dog was infected with 12 ticks (Tab. 1).

Among all collected ticks, 381 obtained from 208 dogs were identified as a species *Dermacentor reticulatus*, belonging to subfamily *Amblyomminae*. Among them, 137 males and 244 females were collected. Alike *I. ricinus*, in most cases 1 *D. reticulatus* tick fed on 1 dog (Fig. 2), but the arithmetical mean amounted to $\bar{x} = 1.8$ with standard deviation $s = 2.1$. Maximal quantity of *D. reticulatus* ticks fed on 1 dog was 16 (Tab. 1).

These species had 2 peaks in seasonal activity in Warsaw: higher in May and lower in September (Fig. 3, Fig. 4).

The identification of these 2 species of ticks was confirmed, based on anatomical differences. The characteristic trait for subfamily *Ixodinae*, genus *Ixodes* is an anal groove surrounding the anus forward (Fig. 5A). The female ticks from subfamily *Ixodinae*, genus *Ixodes*, subgenus *Ixodes* have a genital opening at the level of the fourth pair of the coxae of legs (Fig. 5A), while the male ticks have a genital vent at the level of the third pair of the coxae of legs (Fig. 5B). Collected ticks from subfamily *Ixodinae* were classified to subgenus *Ixodes*. A second hip, narrower than third hip, and a front lip 5-fold to 6-fold

longer than the back lip in the genital opening are characteristic for ticks from the *Ixodes ricinus* species.

The characteristic trait for subfamily *Amblyomminae* are: an anal groove surrounding the anus from the back, and a garland on the back margin of idiosoma (Fig. 5C). The ticks from subfamily *Amblyomminae* possess a white pigmented area on the dorsal scutum (Fig. 5D), characteristic for genus *Dermacentor*. The tarsus of the first pair of legs without circuitous sulcus near the peak (Fig. 5E), and the genital opening at the level of the second pair of the coxae of legs without pterygoid appendages (Fig. 5C) were identified as parts of *Dermacentor reticulatus* tick. Male ticks belonging to species the *D. reticulatus* have a white pigmented area on the dorsal side (Fig. 5F).

DISCUSSION

This is the first report of occurrence of *Dermacentor reticulatus* tick on dog in Warsaw and the first study of occurrence of domestic hard ticks on dogs in the Warsaw area.

Although both tick species identified in the present study have been previously reported in Poland,

Dermacentor reticulatus has been found mostly in the north-eastern part of the country, especially in areas inhabited by elks which are described as a main host of this species [28]. Eight endemic areas for this species have been reported: Augustów Forest, Biebrza National Park, Knyszyn Forest, Białowieża National Park, Poleski National Park, Strzeleckie Forest, the Pobuże Region and the Piska Primeval Forest. Until now, only a single specimen of *Dermacentor reticulatus* (male found on elk) has been reported from the Warsaw area [20].

Ixodes ricinus tick occurs in all regions of Poland. This tick species infests many hosts. It is the most often reported species of hard ticks in Poland [28]. Despite this, the result of this study shows that *Dermacentor reticulatus* more frequently infests dogs in Warsaw than *Ixodes ricinus*. Perhaps *Canis familiaris* should be considered as one of the main hosts of *Dermacentor reticulatus* in the Warsaw region.

The male of *Ixodes ricinus* is smaller than the male of *Dermacentor reticulatus*, and the latter is easier to spot. Perhaps it is for this reason that males of *Dermacentor reticulatus* were found more frequently during clinical examination of dogs in veterinary clinics than males of *Ixodes ricinus*.

Similar investigations to those reported in the present paper were performed on dogs in Hungary [13] and in Mozambique [24]. In Hungary, Foldvari and Farkas [13] collected 900 ticks from dogs and among them identified 6 species: *Dermacentor reticulatus* (48.9%), *Ixodes ricinus* (43.2%), *Ixodes canisuga* (5.6%), *Haemaphysalis concinna* (2%), and single specimens of *Dermacentor marginatus* and *Ixodes hexagonus*. It should be pointed out that, as in our study, the majority of ticks found on dogs in Hungary were classified as *D. reticulatus*. In Mozambique, Neves *et al.* [24] collected from dogs 89 ticks belonging to 2 species: *Rhipicephalus sanguineus* and *Haemaphysalis leachi*.

Rhipicephalus sanguineus (known as a brown dog tick) has also been found on dogs in Warsaw and in private flats (Fig. 5G). This species could be brought into Poland with dogs travelling from southern Europe, but there are also reports of dogs infested with *R. sanguineus* which had never been abroad [28]. However, the regions of possible occurrence of brown dog tick in natural environment have not yet been identified in Poland [29].

The majority of examined dogs did not show clinical signs of tick-borne diseases. An enlargement of lymph nodes accessible in clinical examination was noted in 17 dogs infected with *D. reticulatus*. An increase of temperature above the normal value was noted in 21 dogs infected with *D. reticulatus* and in 4 dogs infected with *I. ricinus*. Dehydration was detected in 14 dogs, pallor of mucosae in 5 dogs and hemoglobinuria in 2 dogs infected with *D. reticulatus*. An erythema in the tick attachment site was noted in 28 dogs infected with *I. ricinus* and in 2 dogs infected with *D. reticulatus*. These signs suggest canine babesiosis. This supposition is confirmed by results of the previous study [6, 16, 31].

In summary, results of our study show for the first time that *D. reticulatus* is a major tick species attacking dogs in the Warsaw area. This fact implies a necessity for further studies on the prevalence of important dog pathogens such as: *Ehrlichia* sp., *Babesia canis canis* in this tick in order to assess the threat of diseases caused by these microorganisms.

Acknowledgments

We are very grateful to the surgeons in veterinary clinics in Warsaw (Multiwet Clinic, Fiolka Clinic, Lecznica dla zwierząt Przy Bażantarni, Kabackie Centrum dla Zwierząt, Lecznica zwierząt Janusz Gawliński, and the Clinic for Small Animals in the Warsaw Agricultural University) for assistance with the collection of ticks.

We also thank dr Paweł Górski (Division of Parasitology, Department of Preclinical Sciences, Faculty of Veterinary Medicine, Warsaw Agricultural University) for *Rhipicephalus sanguineus* tick.

REFERENCES

1. Aguirre E, Sainz A, Dunner S, Amusatgeui I, Lopez L, Rodriguez-Franco F, Luaces I, Cortes O, Tesouro MA: First isolation and molecular characterization of *Ehrlichia canis* in Spain. *Vet Parasitol* 2004, **125**(3-4), 365-372.
2. Alekseev AN, Dubinina HV, Van De Pol I, Schouls LM: Identification of *Ehrlichia* spp. and *Borrelia burgdorferi* in *Ixodes* ticks in the Baltic Regions of Russia. *J Clin Microbiol* 2001, **39**(6), 2237-2242.
3. Bacellar F, Dawson JE, Silveira CA, Filipe AR: Antibodies against Rickettsiaceae in dogs of Setubal, Portugal. *Cent Eur J Publ Health* 1995, **3**(2), 100-102.
4. Boch J: *Babesia* infections in horses, cattle and dogs in southern Germany. *Tierarztl Prax* 1985, **Suppl. 1**, 3-7.
5. Boczek J, Błaszczak C: *Roztocze (Acari). Znaczenie w Życiu i Gospodarce Człowieka*. Wydawnictwo SGGW, Warszawa 2005.
6. Caccio SM, Antunovic B, Moretti A, Mangili V, Marinculic A, Baric RR, Slemenda SB, Pieniazek NJ: Molecular characterisation of *Babesia canis canis* and *Babesia canis vogeli* from naturally infected European dogs. *Vet Parasitol* 2002, **106**(4), 285-292.
7. Cocco R, Sanna G, Cillara MG, Tola S, Ximenes L, Pinnaparaglia ML, Masala G: Ehrlichiosis and rickettsiosis in a canine population of Northern Sardinia. *Ann N Y Acad Sci* 2003, **990**, 126-130.
8. Criado-Fornelio A, Gonzalez-del-Rio MA, Buling-Sarana A, Barba-Carretero JC: Molecular characterization of a *Babesia gibsoni* isolate from a Spanish dog. *Vet Parasitol* 2003, **117**(1-2), 123-129.
9. Duh D, Tozon N, Petrovec M, Strasek K, Avsic-Zupanc T: Canine babesiosis in Slovenia: molecular evidence of *Babesia canis canis* and *Babesia canis vogeli*. *Vet Res* 2004, **35**(3), 363-368.
10. Egenvall A, Bonnett BN, Gunnarsson A, Hedhammar A, Shoukri M, Bornstein S, Artursson K: Sero-prevalence of granulocytic *Ehrlichia* spp. and *Borrelia burgdorferi* sensu lato in Swedish dogs 1991-1994. *Scand J Infect Dis* 2000, **32**(1), 19-25.
11. Estrada-Pena A, Jongejans F: Ticks feeding on humans: a review of records on human-biting Ixodoidea with special reference to pathogen transmission. *Exp Appl Acarol* 1999, **23**(9), 685-715.
12. Foldvari G, Hell E, Farkas R: *Babesia canis canis* in dogs from Hungary: detection by PCR and sequencing. *Vet Parasitol* 2005, **127**(3-4), 221-226.
13. Foldvari G, Farkas R: Ixodid tick species attaching to dogs in Hungary. *Vet Parasitol* 2005, **129**(1-2), 125-131.
14. Gothe R: *Ehrlichia canis* infections of dogs in Germany. Epidemiology, diagnosis, therapy and prophylaxis. *Tierarztl Prax Ausg K Klientiere Heimtiere* 1998, **26**(6), 396-401.
15. Gould DJ, Murphy K, Rudolf H, Crispin SM: Canine monocytic ehrlichiosis presenting as acute blindness 36 months after importation into the UK. *J Small Animal Practice* 2000, **41**(6), 263-265.

16. Górski P, Kotomski G, Bogdanowicz M, Gajewska A: Zmiany w składzie gatunkowym pasożytów psów i kotów z Warszawy i okolic w latach 1974-2002. Część I. Pierwotniaki. *Życie Wet* 2004, **79(2)**, 88-92.
17. Harrus S, Waner T, Bark H, Jongejan F, Cornelissen AWCA: Recent Advances in Determining the Pathogenesis of Canine Monocytic Ehrlichiosis. *J Clin Microbiol* 1999, **37(9)**, 2745-2749.
18. Homer MJ, Aguilar-Delfin I, Telford 3rd SR, Krause PJ, Persing DH: Babesiosis. *Clin Microbiol Rev* 2000, **13(3)**, 451-469.
19. Jenkins A, Kristiansen B, Allum A, Aakre RK, Strand L, Kleveland EJ, Van De Pol I, Schouls L: *Borrelia burgdorferi* sensu lato and *Ehrlichia* spp. in *Ixodes* ticks from southern Norway. *J Clin Microbiol* 2001, **39(10)**, 3666-3671.
20. Krzemiński JK: Przyczynę do znajomości pasożytów zewnętrznych łościa, *Alces* (L.) w Polsce. *Wiad Parazytol* 1968, **14**, 83-85.
21. Lappin MR: Infectious diseases. In: Nelson RW, Couto CG (Eds): *Small Animal Internal Medicine*, 1229-1321. 3rd ed. Mosby Publishing, St. Louis 2003.
22. Martinod S, Gilot B: Epidemiology of canine babesiosis in relation to the activity of *Dermacentor reticulatus* in southern Jura (France). *Exp Appl Acarol* 1991, **11(2-3)**, 215-222.
23. Mylonakis ME, Koutinas AF, Baneth G, Polizopoulou Z, Fytianou A: Mixed *Ehrlichia canis*, *Hepatozoon canis*, and presumptive *Anaplasma phagocytophilum* infection in a dog. *Vet Clin Pathol* 2004, **33(4)**, 249-251.
24. Neves L, Afonso S, Horak IG: *Ixodid* ticks on dogs in southern Mozambique. *Onderstepoort J Vet Res* 2004, **71(4)**, 279-283.
25. Płoneczka K, Śmiełewska-Łoś E: Występowanie przeciwciał swoistych dla *Ehrlichia canis* u psów z terenu południowo-zachodniej Polski. *Med Wet* 2003, **59(11)**, 1005-1008.
26. Pusterla N, Pusterla JB, Deplazes P, Wolfensberger C, Muller W, Horauf A, Reusch C, Lutz H: Seroprevalence of *Ehrlichia canis* and of canine granulocytic *Ehrlichia* infection in dogs in Switzerland. *J Clin Microbiol* 1998, **36(12)**, 3460-3462.
27. Shaw SE, Day MJ, Birtles RJ, Breitschwerdt EB: Tick-born infectious diseases of dogs. *Trends Parasitol* 2001, **17(2)**, 74-80.
28. Siuda K: *Kleszcze Polski (Acari: Ixodida). Cz. II. Systematyka i rozmieszczenie*. Polskie Towarzystwo Parazytologiczne. Warszawa 1993.
29. Siuda K: The review of data of the distribution of Ixodida (Acari) in Poland. In: Kropczyńska D, Boczek J, Tomczyk A (Eds): *The Acari, Physiological and Ecological Aspects of Acari-Host Relationships*, 273-280. 1st ed. Oficyna "Dabor", Warszawa 1995.
30. Skotarczak B: Canine ehrlichiosis. *Ann Agric Environ Med* 2003, **10(2)**, 137-141.
31. Sobczyk AS, Kotomski G, Górski P, Wędrychowicz H: Usefulness of touch-down PCR assay for the diagnosis of atypical cases of *Babesia canis canis* in dogs. *Bull Vet Inst Puławy* 2005, **49**, 407-410.
32. Tarello W: Canine granulocytic ehrlichiosis (CGE) in Italy. *Acta Vet Hung* 2003, **51(1)**, 73-90.
33. Zandvliet MM, Teske E, Piek CJ: *Ehrlichia* and *Babesia* infections in dogs in The Netherlands. *Tijdschrift voor diergeneeskunde* 2004, **129(22)**, 740-745.