

Minimally invasive, endovenous laser treatment of varicose veins in patients with von Willebrand disease

Piotr Terlecki¹, Tomasz Zubilewicz¹, Stanisław Przywara¹, Marek Iłżecki¹, Wacław Karakuła¹, Marek Hus², Aleksandra Nowaczyńska², Maciej Kuczyński³

¹ Department of Vascular Surgery and Angiology, Medical University of Lublin, Poland

² Department of Hematooncology and Bone Marrow Transplantation, Medical University of Lublin, Poland

³ Centre of Plastic Surgery of Maciej Kuczyński, Lublin, Poland

Terlecki P, Zubilewicz T, Przywara S, Iłżecki M, Karakuła W, Hus M, Nowaczyńska A, Kuczyński M. Minimally invasive, endovenous laser treatment of varicose veins in patients with von Willebrand disease. *Ann Agric Environ Med.* 2013; 20(4): 880–883.

Abstract

The presented report presents a minimally invasive approach for the treatment of varicose veins in patients with chronic venous disease and coexisting von Willebrand disease, the most common inherited bleeding disorder. Conventional stripping of an insufficient great saphenous vein and varicose vein surgery, carries a potential risk of serious bleeding complications in this specific group of patients. It is related to the extent of open surgery, significant tissue trauma, and possible post-operative bleeding of wounds. Less aggressive techniques, such as endovenous laser treatment or radiofrequency ablation, gain increasing popularity as a valuable and equally efficient alternative to conventional surgery in patients with varicose veins. Both of these endovenous techniques seem to have special indications in patients with bleeding disorders. Shortening of hospitalization, quick recovery time and return to normal daily activities, optimal cosmetic effect of the procedure, are also advantageous. The paper presents the technique and results of endovenous laser treatment of great saphenous vein insufficiency and varicose veins in a patient with type I von Willebrand disease. Available data on peri-operative care standards, optimization of the safety of procedures, and prevention of bleeding complications in surgical patients with von Willebrand disease, specifically undergoing varicose veins surgery are analysed.

Key words

von Willebrand disease, Endovenous laser treatment, Varicose veins, Saphenous Vein – abnormalities

INTRODUCTION

Chronic venous disease (CVD) is currently a common problem. CVD may have various manifestations, from aesthetic to severe medical problems such as venous ulceration or varicose veins thrombosis. Typical symptoms of chronic venous insufficiency include pain, oedema, itching, and night cramps. Conventional stripping or – as a valuable alternative – less invasive, thermal/radial ablation of the great/small saphenous vein are treatment options. Surgical treatment of insufficient great saphenous vein (GSV) leads to tissue damage, disruption of its functions and scarring. Nowadays, endovenous laser treatment (EVL) or radiofrequency ablation (RFA) are becoming increasingly popular because of the potential reduction in postoperative recovery time, in wound related complications, and because of the shortening of hospitalization, and time of returning to normal, daily activities. Better cosmetic effect, without a doubt, is also an advantage. Both endovenous techniques seem to have specific indications in patients with a potentially high risk of postoperative bleeding, such as haemophilia or von Willebrand disease (VWD).

The von Willebrand disease (VWD) is the most common inherited bleeding disorder, with an estimated prevalence of 1% in the general population [1]. It is a consequence of deficient

or defective plasma, the von Willebrand factor (VWF). VWD can be divided into three disease types: type 1 – partial quantitative deficiency, type 2 – qualitative deficiency (groups 2A, 2B, 2M, 2N) and type 3 – total quantitative deficiency [2]. Type 1 was reported to be the most frequent form of VWD, accounting for approximately 70% of cases [3]. Patients with mild disease (in most cases type 1) may be asymptomatic. More severe disease presents with petechiae, easy bruising, spontaneous bleeding from mucosa, menorrhagia or intensive perioperative bleeding [4]. The different treatment options for patients with VWD depend on the clinical severity, risk of bleeding – as in the case of surgery and type of VWD [5]. These include desmopressin /DDAVP, 1-desamino-8-d-arginine vasopressin, which releases endogenous VWF from endothelial cells and exogenous VWF contained in VWF/FVIII plasma-derived concentrates /HaemateP/HumateP/ [4, 6].

OBJECTIVE

Prevention of postoperative bleeding and optimization of the safety of procedures has been reported among various groups of surgical patients with von Willebrand disease. However, there exist only very limited data in the literature regarding varicose vein surgery in patients with VWD. The presented study analyzes the available literature and presents the case of young woman suffering from type 1 VWD and chronic venous disease, C2 in CEAP classification, treated by EVLT.

Address for correspondence: Piotr Terlecki, Chair and Department of Vascular Surgery and Angiology, Medical University of Lublin, Staszica 11 Street, 20-081 Lublin, Poland
e-mail: piotrterlecki@interia.pl

Received: 2 October 2013; accepted: 25 November 2013



MATERIALS AND METHODS

A 32-year-old woman with a history of type 1 VWD, diagnosed when a teenager, was qualified for endovenous laser treatment (EVLT) of an insufficient great saphenous vein (GSV). She presented chronic venous disease: C2 in CEAP classification. GSV diameter measured in the standing position was 7 mm and the minimum distance from the skin was 5 mm. Under ultrasound guidance (5–12 MHz linear array probe, GE Logiq 9) the great saphenous vein was punctured in the infrapopliteal segment, using a 21-gauge needle below the varicose tributaries. A 0.035-inch guide-wire was then inserted and advanced to the saphenofemoral junction under ultrasound guidance. A 5-Fr sheath was subsequently advanced over the guide-wire. The correct position of the laser fibre tip below the epigastric vein was confirmed by ultrasound. Tumescence, local anesthesia was performed by a 21-gauge needle, with a mixture of 150 ml of 0.1% lidocaine solution. The EVLT wavelength used was the 810 nm diode system (Diomed Inc. USA). The laser energy rate used was 14W/40–50J/cm, continuous power. Operation time was 25 minutes. Elastic stocking class II was applied just after the operation for the next 30 days, except during the first week and while sleeping and showering. Low-molecular-weight heparin (LMWH) prophylaxis was not administered postoperatively.

DDAVP intravenous challenge testing was positive, demonstrating von Willebrand factor baseline activity 56.6%, which increased up to 208%, and factor VIII baseline activity of 68.8%, which increased to 262%. An intravenous dose of 0.3 µg/kg DDAVP was administered 1 hour prior to surgical procedure, and then daily for the next two days.

Tranexamic acid was administered intravenously at a regimen of 2g, three times a day for 2 days, and was later continued orally for 7 days at a regimen of 1g three times a day.

In order to 'seal' blood vessels, the patient received etamsylate orally, at a regimen of 500 mg, three times a day for 10 days.

RESULTS

Technical success was fully achieved. Hospitalization lasted 4 days due to the need for VWF parameters monitoring. No major local or bleeding complications were observed. The patient was evaluated clinically and by ultrasound imaging on the day of discharge and at 1, 3, 6, 12 and 18 months after EVLT. Mild pain, local skin burns and superficial haematoma were observed during the first three weeks (Fig. 1). During the follow-up period, one month after the procedure, there was no need to perform complementary

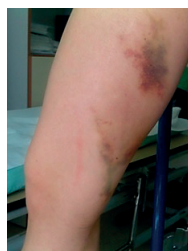

Figure 1. After EVLT of insufficient GSV

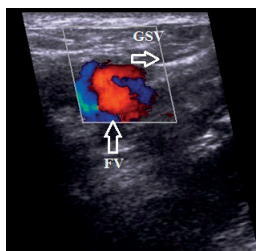


Figure 2. Completely occluded sapheno-femoral junction in ultrasound exam. 18 months follow-up after EVLT (FV – femoral vein)

foam sclerotherapy of varicose tributaries. Cramping and skin pigmentation in ablated GSV area disappeared 3 months after the procedure. At 18 months of follow-up, the trunk of GSV was still occluded (Fig. 2). The very good aesthetic result was maintained (Fig. 3). No serious late complications were noted throughout the entire observation period.

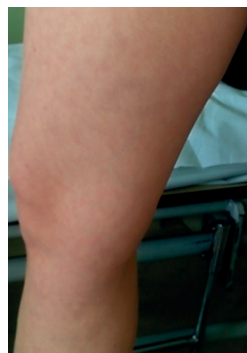

Figure 3. Excellent cosmetic result 18 months after EVLT

DISCUSSION

The treatment of patients with VWD undergoing surgery is challenging because the haemostatic response cannot be accurately predicted. The use and efficacy of DDAVP in patients with von Willebrand disease undergoing EVLT of the insufficient great saphenous vein (GSV) has not been addressed in literature, and there are only a few reports of surgical treatment of CVD in this population of patients. Endovenous laser ablation is commonly used to treat great or small saphenous vein insufficiency, with a high success rate – over 90%, after several years of follow-up –, and carries a low complication rate when compared to surgical stripping in patients without pre-existing coagulopathy [7]. The risk of bleeding in VWD is proportional to the degree of VWF factor deficiency, from mild in type 1 of VWD to high in type 3. Patients with type 1 and some degrees of type 2 can be treated either by DDAVP and plasma-derived VWF/FVIII concentrates /Haemate P, Humate P/.

Desmopressin, a vasopressin analogue, has many actions. It has been found to trigger the release of preformed VWF from storage sites in endothelial cells lining blood vessels. The VWF then binds free factor VIII that has been released from the liver, thereby stabilizing factor VIII against proteolysis. This VWF/FVIII complex supports platelet adhesion by forming a protein bridge between platelets and subendothelial connective tissue at sites of endothelial disruption. Moreover, DDAVP increases the plasma levels of large VWF multimers, which are functionally more active [8, 9].

After delivery, the levels of FVIII and VWF reach their maximum within the first hour [5] and remain normal for 5–6 h [10]. The rise in FVIII and VWF antigen (VWF:Ag) activity reaches a peak, approximately 3 to 4 times of the baseline level. It is generally accepted that a DDAVP test – to assess the efficacy of the drug – should always be undertaken in type 1 VWD and never undertaken in type 3 because of the a priori lack of efficacy. The successful use in many cases, including type 2, has led to the suggestion that these patients should also be tested.

A more frequent use of DDAVP is associated with a reduction in effect (tachyphylaxis). This is due to emptying of the storage organelles that first need to be

replenished. Repeated administration of DDAVP earlier than 8 hours after the first administration is therefore less effective [5].

DDAVP is the treatment of choice for type 1 patients with baseline von Willebrand factor levels of 10 IU dL⁻¹ or higher. At the prescribed intravenous dose of 0.3 µg kg⁻¹, this drug has been shown to induce a total or partial biologic response in 96% of type 1 VWD patients [11]. DDAVP is generally well tolerated, although associated with transient side-effects, such as headache, facial flush and mild tachycardia. Serious side-effects include myocardial infarction; therefore, the drug should not be used in patients with unstable coronary disease [12]. It also has an antidiuretic activity, which is usually inconsequential in patients with normal renal function, in whom a free water intake is limited (to 1,500–2,000 mL per day), provided that the drug is not administered more frequently than at the prescribed intervals of 12–24 h [11]. It is important to limit fluid intake and the serum concentration of sodium should be also monitored during treatment time [8]. Risk factors for hyponatraemia following DDAVP administration have been listed to be hepatic disease, renal dysfunction, surgery, excessive fluid intake, stress, pain and increased doses of DDAVP [13].

Antifibrinolytic therapy plays an important adjunctive role in the effective treatment of bleeding, particularly mucocutaneous bleeding. Tranexamic acid has antifibrinolytic activity by binding plasminogen, thereby blocking the binding of plasminogen to fibrin and its activation and transformation into plasmin. It has a wide use in connection with almost all types of surgery [14]. Tranexamic acid is given intravenously or orally at a dosage of 2–4 g /24 h, divided into 2 or 3 portions [4].

Patients with VWD may be given short- or long-term prophylaxis. Short-term usually prevents bleeding following surgery or other invasive procedures, while the purpose of long-term prophylaxis is to control recurrent bleeding in more severe forms of VWD, usually in patients with type 3 disease who have recurrent haemorrhages in the joints or in the gastrointestinal tract [15].

The first successful clinical trial with DDAVP was conducted in 1977, with its application in a patient with mild haemophilia or VWD who underwent dental extraction [16]. Treatment with DDAVP has been also described in a few other studies, documenting success with an efficacy rate ranging from 91 – 100% [17, 18]. Most patients with VWD type 1 adequately respond to DDAVP, but patients with type 2 may respond insufficiently and those with type 3 do not respond at all. Shah et al. [9] formulated a treatment protocol in patients with VWD, which incorporates medical and surgical considerations. Before procedure, each patient is evaluated by a haematologist and the surgeon to determine the type of VWD and the appropriateness of surgery. Surgical risks, with special emphasis on intra- and post-operative bleeding complications, are reviewed with the patient by the surgeon and the haematologist and weighed against the potential benefits of surgery. Further pre-operative instructions include avoidance of all antiplatelet drugs (especially aspirin and other non-steroidal anti-inflammatory medications) and intramuscular injections. In patients with VWD type 1 or 2A, DDAVP at the dose of 0.3 µg/kg is given intravenously over 30 minutes, starting 30 – 60 minutes before the procedure. Another dose of DDAVP is given 24 hours after the procedure. Intra-operative management of VWD is manifold and consists of all measures to avoid bleeding.

Also close attention to local haemostasis during the operation (eg. sutures, cautery, wound packing) is fundamental. If excessive intra-operative bleeding is encountered, additional doses of FVIII/VWF concentrates should be given. In VWD patients who cannot respond to DDAVP, FVIII/VWF concentrates are the first line therapeutic agents [19].

Some studies recommend the administration of VWF/FVIII in concentrates as a prophylaxis in VWD patients undergoing surgical procedures [20, 21, 22, 23]. The literature documents that doses of 20–50 IU/kg of VWF/FVIII concentrates given once daily are haemostatically effective in preventing bleeding in the majority of surgical or invasive procedures. A publication [11] describing administration of desmopressin for adenotonsillectomy included 144 patients. Early bleeding occurred in 7% of cases and 8% had a late bleeding (more than 24 hours after operation). In the same group of 106 patients who had sodium plasma level monitored, 56 presented mild hyponatraemia. Another report in patients undergoing saphenectomy, no bleeding complications were noted after the operation [24].

Accumulation of FVIII, both exogenously infused and endogenously synthesized and stabilized by infused VWF, may cause very high FVIII levels when multiple infusions are given to cover major surgery. Sustained high levels of VWF/FVIII may increase the risk of deep vein thrombosis (DVT). However, this is a rare event, reported only in patients with concomitant risk factors [25].

DDAVP is effective not only in type 1 and some cases of type 2 VWD, but also in mild haemophilia, and usually permits the avoidance of coagulation factor concentrates administration, with a significant reduction in costs.

CONCLUSIONS

Endovenous laser ablation of incompetent great saphenous vein is a safe and efficient method, and seems to be a valuable and preferable alternative to open surgery in patients with chronic venous disease and concomitant haemophilia or von Willebrand disease.

REFERENCES

1. Rodeghiero F, Castaman G, Dini E. Epidemiological investigation of the prevalence of von Willebrand's disease. *Blood* 1987; 69: 454–459.
2. Castaman G, Montgomery RR, Meschengieser SS, Haberichter SL, Woods AI, Lazzari MA. Von Willebrand's disease diagnosis and laboratory issues. *Haemophilia* 2010; 16(5): 67–73.
3. Federici A. Prophylaxis of bleeding episodes in patients with von Willebrand disease. *Blood Transfus*. 2008; 6(2): 26–32.
4. Zdziarska J, Chojnowski K, Klukowska A, Łętowska M, Mital A, Podolak-Dawidziam M, Windyga J, Zawilska K on behalf of The Working Group of Polish Society of Haematology and Blood Transfusion Medicine. The management of von Willebrand disease. *Med Praktyczna* 2008; 12: 1–24.
5. Schnepfenheim R, Budde U. Treatment of von Willebrand Disease. *Von Willebrand Disease and von Willebrand Factor. Current aspects of diagnosis and treatment.* UNI-MED Verlag AG Bremen-London-Boston 2008; 68–73.
6. Nitu-Whalley IC, Griffioen A Harrington Ch, Lee ChA. Retrospective review of the Management of Elective Surgery With Desmopressin and Clotting Factor Concentrates in Patients With von Wilebrand Disease. *Am J Hematol*. 2001; 66: 280–284.
7. Geier B, Stücker M, Hummel T, Burger P, Frings N, Hartmann M, Stenger D, Schwahn-Schreiber C, Schonath M, Mumme A. Residual stumps associated with inguinal varicose vein recurrences: A multicenter study. *Eur J Vasc Endovasc Surg*. 2008; 36: 207–210.



8. Lethagen S. Haemostatic treatment in connection with surgery in patients with von Willebrand disease. *Haemophilia* 1999; 5(2): 64–67.
9. Shah SB, Lawani AK, Koerper MA. Perioperative Management of von Willebrand's Disease in Otolaryngologic Surgery. *The Laryngoscope* 1998; 108: 32–36.
10. Federici AB, Castaman G, Thompson A, Berntorp E. Von Willebrand's disease: clinical management. *Haemophilia* 2006; 12(3): 152–158.
11. Santoro C, Hsu F, DiMichele DM. Haemostasis prophylaxis using single dose desmopressin acetate and extended use epsilon aminocaproic acid for adenotonsillectomy in patients with type 1 von Willebrand disease. *Haemophilia* 2012; 18(2): 200–204.
12. Pascheco L, Constantine, Saade G, Mucowski S, Hankins GD, Sciscione AC. Von Willebrand disease and pregnancy: a practical approach for the diagnosis and treatment. *Am J Obstet Gynecol.* 2010; 203(3): 194–200.
13. Shindel A, Tobin G, Klutke C. Hyponatremia associated with desmopressin for treatment of nocturnal polyuria. *Urology* 2002; 60: 344.
14. Lethagen S. Desmopressin (DDAVP) treatment. *Hemophilia. Octafarma* 2004: 72–76.
15. Mannucci PM. Treatment of von Willebrand's disease. *N Engl J Med.* 2004; 351: 683–694.
16. Mannucci S., Ruggeri Z., Pareti F., Capitanio A. A new pharmacological approach to the management of hemophilia and von Willebrand disease. *Lancet* 1977; 1: 869–872.
17. Federici A, Sacco R, Stabile L, Carpenedo M, Zingaro E, Mannucci PM. Optimizing local therapy during oral surgery in patients with von Willebrand disease: effective results from a retrospective analysis of 63 cases. *Haemophilia* 2000; 6: 71–77.
18. Leissinger C, Becton D, Cornell C Jr, Cox Gill J. High-dose DDAVP intranasal spray (Stimate) for the prevention and treatment of bleeding in patients with mild haemophilia A, mild or moderate type I von Willebrand disease and symptomatic carriers of haemophilia A. *Haemophilia* 2001; 7: 258–66.
19. Bernstein J, Cox Gill J, Leissinger C, Humate P Study Group. Safety and efficacy of von Willebrand factor/factor VIII concentrate (Humate P) for prophylaxis of excessive bleeding elective surgery in patients with von Willebrand disease. *Blood* 2006; 108 abstract 4076.
20. Federici A, Castaman G, Franchini M, Morfini M, Zanon E, Coppola A, Tagliaferri A, Boeri E, Mazzucconi MG, Rossetti G, Mannucci PM. Clinical use of Haemate P in inherited von Willebrand disease: a cohort study on 100 Italian patients. *Haematologica* 2007; 92: 944–951.
21. Lethagen S, Kyrle P, Castaman G, Haertel S, Mannucci PM, HAEMATE P Surgical Study Group. Von Willebrand factor/factor VIII concentrate (Haemate P) dosing based on pharmacokinetics: a prospective multicenter trial in elective surgery. *J Thromb Haemost.* 2007; 5: 1420–1430.
22. Borel-Derlon A, Federici A, Roussel-Robert V, Goudemand J, Lee CA, Scharrer I, Rothschild C, Berntorp E, Henriot C, Tellier Z, Bridey F, Mannucci PM. Treatment of severe von Willebrand disease with a high-purity von Willebrand factor concentrate (Wilfactin): a prospective study of 50 patients. *J Thromb Haemost.* 2007; 5: 1115–1124.
23. Castaman G., Tosetto A., Federici A., Rodeghiero F., Bleeding tendency and efficacy of anti-haemorrhagic treatments in patients with type 1 von Willebrand disease and increased von Willebrand factor clearance. *Thromb Haemost.* 2011; 105: 647–654.
24. Manucci P. Treatment of von Willebrand disease. *N Eng J Med.* 2004; 351: 683–694.
25. Federici A. Management of von Willebrand disease with factor VIII/von Willebrand factor concentrates: results from current studies and surveys. *Blood Coagulation and Fibrinolysis* 2005; 16: S17-S21.

