

# Retrospective epidemiological study of supracondylar fractures of the humeral bone in children from urban and rural areas of the Lublin region in eastern Poland

Łukasz Matuszewski, Marek Okoński

Paediatric Orthopaedic and Rehabilitation Clinic, Medical University, Lublin, Poland

Matuszewski Ł, Okoński M. Retrospective epidemiological study of supracondylar fractures of the humeral bone in children from urban and rural areas of the Lublin region in eastern Poland. *Ann Agric Environ Med.* 2013; 20(2): 401–404.

## Abstract

**Introduction.** Supracondylar fractures of the humeral bone are frequent injuries in children. It has been affirmed that supracondylar fractures have an excellent prognosis when proper treatment is applied.

**Objective.** Present of the statistical relationships between fractures occurring and patient's development period; the relation between development period and site of the fracture and statistical relationship between development period and gender of the patients. Also indicated are the place of residence of the hospitalized patients and time of admission to the Clinic after injury.

**Materials and method.** Research was based on the data of paediatric patients treated in the Clinic for Paediatric Surgery, Traumatology and Paediatric Orthopaedics, and Rehabilitation Clinic of the Medical University in Lublin, Poland, between 1986–2010. An independent Chi-square Test was used for statistical analysis ( $\chi^2$ ).

**Results.** The majority of patients were admitted to the Clinic on the day of injury. Of these patients, 71% lived in the urban area of the Lublin region where all the children received medical care in hospital directly after trauma; 29% of children came from the rural areas of the Lublin region, and 10% of them were admitted to hospital 24 or more hours after the injury.

**Conclusion.** 71% of patients lived in the urban areas of the Lublin region and the main cause of injury was a fall from a higher level onto an outstretched upper left limb. Most supracondylar fractures of the humeral bone concerned children at school and adolescent age. Despite the fact that some of the hospitalised children lived in the rural areas of the Lublin region, the majority were admitted to the Clinic directly after trauma and received timely treatment.

## Key words

supracondylar fractures, children, paediatric orthopaedic

## INTRODUCTION

Supracondylar fractures of the humeral bone are the most frequent injuries in children. The frequency of occurrence among other fractures of the elbow region has been estimated at around 70% [1, 2, 3, 4]. This type of paediatric bone injury holds an important place in the treatment of fracture. Supracondylar fractures have an excellent prognosis when proper management and treatment are applied. However, diagnostic and treatment procedures are sometimes inadequate and may cause severe complications. Treatment of type I and II supracondylar fractures in children used to be easy; however, in type III of the fractures with disturbance of blood flow in distal part of upper limb (*pulseless pale hand*), might be quite difficult. Operating treatment is required in fractures with permanent blood flow disturbance in the distal part of upper limb (*pulseless pale hand*), but not necessary in fractures with perfused but pulseless hand (*pulseless pink hand*) [5].

Volkman's contracture represents the most severe complication after supracondylar fractures. Fortunately, it has become a rarity [6, 7, 8]. Many studies have concentrated on the diagnostic and treatment procedures for such

fractures and their complications, and the the presented study emphasises some epidemiological patterns [9, 10, 11].

## OBJECTIVE

The main aim of the presented study was to present statistical relationships between the occurrence of the fractures and the patient's development period; relationship between the development period and site of the fracture, and statistical relationship between development period and gender of the patients. Also indicated are the main causes and mechanism of this particular type of injury in childhood, together with the place of residence of the hospitalized patients and time of admission to the Clinic after the injury.

## MATERIALS AND METHOD

On the basis of the data of 690 patients treated in the Clinic of Paediatric Surgery and Traumatology and Paediatric Orthopaedic and Rehabilitation Clinic of the Medical University in Lublin, Poland, between 1986–2010, supracondylar fractures of the humeral bone have been presented, together with the presentation of the causes and mechanism of the injury, involving 495 male and 193 female patients. All cases were divided among groups according to

Address for correspondence: Łukasz Matuszewski, Paediatric Orthopaedic and Rehabilitation Clinic, Medical University, Lublin, Chodźki 2, 20-093 Lublin, Poland  
e-mail: lukasz.matuszewski@am.lublin.pl

Received: 27 February 2012; accepted: 25 February 2013



the Chrząstek-Spruch scale [12], which concerns the patient's development period.

International anatomical nomenclature was used in the morphological descriptions of the fractures encountered. In statistic analysis, an independent Chi Square Test  $\chi^2$  was used. The final results were obtained with the use of the 'Statistica' programme (StatSoft, Poland) based on significant level  $p < 0.05$ .

## RESULTS

Supracondylar fractures of the humeral bone were examined 690 patients. Following analysis of the line of the fracture, 2 types of injuries emerged. In children, the supracondylar region encompasses an area of thin, weak bone located in the distal humerus. This region is bordered posteriorly by the olecranon fossa and anteriorly by the coronoid fossa. Concerning the mechanism of the accidents, 681 cases were of the typical 'extension type' with posterior dislocation of distal fragment of fracture (Fig. 1). In only 9 patients a 'flexion type' fracture was seen with anterior dislocation of distal fragment of fracture.

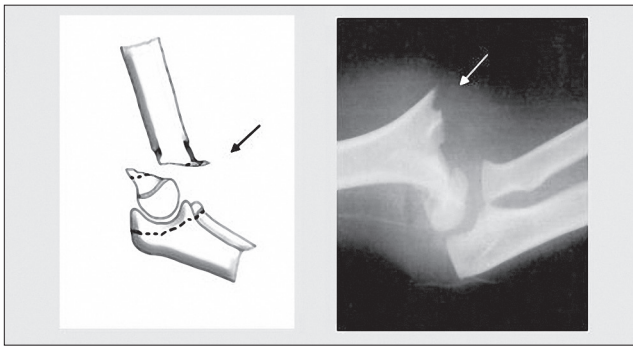


Figure 1. Extension type of the supracondylar fracture of the humeral bone.

**Type I. Extension type of fracture, with the line of fracture extending horizontally or obliquely and extending upwards and posteriorly in the distal part of the humeral bone.** Depending on the severity of the fracture, posterior displacement of the distal fracture fragment and anterior displacement of the proximal fracture fragment may occur. In analysis of the displacement of the broken fragments, the Gartland classification has been used. All analysed fractures were Gartland II or III type (Fig. 2).

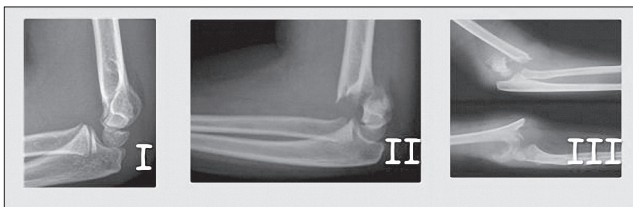

Figure 2. Gartland classification.

63% of fractures were caused by a fall from height. In 35% of the patients, the injury occurred due to a fall from a height. 2% of fractures were caused by direct trauma on the elbow joint, while 9 of them occurred during agricultural or farm activities. Among the patients there were 490 (72%) males and 191 (27%) females. 365 (53%) fractures concerned

the left limb and 316 (47%) the right limb. No significant relationship was found between the development period and gender ( $\chi^2 = 3.175$ ;  $p = 0.201$ ). No crucial statistical relationship was found between the development period and side of the fracture ( $\chi^2 = 0.061$ ;  $p = 0.963$ ).

Most of the injuries concerned patients at school and adolescent age, and were rarely observed at kindergarten and pre-school age. An essential relationship was found between the type of fracture and developmental period. ( $\chi^2 = 33.65$ ;  $p < 0.001$ ).

The majority of patients were admitted to the Clinic on the day of injury (660 patients – 96%). 483 (71%) of the patients lived in the urban areas of the Lublin region where all of the children received medical care directly after trauma. 198 of children (29%) came from the rural areas of the Lublin region. 21 (10%) of them were admitted to the hospital 24 or more hours after the injury. However most of them were transferred to our hospital from other regional hospitals in the Lublin region.

30 patients had to be operated because of the development of a 'pulseless pale hand'. Scraping of the brachial artery by the bony fragment occurred, which resulted in intimal damage to the vessel. This kind of injury subsequently leads to thrombosis and vascular insufficiency.

Recovery of the function of the elbow joint was achieved within a period of 6 weeks or even up to 52 weeks, using a Templeton-Graham scale made by Flynn. Good or very good results were observed in 89% of the patients, which means that flexion motion of more than 60 degrees and extension motion of more than 150 degrees was obtained. A quite early recovery of those motions was observed. Rotation motion appeared significantly later in almost all patients, but finally it reached more than 45 degrees of supination and 45 degrees of pronation. However, there were 2 patients with severe Volkman's contracture, and 5 patients with myositis ossificans in the area of the elbow joint. The 2 patients with Volkman's contracture were admitted to the Clinic more than 24 hours after the injury.

**Type II. Flexion type of fracture, with the line of the fracture which extending horizontally or obliquely, descending and posterior in the distal part of humeral bone.** Among the patients in the presented study, this type of fracture was very rare and found in only 9 (1%) patients (Fig. 3). In 6 patients, these fractures were caused by fall from an elevated height. In 3 patients, the injury resulted from a fall from own height.

Among the patients in the presented study, there were 8 boys and 1 girl. The fractures concerned 6 left limbs and 3 right limbs. In type II fractures, no statistical analysis were

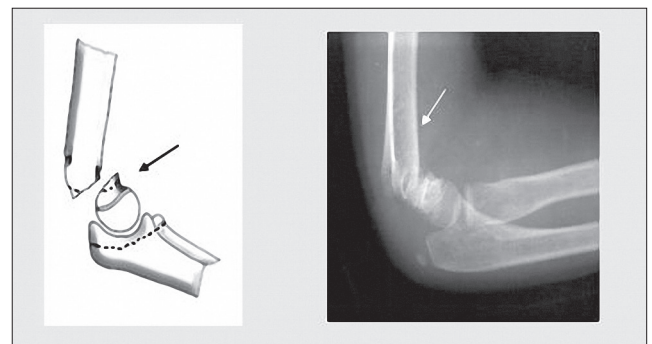


Figure 3. Flexion type of the supracondylar fracture of the humeral bone.



performed because of the small number of patients treated. Most of injuries concerned children at school and adolescent age; none were observed at kindergarden age. All patients lived in the urban areas of the Lublin region, where all of children received first medical care directly after trauma.

All patients were treated by closed reduction and immobilization in a cast for no more than 4 weeks. No complications were observed. Recovery of full range of motion in the elbow joint was obtained after normal post-operative rehabilitation. In a follow-up study, very good results were obtained on the basis of the Templeton-Graham scale made by Flynn.

## DISCUSSION

Supracondylar fracture of the humeral bone is one of the most popular injuries of the children's organs of movement. Koszla [13], Siwek and et al. [14] and Townsed et al. [15] indicate that it is results of the children's curiosity in the surrounding world, games and plays which are the reasons for considerable motor activeness of small patients. Most of those injuries happened in the urban area. However some of them are still caused by various agriculture or farm activities.

Fick and Lyons [7] indicate that the complex development of the elbow joint with numerous ossification centres creates a number of problems in the process of formulating a diagnosis for this type of an injury. Knowledge of the development of the elbow joint and the timing when the ossification centres are developed, as well as the radiological volatility of elbow morphology in a child patient, are thus indispensable in the case of a suspected injury.

The frequency of supracondylar fractures of the proximal part of the humeral bone, compared to other injuries of an elbow joint, was evaluated by Blount [2] and Okłot [16] on the level up to 60%. These fractures mostly occurred among children at school age or at the age of puberty, which matches data presented by other authors [17, 18, 19]. In the majority of cases, fractures were recorded in boys. The majority of elbow joint fractures in male patients were also mentioned by Siwek et al. [14], and Townsed [15]. Supracondylar fractures account for up to 60% of paediatric elbow fractures. Most of them occur due to a fall onto an outstretched arm in up to 70% of patients. The left extremity is most commonly affected. Children under 3 years of age typically sustain a supracondylar fracture after a fall from own height. The majority of fractures in older children result from higher falls from playground equipment. In data subjected to analysis, supracondylar fractures of the humeral bone mainly occurred, as in Okłot's tests [16], in which the line of the fracture extends horizontally or obliquely and rises, posterior in the distal part of humeral bone. This type accounts for 99% of cases. The second type of fracture is very rare in children and youths [5, 7, 8, 12].

In the presented cases of supracondylar fracture of the humeral bone, the principles applied were compliant with the ideas of other authors [20, 21, 22]. Supracondylar fractures require orthopaedic consultation for determination of the appropriate intervention. Most paediatric orthopaedists recommend closed reduction and percutaneous pin fixation [23]. The importance of time of admission to the Clinic must be emphasized. Sometimes, it is a crucial factor, especially in case of any ischemic disturbances of the distal part of

the upper limb. However, in the presented study, no crucial relationship was found between the place of residence and time of admission to the Clinic. Most patients demonstrating considerable ischemic disturbances were operated on within no more than 6 hours after injury, and the procedure used complied with other points of view [21, 22, 23]. It can be affirmed that nowadays the number of surgical intervention in supracondylar fractures with injuries to the arteries or nerves injuries has declined, as also noted by other authors.

Although complications of supracondylar humeral bone fractures sometimes occur in the paediatric population, the prognosis for long-term outcome and function is very good if the fracture is appropriately diagnosed and treated on time [5]. Nevertheless, complications are still caused by problems with a detailed diagnosis of this kind of injury, differences in opinions concerning treatment methods, and finally (but very rarely) by the time delay of surgical intervention.

## CONCLUSION

1. It was noted that 71% of the patients lived in the urban areas of the Lublin region, and that the main cause of this kind of injury was a fall from a higher level onto an outstretched upper left limb.
2. A crucial statistical relationship was observed between the type of injury and development period: most supracondylar fractures of the humeral bone concerned children at school and adolescent age.
3. It was affirmed that despite the fact that some of hospitalised children lived in rural areas of the Lublin region, the majority were admitted to the Clinic directly after trauma and received appropriate and timely orthopaedic treatment.
4. Taking into consideration the specificity of the structure of a child's bone system, accurate diagnostic and treatment procedures allows achievement of the best outcome. However, it has to be emphasized that there is a risk of the development of severe complications.

## REFERENCES

1. de Beaux AC, Beattie T, Gilbert F. Elbow fat pad sign: implications for clinical management. *J R Coll Surg.* 1992; 37: 205–207.
2. Blount WP. *Fractures in children*, Baltimore, MD: Williams and Wilkins. 1955: 211.
3. Chapchal G. *Fractures in children*. New York, NY: Thieme Stratton Inc. 1981: 202.
4. Cheng JC, Lam TP, Shen WY. Closed reduction and percutaneous pinning for type III displaced supracondylar fractures of the humerus in children. *J Orthop Trauma.* 1995; 6: 511–515.
5. Griffin KJ, Walsh SR, Markar S, et al. The pink pulseless hand: a review of the literature regarding management of vascular complications of supracondylar humeral fractures in children. *Eur J Vasc Endovasc Surg.* 2008; 36: 697.
6. Draenert K, Willenegger H, Müller J, Draenert Y. *Distal Humerus Fractures in Children – Results of Clinical Follow-up After Termination of Growth in: Fractures in children.* 1981. New York, Thieme Stratton Inc. 202.
7. Fick DS, Lyons TA. Interpreting elbow radiographs in children. *Am Fam Physician.* 1997; 55: 1278–1281.
8. Gehling H, Gotzen L, Giannadakis K, Hessmann M. *Behandlung und Ergebnisse bei suprakondylaren Humerusfrakturen im Kindesalter.* *Unfallchirurg.* 1995; (98) 2: 93–97.
9. Hasler C. *Supracondylar fractures in children.* *J Bone Joint Surg – British Vol.* 2002; 84-B: 361–364.
10. Judet J, Judet H. *Fractures et orthopedie de l'enfant: indications, techniques, voies d'abord.* 1974. Paris. Maloine. 3042.



11. Kisson N, Galpin R, Gayle M, Chacon D, Brown T. Evaluation of the role of comparison radiographs views of the diagnosis of the traumatic elbow injuries. *J Pediatr Orthop*. 1995; 15: 449.
12. Szajner – Milart I, Papierkowski A. *Medicine of developmental age*. Warsaw. 1997. PZWL. 134.
13. Koszła M. *Fractures and dislocations in children*. Warsaw. PZWL. 1986. 188.
14. Siwek R, Osemlak J, Obel W, Wypyski A. *Elbow's injuries in children. Elbow's injuries., Material from XIV Meeting of Pediatric Trauma Surgery Section Polish Pediatric Surgery Associations*. 1988. Warsaw: 59.
15. Townsend DJ, Basett GS. Common elbow fractures in children. *Am Fam Physician*. 1996; 53: 2031–2033.
16. Okłot K. *Traumatology in children and youth*. Warsaw. 2006. PZWL. 743.
17. von Laer L. *Frakturen und Luxationen im Wachstumsalter*, Stuttgart. Thieme Verl. 2001: 243.
18. von Laer L, Pirwitz A, Vocke AK. Post-traumatic problem cases involving the elbow in children. *Orthopade*. 1997; 26: 1030–1033.
19. Michael A, Matsuzaki K. Treatment of supracondylar fractures in children by skeletal traction and brace. *J Bone Joint Surg – British Vol*. 2005; 87-B: 434–437.
20. Peters CL, Scott SM, Stevens PM. Closed reduction and percutaneous pinning of displaced supracondylar humerus fractures in children: description of a new closed reduction technique for fractures with brachialis muscle entrapment. *J Orthop Trauma*. 1995; 9: 430–434.
21. Sadiq M, Syed, Travlos J. Management of grade III supracondylar fracture of the humerus by straight-arm lateral traction. *Int Orthop*. 2007; 31: 155–158.
22. Skaggs D, Cluck M, Mostofi A, Flynn JM, Kay R. Lateral-Entry Pin Fixation in the Management of Supracondylar Fractures in Children. *J Bone Joint Surg. (American)*. 2004; 86: 702–707.
23. Wilkins K. Operative management of children's fractures: is it a sign of impetuosity or do the children really benefit? *J Pediatr Orthop*. 1998; 18: 1–3.

