

Uncommon co-infection due to *Moniezia expansa* and *Moniezia benedeni* in young goats from Romania: morphological and histopathological analysis

Olimpia C. IACOB¹, Wael M. EL-DEEB², Sorin-Aurelian PAȘCA³,
Andreea-Ioana TURTOI⁴

¹Department of Parasitology and Parasitic Diseases, Faculty of Veterinary Medicine, University of Agricultural Sciences and Veterinary Medicine "Ion Ionescu de la Brad" in Iași, M. Sadoveanu Alley, 3 no., 799490, Iași, Romania

²Department of Clinical Sciences, College of Veterinary Medicine, King Faisal University, Al-Ahsa 31982, Al-Hofuf P.O. 400, Saudi Arabia

Department of Veterinary Medicine, Infectious Diseases and Fish Diseases, Faculty of Veterinary Medicine, Mansoura University, Mansoura, Egypt

³Department of Pathology, Faculty of Veterinary Medicine, University of Agricultural Sciences and Veterinary Medicine "Ion Ionescu de la Brad" in Iași, M. Sadoveanu Alley, 3 no., 799490, Iassy, Romania

⁴S.C. Farmavet S.A. Iași Branch, Industriilor Street, no.16 Uricani, Romania

Corresponding Author: Olimpia IACOB; e-mail: iacobolimpia@yahoo.com

ABSTRACT. Digestive parasitoses negatively affect the goat's health, the gain weight of the kids, the efficiency of food conversion, fertility, and productivity, causing important economic losses. This investigation was carried out on a group of goats, Carpathian breed, in the hill area of Tg. Frumos-Iași, to specify the etiology of the acute digestive syndrome, triggered towards the end of the pasturing season, in the young goats. In this context, four sick animals, aged 6–8 months, were slaughtered. Morphological, pathological, and parasitological examination of dissected animals was conducted. Multiple tapeworms belonging to *Moniezia expansa* and *Moniezia benedeni* species were found. From the duodenum, jejunum, ileum, fragments were taken for the histopathological processing. The identification of the tapeworm species was carried out through morphological differentiation. The prevalence of tapeworm infection in the examined animals was 100% of which *M. expansa* was 56.10% and *M. benedeni* was 43.90%. The average infection intensity was 10.25 tapeworms/animal. The average intensity of infection with *M. expansa* was 7.5 tapeworms/ animal, and with *M. benedeni* it was 4.5 tapeworms/animal. Severe pathological lesions in the small intestine such as occlusion, intestinal obstruction, catarrhal inflammation, total atrophy of intestinal villi, ulcerations were produced by the parasites, which led to the clinical expression of the disease and to direct economic losses. The infection with the *Moniezia benedeni* species is noticed for the first time in Romania, in young goats.

Keywords: young goats, small intestine, *M. expansa*, *M. benedeni*, morphological-histopathological analysis

Introduction

Gastrointestinal helminthoses of the goats cause indirect economic losses, by reducing the quantity of the food, reducing the weight gain, decreasing growth rate of kids, reducing the fertility, diminishing the production, increasing the therapeutic costs and direct through mortality in animals intensely infected [1–3]. Helminthoses constitute the most important health problem of the

goats raised in geographical areas with a lot of rain [4]. The cestodosis of small ruminants is caused by species belonging to the Anoplocephalidae, Avitellinidae, and Thysanosomidae families, *Moniezia*, *Thysaniezia*, *Avitellina*, *Stilesia*, *Thysanosoma* genera, etc. [5]. The infection with *Moniezia* spp. is more frequent in lambs and kids, in the first year of life and, more rarely, is encountered in young and adult animals. In moderate climates, the seasonal fluctuation of the infection with

Moniezia spp. is conditioned by the active periods of the oribatid mites – intermediate host, during summer or autumn [6,7]. The prevalence of cestodes in small ruminants is variable. In some cases, *Moniezia* spp. registered more values in sheep (69.0%), comparatively with goats (55.0%) [8]. In other cases, both sheep and goats were infected with the same species of tapeworms, represented by *Moniezia expansa*, *Avitellina centripunctata*, *Stilesia globipunctata*, and *Stilesia hepatica*, with a similar prevalence, thus, in sheep: 61%, 20%, 24% and 39%; and in goats: 53%, 21%, 27% and 36% [9]. In some geographical areas, the prevalence of tapeworms in goats was very high (94.4%), causing major infections and high mortality [10]. The strategy of surviving and perpetuating the tapeworms consists of producing a very large number of eggs (hundreds of thousands) in a short time, ensuring the highest rate of reproduction known in living bodies [11]. The severe infection with tapeworms affects the growth rate of kids and causes diarrhea, malnutrition, dehydration, weight loss, occlusion or intestinal obstructions, topographic changes of the intestine, and lethal ending [4,6,12]. This paper reports the first time detection of *Moniezia benedeni* species in Romania in young goats and the impact of tapeworms upon the intestinal mucosa and the induced histopathological changes.

Materials and Methods

The investigations were carried out on a group of 86 young goats, Carpathian breed, raised on a farm in Tg. Frumos, Iași area, with an acute enteric syndrome, triggered towards the end of the pasturing season (October). In these conditions, four

animals, aged 6–8 months, were slaughtered and pathological and parasitological examination was conducted. The abdominal cavity was examined and the small intestine was opened. Following the extraction, the tapeworms were washed with distilled water and were preserved in recipients with 70% alcohol. From the duodenum, jejunum, ileum, fragments were taken and they were placed in recipients with 10% formaldehyde, for histopathological processing. After the paraffin embedding, the fragments were sectioned at 5 μ m thickness and were stained by the Masson trichromic method. The examination and the microphotography were done with a Leica DM 750 photonic microscope. The identification of tapeworm species was done by morphological differentiation, using fuchsin and Lügol staining and they were taxonomically registered, according to the specialty [5,13,14].

Results

The macroscopic examination of the abdominal cavity highlighted modifications in the form and volume of the small intestine. The jejunal ansae presented segments with gaseous distention and greenish liquid content. Through the length of the wall, there were observed white, long structures, which dorsoventrally flattened and occupied the intestinal lumen. The opening of the intestine of each animal allowed the visualizing of some tapeworms which occluded or obstructed the lumen, in varying numbers: 9 tapeworms were found in case 1; 11 tapeworms were found in case 2; 8 tapeworms were found in case 3, and 13 tapeworms were found in case 4. In some cases, the intestinal content was liquid, yellowish, and in a reduced

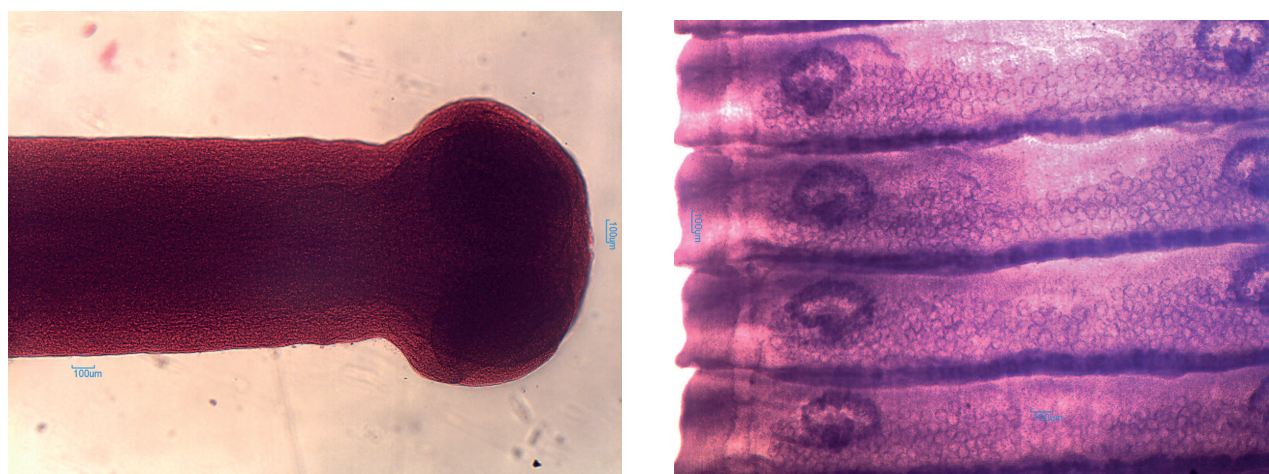
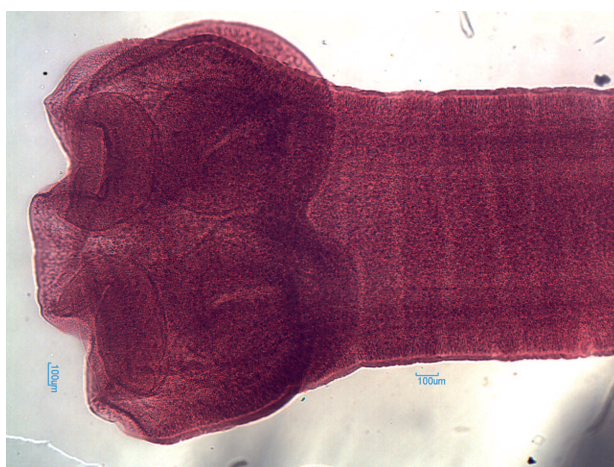

Figure 1 A,B. *Moniezia expansa*: A. scolex and neck (Fuchsin stain); B. mature proglottids (Lügol stain)

Table 1. Prevalence and intensity of infection with *M. expansa* and *M. benedeni* in slaughtered young goats

Slaughtered young goats n=4	No of tapeworms/ animal (n)	<i>Moniezia expansa</i>		<i>Moniezia benedeni</i>	
		(n)	%	(n)	%
Case 1	9	4	44.44	5	55.55
Case 2	11	7	63.63	4	36.36
Case 3	8	5	62.5	3	37.5
Case 4	13	7	53.85	6	46.15
Total number of tapeworms	41	23	56.10	18	43.90
Average intensity	10.25	7.5		4.5	

quantity, and in other cases, the intestinal content was replaced by the body of the tapeworms. The intestinal wall is mildly thickened, presented a velvety, shiny mucosa, covered by catarrhal exudate. The morphological exam of the tapeworms extracted from the intestine of the young goats confirmed the belonging to the Anoplocephalidae family, *Moniezia* genus. The macroscopic and microscopic investigation of the tapeworms confirmed the mixed infection of the young goats with the *M. expansa* and *M. benedeni* species. *Moniezia expansa* has a long flattened and segmented body, white-yellowish; it has 2.0–6.0 m length × 15–25 mm width. The small, globular scolex (0.7 mm), without rostrum, has four oval suckers (Fig. 1A). The neck, unsegmented and long, is followed by the immature area in which the internal structure of the proglottids is a little visible. The mature proglottids are rather wide than long (15.0 × 3.0 mm), have double genital organs, and bilateral genital pores. The ovaries are lobular, recurved, with the concavity placed posteriorly. The vitellogenin glands are found in the concavity of the

Figure 1 C. *Moniezia benedeni*: scolex and neck (Fuchsin stain)

ovaries. The testicles (numerous) are disseminated in the parenchymatous tissue between the ovaries. The inter proglottids glands are follicular, arranged in a line, on the posterior edge of the proglottids, all along its width (Fig. 1B). The ovigerous proglottids are thickened and yellowish. *Moniezia benedeni* has a similar body with *M. expansa* species but translucent and with reduced dimensions, with 1.0–4.0 m length and 10–25 mm width. The scolex is cubic (1.60 mm), without rostrum, with four developed suckers and a short neck (Fig. 1C). The mature proglottids are thin, translucent, rather wide than long (25 × 3.0–5.0 mm). The ovaries are globular, and the interproglottids glands are placed on the posterior edge of the proglottids, only in the central area. These aspects contribute to the morphological differentiation of the two species. The tapeworms extracted from the small intestine of the kids have taxonomically registered in the Anoplocephalidae family *Moniezia* genus, *M. expansa*, and *M. benedeni* species. The prevalence and the intensity of *M. expansa* and *M. benedeni* species in slaughtered young goats are shown in the Table 1.

The prevalence of tapeworms was 100%. The prevalence of the two species has slightly close values in which, *M. expansa* is dominant (56.10%), compared to *M. benedeni* (43.90%). The average intensity of infection was 10.25 tapeworms/animal in which, the intensity of *M. expansa* infection was more (7.5 tapeworms/animal), than the intensity of *M. benedeni* infection (4.5 tapeworms/animal). The tapeworms' aggression on the mucosa of the small intestine was characterized by mucinous dystrophy and catarrhal inflammation of the intestinal epithelium.

The main inflammatory cells identified in the affected tissue were eosinophils, lymphocytes, and histiocytes. Moreover, desquamation of the

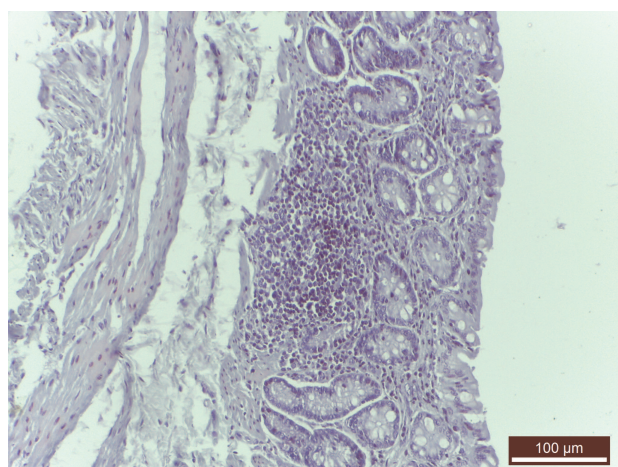


Figure 2. Jejunum. Severe atrophy of intestinal mucosa and inflammatory infiltrate predominantly eosinocytic in the lamina propria (Trichromic Masson stain×100)

epithelium from the surface of the villi, beheading or the halving of the villi, progressive atrophy up to the total atrophy of the mucosa (Fig. 2), aspects which correspond to multiple and brutal aggression in the intestinal mucosa. The reactivity of the intestinal mucosa at the aggression of tapeworms was characterized by hyperemia, edema, lymphohistiocytic and eosinophilic infiltration in lamina propria lymphohistiocytic proliferation in Payer's patches from the submucosa.

Discussion

Globally, the parasitic diseases produce important economic losses in goats, affecting negatively the weight gain of kids, the efficiency of feed conversion, the fertility and reproduction of animals, the nutritional and vitamin-mineral balance, increasing the sensitivity to other diseases [15–17]. The animals who graze are permanently exposed to the parasitic elements and are thus constantly and continuously reinfected [3,18]. The goats which are intensely infected give reduced production, quantitatively, and qualitatively (meat, milk, wool) [19], and in some cases, the mortality rate is high. According to the USDA 2017 statistics, in goats, there has been the highest number of losses through mortality (87.000 goats and kids), caused by internal parasites [20]. Uke et al. [7] showed that the infection with *Moniezia* of the small ruminants leads to a severe pathology with a negative impact upon production. *Moniezia* affects sheep and, especially, lambs, in the first part of the pasturing season and, more rarely, kids. The incidence of

Moniezia in kids is influenced by the way of getting the food, being known the fact that kids prefer sprigs and the superior part of the vegetation, and consequently, avoiding the infection [21]. The oribatid mites – intermediate host, live on pastures, at the basis of plants, favoring the infection of lambs and sheep [22]. The acute monieziosis triggered in young goats in autumn towards the ending of the pasturing season was caused by the infection with both species of the *Moniezia* genus, *M. expansa*, and *M. benedeni*, respectively. Surprisingly, the *M. benedeni* species was developed in the small intestine in young goats in the context in which this species is known to infect in the small intestine in cattle [13] and recent, in European bison [23]. The morphological characteristics of the species of the genus *Moniezia*, respectively *M. expansa* (species common in sheep, goats, less often in calves, buffaloes) and *M. benedeni* (common especially in calves and less often in sheep, goats) are presented as common [5,24,25]. Morphological differences are based on body size (length×width), shape and size of the scolex, shape, and size of proglottids, arrangement of the interproglottid glands. In *M. expansa*, the body length between 2.0–6.0 m described by us is in agreement with Kaufman [25], who mentions lengths of up to 6.0 m and does not agree with Mehlhorn [14] which mentions the length of 10.0 m. In *M. benedeni*, the body length between 1.0–4.0 m, described in the paper, is in agreement with Mehlhorn [14], which mentions the length of 4.0 m and is not in agreement with Foreyt [13], which mentions the length of up to 100 cm. The body width in *M. expansa* was 15–25 mm, and in *M. benedeni*, the body width was between 10–25 mm, according to Kaufman [25] and Mehlhorn [14]. The scolex is unarmed in both species, but in *M. expansa* it is globular (0.7 mm), provided with four suckers, and *M. benedeni* has the cubic scolex, with a larger diameter (1.60 mm) and large suckers, characteristics according to Mehlhorn [14], Urquhart [24], Bowmann [5]. The neck is unsegmented, long in *M. expansa* and short in *M. benedeni*, according to Mehlhorn [14] and Bowmann [5]. Mature proglottids are wider than long. The dimensions of the mature proglottids were 15–25×3.0 mm in *M. expansa* and 10–25×3.0 mm in *M. benedeni*, with double genitals, bilateral pores, and numerous testicles scattered between the two ovaries, according to the literature [5,24]. The main morphological differences between these two species were made based on the interproglottid glands: in *M. expansa*,

they are follicular, distributed linearly, in the posterior part of the proglottids, across the entire width, while in *M. benedeni*, the glands are compact, grouped in the middle of the proglottids, on the posterior edge. Our data are in agreement with the literature [5,13,14], but this finding will be verified with the use of molecular techniques. The prevalence of tapeworms, in slaughtered animals, was 100%, according to studies by Futagbi et al. [10]. The tapeworms caused several changes of variable intensity, according to the number of grown specimens, in the intestine. The modifications of the intestinal mucosa were characterized, mainly, by catarrhal inflammation. The intestinal mucosa thinned in certain areas and was infiltrated and thickened in other areas. Petechiae, small ulcerations can be noticed, similar to those described in lambs [26]. In this study, the intestinal aggression caused by the high number of tapeworms produced the occlusion and obstruction of the intestinal lumen. Furthermore, the intimate contact between the tapeworms and the intestinal mucosa irritates the mucosa through their movements in the intestine, the toxins eliminated in the intestinal content, disturbed the digestion and the absorption processes of the nutrients, causing maldigestion and malabsorption, the acceleration of the intestinal peristalsis, diarrheic emissions, tenesmus, abdominal pains, bloating, prostration, a general body deterioration. These observed manifestations are described by other authors, as well [5]. Tapeworms influence negatively the general development of infected animals by passively taking the important nutrients, necessary for their developments (proteins, lipids, glucides, mineral salts, vitamins, especially, complex B) [11]. In this way, tapeworms contribute significantly to reducing weight gain of the occurrence of rickets in kids and the faulty development of the skeleton. Moreover, tapeworms affect the development of muscular mass and body weight, thus influencing the quality and the quantity of the obtained products [16]. Also, parasitizing small ruminants with gastrointestinal helminths affects the quality of the wool yarn, by a non-uniform development, the appearance of strangulations or nodosities on its whole length [27]. Injury of the intestinal mucosa, starting with epithelial desquamation of the villi, progressive atrophy with halving of the villi until the total atrophy of the mucosa is characteristic of tapeworms, facilitated by body length and cuticle morphology adapted to the small intestine [28]. The

microtriches from the cuticle of tapeworms blend perfectly with the intestinal microvilli, achieving intimate contact between the parasite and the mucosa. This interpenetration takes place during the antiperistaltic movements of the infected intestine, ensuring the fixation of the tapeworm on the mucosa on the whole surface of the body, not just through scolex [5]. The immune effort of the intestinal mucosa was maximal reflected by the inflammatory infiltrate predominantly eosinocytic from lamina propria and by the lymphohistiocytic proliferation in the Payer's patches from the submucosa of the ileum. The clinical infections with tapeworms from the *Moniezia* genus in kids and young goats are especially important for goat breeders, leading to economic losses, reduced productivity, sources of continuous pollution of pasturing areas and losses through mortality, aspects described in the specialty literature, as well [18,21]. Observing the *M. benedeni* species in young goats increases the spectrum of action for the species from Anoplocephalidae family, *Moniezia* genus, by enriching the etiology of the digestive syndrome in goats, with autumnal manifestations. The unusual infection of goats with both species of *Moniezia* shows the common source of intermediate hosts. The mites for *M. expansa* grow on pastures in April-July and for *M. benedeni*, in August-October, ensuring the development of the cysticercoid larvae, the infecting of young animals and perpetuating the species of tapeworms in ruminants [22].

In conclusions, mixed infection of young goats with *M. expansa* and *M. benedeni* species is reported for the first time in Romania. The prevalence of *M. expansa* was 56.10%, and the prevalence of *M. benedeni* species was 43.90%. The lesions were characterized by intestinal occlusion and obstruction, severe catarrhal jejunitis, total mucosal atrophy, eosinophilia in the lamina propria, and inflammatory hyperplasia of the Payer's patches. Further investigations of a large number of goat flocks are indicated to detect the prevalence of such cestodes in Romania and to assess its economic impact. Molecular biology studies will complete future investigations.

References

- [1] Rahmann G., Seip H. 2007. Alternative management strategies to prevent and control endo-parasite diseases in sheep and goat farming systems-a review of the recent scientific knowledge. *Landbauforschung*

- 2: 75-88.
- [2] Villarroel A. 2013. Internal Parasites. In: *Sheep and Goats*. Oregon State University Extension Service, EM 9055.
- [3] Iacob O., El-Deeb W., Solcan Gh., Pavel G. 2016. Parasite burdens in Carpathian goats in Romania and associated haematological and biochemical parameters. In: *Sustainable goat breeding and goat farming in Central and Eastern European countries*. (Ed. S. Kukovics), FAO Book, Rome-Italy.
- [4] Love S., Greentree K. 2017. Managing worms in goats. In: *State of New South Wales. Primefact 1564*. 1st ed. www.dpi.nsw.gov.au/factsheets
- [5] Bowman D.D. 2014. *Georgis Parasitology for Veterinarians*. (Eds. Saunders, an imprint of Elsevier Inc.). 10th ed. St. Louis, Missouri, USA.
- [6] Iacob O.C. 2016. Parazitologia și clinica bolilor parazitare la animale – Helminthoză a 3-a ediție revizuită [Parasitology and parasitic disease in animals – Helminthology, 3-rd rev. ed.], Publishing “Ion Ionescu de la Brad” Ed. Iași, Romania (In Romanian with summary in English).
- [7] Uke P.S., Rafiqi I.S., Kumar S., Durge S. 2017. Management of concurrent infection of tapeworm and amphistomosis outbreak in a goat farm. *International Journal of Environmental Science and Technology* 6: 2064-2067.
- [8] Kassaye A., Gebreegziabher E. 2014. Small intestinal helminth parasites in slaughtered sheep and goats in Hawassa, Southern Ethiopia. *African Journal of Basic and Applied Sciences* 6: 25-29. doi:10.5829/idosi.ajbas.2014.6.2.85153
- [9] Sissay M.M., Uggla A., Waller J.P. 2008. Prevalence and seasonal incidence of larval and adult cestode infections of sheep and goats in eastern Ethiopia. *Tropical Animal Health and Production* 40: 387-394. doi:10.1007/s11250-007-9096-z
- [10] Futagbi G., Abankwa J.K., Agbale P.S., Aboagye I.F. 2015. Assessment of helminth infections in goats slaughtered in an abattoir in a suburb of Accra, Ghana. *West African Journal of Applied Ecology* 23: 35-42.
- [11] Christensen K. 2005. Scientific animation and illustration: the secret lives of goat parasites. <http://www.goatbiology.com/animations/moniezia.html>
- [12] Macon D. 2018. Managing internal parasites in small ruminants. UCCE Cooperative Extension. California sheep and goats grazing school. www.wormx.info-American Consortium for Small Ruminant Parasite Control
- [13] Foreyt J.W. 2001. *Veterinary Parasitology. Reference manual*. 5th ed. Blackwell Publishing, Iowa State University.
- [14] Mehlhorn H. (Ed). 2016. *Encyclopedia of Parasitology*. Springer-Verlag Berlin, Heidelberg, New York.
- [15] Waal, T. 2003. Goat parasites. Survey of endoparasites in goats in Ireland. UCD Dublin, School of Veterinary Medicine. tagxedo.com.
- [16] Kumar N., Rao S.K.T., Varghese A., Rathor S.V. 2013. Internal parasite management in grazing livestock. *Journal of Parasitic Diseases* 37: 151-157. doi:10.1007/s12639-012-0215-z
- [17] Rizac I.R., Paraschiv A.I., Stoian C.A., Soare T., Constantin T.N., Grecu, M., Nadolu D., Militaru M. 2015. Systemic lesions of multiple etiology in French-Alpine kids. *Revista Română de Medicină Veterinară* 25: 27-32.
- [18] Juszczak M., Sadowska N., Udala J. 2019. Parasite of the digestive tract of sheep and goats from organic farms in Western Pomerania, Poland. *Annals of Parasitology* 65: 245-250. doi:10.17420/ap6503.206
- [19] Hepworth K., Neary M., Hutchens, T. 2006. Managing internal parasitism in sheep and goats. AS-573-W. Purdue Extension Education Store Knowledge to Go. www.ces.purdue.edu/new
- [20] Schoenian S., Escobar N.E. 2018. Best management practices for internal parasite control in small ruminants. In: *Proceedings of the 3rd National Goat Conference*. (Eds. O. Bolden-Tiller, U. Karky). Tuskegee University, Tuskegee, AL 36088.
- [21] Bannerman-Williams E. 2013. Gastrointestinal parasites in ruminants at selected abattoirs in the Greater Accra Region, Ghana. PhD Thesis, University of Ghana <http://ugspace.ug.edu.gh>
- [22] Iacob O., Vasiliu N. 2000. *Zygoribatula connexa* (Berlese, 1904), an intermediate host in cestodosis transmission to sheep. *Lucrări Științifice de Medicină Veterinară, USAMVB Timișoara, Romania*, 33: 219-223.
- [23] Demiaszkiewicz W.A., Pyziel M.A., Jacek Lachowicz J., Filip-Hutsch K. 2020. Occurrence of tapeworms *Moniezia benedeni* (Moniez, 1879), in European bison *Bison bonasus* L. in Bialowieza Primeval Forest. *Annals of Parasitology* 66: 107-109. doi:10.17420/ap6601.244
- [24] Urquhart G.M., Armour J., Duncan J.L., Dunn A.M., Jennings F.W. 1987. *Veterinary Parasitology*. Longman Scientific and Technical. Essex, England, New York.
- [25] Kaufmann J. 1996. *Parasitic infections of domestic animals: a diagnostic manual*. Springer Basel AG, Boston, Berlin.
- [26] Iacob O.C. 2000. Patogenia, micro- și macroecologia faunei helmintice din intestinul subțire la ovine [The pathogeny, micro and macroecology of the helminth fauna within the small intestine in sheep]. PhD thesis, USAMV Bucharest, Romania.
- [27] Iacob O., Pascal C. 2002. Infestarea experimentală a mieilor cu L₃ de nematode intestinale: consecințe asupra calității firului de lână [Experimental infection of lambs by L₃ nematode intestinal: consequences on

- the quality of wool yarn]. *Scientia Parasitologica* 3: 137-141 (in Romanian with summary in English).
- [28] Iacob O., Coțofan O. 2007. Histological aspects regarding reactivity of intestinal mucosa in newborn lambs and the risk of apparition of parasitic enteritis.

Scientia Parasitologica 8: 52-59.

Received 14 April 2020
Accepted 23 August 2020