



Diagnostic approach to a paediatric patient with Wiedemann-Steiner syndrome with *de novo* missense variant in the *KMT2A* gene – a case report

Gabriela Ręka^{1,A-D,F}✉, Katarzyna Wojciechowska^{1,A-C,E}, Monika Lejman^{1,B-C,E-F}

¹ Laboratory of Genetic Diagnostics of the Second Department of Paediatrics, Medical University, Lublin, Poland
A – Research concept and design, B – Collection and/or assembly of data, C – Data analysis and interpretation, D – Writing the article, E – Critical revision of the article, F – Final approval of the article

Ręka G, Wojciechowska K, Lejman M. Diagnostic approach to a paediatric patient with Wiedemann-Steiner syndrome with *de novo* missense variant in the *KMT2A* gene – a case report. *Ann Agric Environ Med.* 2023; 30(3): 577–579. doi: 10.26444/aaem/163063

Abstract

Introduction. Wiedemann-Steiner syndrome is caused by mutations in the *KMT2A* gene (11q23.3). It might be inherited autosomal dominant or appear *de novo*. Features described in the syndrome include developmental delay, short stature, hypotonia, hypertrichosis, facial dysmorphic features, and intellectual disability.

Case Report. A boy aged 5.5 months was admitted to the Genetics Outpatient Clinic due to delayed psychomotor development. Microsomnia, hypotonia, joint laxity, and facial dysmorphic features were noticed. No genomic imbalance was found in microarray, based on comparative genomic hybridization. The c.3528G>T variant of the *KMT2A* gene was identified on chromosome 11 of the missense type in next-generation sequencing. The reasons for phenotypic features were confirmed in genetic research.

Conclusions. Wiedemann-Steiner syndrome has a variable clinical phenotype. There is a strong need to pay attention to phenotypic features that may suggest the syndrome and refer patients for appropriate genetic diagnostics.

Key words

Wiedemann-Steiner syndrome, *KMT2A* gene, whole-exome sequencing

INTRODUCTION

Wiedemann-Steiner syndrome (WDSTS, OMIM #605130) is a rare disease with a frequency of 1:25,000–40,000 births [1, 2]. The syndrome was described for the first time in 1989 by Hans-Rudolf Wiedemann et al. [3] and first stated as a syndrome by Carlos E. Steiner and Antonia P. Marques [4]. Its genetic basis was found in 2012 by Wendy D. Jones et al. [5]. It is caused by germinal heterozygous mutations in the *KMT2A* gene encoding lysine-specific methyltransferase 2A [6, 7]. The gene is also known as *MLL1* and is located on the long arm of chromosome 11 (11q23.3) [7, 8, 9]. Genetic variants in the *KMT2A* gene may be inherited autosomal dominant or appear *de novo* [6, 9, 10]. Patients are diagnosed usually in the neonatal, infant, or childhood period [2].

Wiedemann-Steiner syndrome is characterized by a variable phenotype: developmental delay, short stature, hypotonia, hypertrichosis of the elbows or back, facial dysmorphic features, small hands and feet, abnormalities in the structure of the heart (PDA), genitourinary system, skeleton, and teeth, mild to moderate intellectual disability, seizures, autistic features, attention deficit, and hyperactivity disorder [1, 3, 6, 9, 11, 12, 13]. Chiari malformation, tethered cord, dysmotility of the gut, growth hormone deficiency, and hypogammaglobulinaemia have been reported less frequently [2]. Among facial dysmorphic features, the following characteristics are enumerated in the literature:

flat and round face, low-set ears, short nose, broad nasal bridge, thick or arched eyebrows, telecanthus, widely-spaced eyes, vertically narrow palpebral fissures, long and dense eyelashes, long philtrum, and high-arched palate [1, 5, 11, 13].

Wiedemann-Steiner syndrome sometimes is misdiagnosed with other disorders, such as autism spectrum disorders, Rubinstein-Taybi syndrome, Kabuki syndrome, Coffin-Siris syndrome, or Cornelia de Lange syndrome [2, 5, 6]. Specific treatment for Wiedemann-Steiner syndrome is not accessible. In most cases of children with the syndrome, there is hypotonia and developmental delay; therefore, early inclusion of physical therapy services becomes a significant aspect of management [14]. In some patients with growth hormone deficiency and short stature, growth hormone therapy is indicated [2, 15]. Life expectancy is not shortened in most cases [2]. The study aims to present a medical history and diagnostic process of a patient with Wiedemann-Steiner syndrome.

CASE REPORT

A patient was admitted to the Genetics Outpatient Clinic the first time at the age of 5.5 months due to delayed psychomotor development. The boy was born from the first pregnancy, first delivery, at 37 weeks of pregnancy by caesarean section due to imminent foetal asphyxia. From the 31st week of pregnancy, weaker weight and length gain were noted. Intrauterine infection was diagnosed in the perinatal period. Apgar score after birth was 7 and 9 points. Body weight was 2,740g, body length 50cm, head circumference 33cm, and

✉ Address for correspondence: Gabriela Ręka, Laboratory of Genetic Diagnostics of the Second Department of Paediatrics, Medical University, Lublin, Poland
E-mail: gabrysia.reka@gmail.com

Received: 01.02.2023; accepted: 04.04.2023; first published: 08.05.2023

chest circumference 32 cm. The patient's parents were non-consanguineous Caucasians (Fig.1). For 5 years his mother had difficulties with becoming pregnant. In her medical history, she also presented with removed ovarian cyst 2 years before the birth of the boy, and hypothyroidism treated with levothyroxine from the 36th week of pregnancy. Six years before the birth of the boy, his father had been treated with chemotherapy for testicular cancer. Both parents were 38-years-old at the birth of the boy who had no siblings.

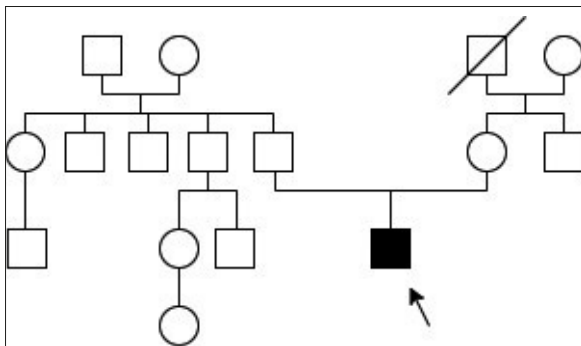


Figure 1. Genetic lineage of the proband's family

Delayed psychomotor development was seen in different areas: lifting the head at the age of 5.5 months, sitting up at the age of 18 months, speaking at the age of 2, and walking at the age of 2 years and 7 months. Body length, height, and weight were below the 3rd percentile on growth charts during 2-year observation in the Outpatient Clinic. Microsomia, decreased muscle tone, joint laxity, flat feet, flat face, low-set ears, wide, slightly concave nasal bridge, smooth philtrum, and high-arched palate were described in the patient (Fig. 2–4). The boy also suffered from a food allergy, hypothyroidism, patent foramen ovale (PFO), and patent ductus arteriosus (PDA). He had problems with gross motor and fine motor skills and expressing emotions.

No genomic imbalance was found in microarray-based comparative genomic hybridization (aCGH). Next-generation sequencing (NGS) and whole-exome sequencing (WES) was commissioned, augmented by an analysis of

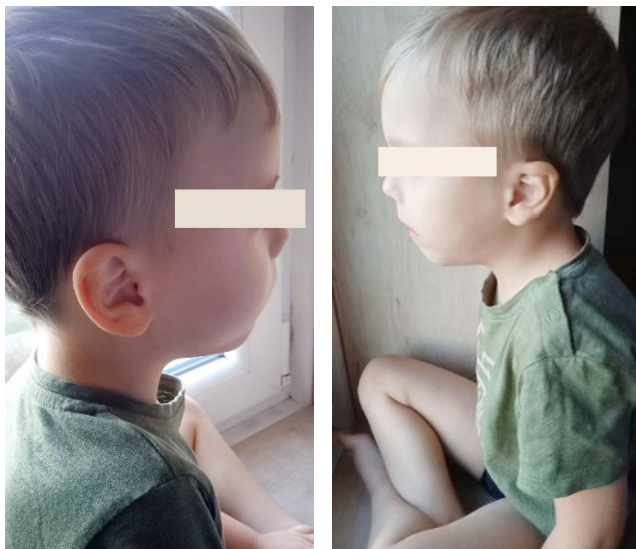

Figure 2. Face of the patient with Wiedemann-Steiner syndrome. Note characteristic facial features: flat face, low-set ears, wide, slightly concave nasal bridge, smooth philtrum

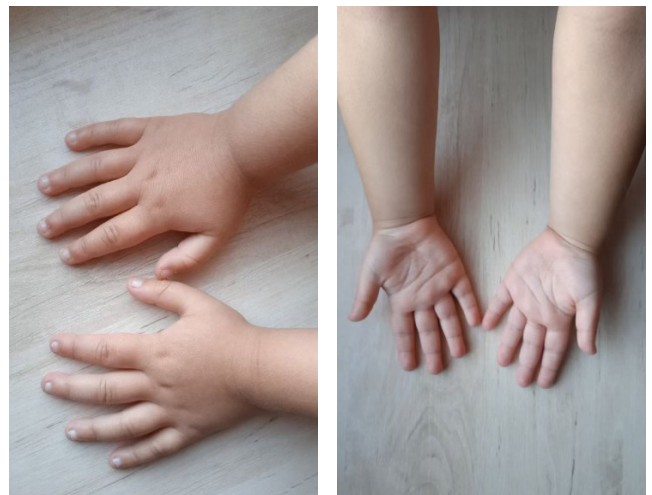

Figure 3. Arms of the patient with Wiedemann-Steiner syndrome. Note characteristic features: brachydactyly, puffy hands

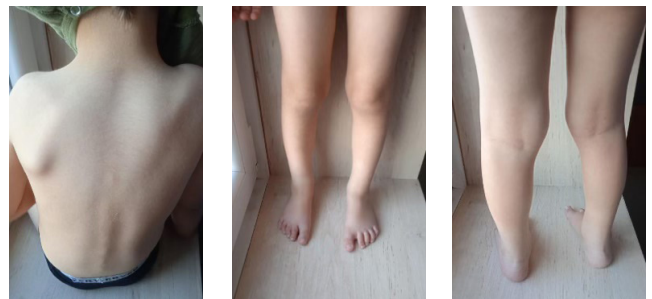

Figure 4. Back and feet of the patient with Wiedemann-Steiner syndrome. Note characteristic features: hypertrichosis of the back, small and flat feet

the complete mitochondrial genome and a panel of known pathogenic variants beyond the exome. The Twist Human Core Exome 2.0, Comp Spike-in, and Twist mtDNA Panel (Twist Bioscience) kit were used to perform the study. Analysis of DNA copy number variation (CNV) showed no changes that could explain the proband's symptoms. In WES, a change in the *KMT2A* gene at the p.(Lys1176Asn) protein level at the cDNA level c.3528G>T of a missense type was diagnosed (NM_005933.4:c[3528G>T];[3528=]). The variant in the proband's parents was excluded (*de novo* lesion).

DISCUSSION

Enzyme lysine-specific methyltransferase 2A modifies the expression of other genes and catalyzes mono-, di-, and trimethylation of lysine 4 of histone H3 (H3K4). It regulates chromatin modifications associated with epigenetic transcriptional activation of various genes, including genes involved in embryonic development, neurodevelopment, and haematopoiesis [6, 15, 16, 17, 18]. The highest expression of *KMT2A* occurs in the ovary, lymph node, brain, and skin tissue. However, the gene is widely expressed in most human tissues [19].

Pathogenic germline changes in the *KMT2A* gene, including frameshift (41%) and stop mutations (29%), followed by missense variants (18%), are the cause of Wiedemann-Steiner syndrome [16]. According to Shepperd et al., most variants were frameshift (37.8%) and nonsense (29.3%). Missense variants were noted in 20.7% of the variants and were followed

by splice site variants found in 11% of patients. According to the study, most Wiedemann-Steiner cases (55.5%) appeared *de novo* [13]. The c.3528G>T variant of the *KMT2A* gene, as in the patient in the case study, has not yet been described in the literature and databases (dbSNP (<https://www.ncbi.nlm.nih.gov/snp/>), accessed 20.12.2022 ClinVar (<https://www.ncbi.nlm.nih.gov/clinvar/>), accessed 20.12.2022, and gnomAD (<http://gnomad.broadinstitute.org/>), accessed 20.12.2022). The missense mutation in the current patient's genotype caused an amino acid change in the lysine-specific methyltransferase 2A sequence. Both dominant negative mechanisms and loss of function have been hypothesized to cause Wiedemann-Steiner syndrome by this type of mutation. However, the mechanism associated with missense mutations of *KMT2A* still remains ambiguous [17].

In the literature, there is a large variety of variants that cause the syndrome. Shepperd et al. reported that 69 of the 82 variants observed in the analysis (84%) were not previously described in the literature [13]. Similar conclusions were noted by Baer et al. In a study of 33 French Wiedemann-Steiner cases, 29 novel mutations were found [20].

Causes of *de novo* mutations include exposure of gametes to mutagens. In the study by Kaplanis et al. paternal exposure to chemotherapy before conception was probably a key driver of hypermutation in 5 of the 12 studied families [21]. However, it cannot be stated with certainty that in the current case the chemotherapeutic agents used in the father for testicular cancer caused a *de novo* mutation of the *KMT2A* gene, which was passed on to the son.

Sun et al. suggest that there might be a difference in symptoms of the syndrome depending on ethnicity. For example, absent palmar proximal transverse creases have only been observed in 2 Chinese boys described with novel nonsense *KMT2A* mutations [22]. White individuals were significantly more likely to have a bifid uvula and a thin upper vermilion border of the lip than black indigenous people [13].

Moreover, *KMT2A* somatic mutations have been described in several tumors, mainly blood neoplasms like leukemias and lymphomas [16]. There is no data in the literature that patients with Wiedemann-Steiner syndrome might have an increased risk of neoplasms caused by somatic *KMT2A* mutations. Shepperd et al. performed a retrospective, observational, multicentre analysis of 104 patients with Wiedemann-Steiner syndrome from 5 continents and various racial and ethnic origins. In the cohort including 23 adults with the oldest in their forties, no cancers were reported [13]. Currently, no specific measures for cancer surveillance can be recommended or negated for patients with Wiedemann-Steiner syndrome.

CONCLUSIONS

The reasons for phenotypic features present in the patient were confirmed in genetic studies. According to the literature, Wiedemann-Steiner syndrome has a variable clinical phenotype with possible *de novo* occurrence, as in the presented case. There is a need to identify new genetic variants of *KMT2A* mutations that cause the syndrome, and confirm whether phenotypes of different patients with Wiedemann-Steiner syndrome vary between each patient depending on the variant. More data are needed to confirm or deny an increased neoplasms risk in patients with Wiedemann-Steiner syndrome. Even though Wiedemann-

Steiner syndrome is a rare disease with various expressions of symptoms, it is necessary to pay attention to phenotypic features that may suggest the syndrome and refer patients for appropriate genetic diagnostics. Wiedemann-Steiner syndrome probably remains under-diagnosed.

REFERENCES

1. Online Mendelian Inheritance in Man, OMIM®. Johns Hopkins University, Baltimore, MD. MIM Number: 605130; 8 April 2020. World Wide Web URL: <https://omim.org/> (access: 2022.12.20)
2. Orphanet: an online database of rare diseases and orphan drugs. Copyright, INSERM 1997. Available at https://www.orpha.net/consor/cgi-bin/Disease_Search.php?lng=EN&data_id=21621 (access: 2022.12.20)
3. Wiedemann HR, Kunze J, Grosse FR, et al. A syndrome of abnormal facies, short stature, and psychomotor retardation. In: Atlas of Clinical Syndromes: A Visual Aid to Diagnosis for Clinicians and Practicing Physicians, 2nd ed. London: Wolfe Publishing Ltd.; 1989. p. 198–199.
4. Steiner CE, Marques AP. Growth deficiency, mental retardation and unusual facies. Clin Dysmorphol. 2000;9(2):155–6. <https://doi.org/10.1097/00019605-200009020-00021>
5. Jones WD, Dafou D, McEntagart M, et al. De novo mutations in MLL cause Wiedemann-Steiner syndrome. Am J Hum Genet. 2012;91(2):358–64. <https://doi.org/10.1016/j.ajhg.2012.06.008>
6. Miyake N, Tsurusaki Y, Koshimizu E, et al. Delineation of clinical features in Wiedemann-Steiner syndrome caused by *KMT2A* mutations. Clin Genet. 2016;89(1):115–9. <https://doi.org/10.1111/cge.12586>
7. Di Fede E, Massa V, Augello B, et al. Expanding the phenotype associated to *KMT2A* variants: overlapping clinical signs between Wiedemann-Steiner and Rubinstein-Taybi syndromes. Eur J Hum Genet. 2021;29(1):88–98. <https://doi.org/10.1038/s41431-020-0679-8>
8. Jinxu L, Shuimei L, Ming X, et al. Wiedemann-Steiner syndrome with a *de novo* mutation in *KMT2A*: A case report. Medicine (Baltimore). 2020;99(16):e19813. <https://doi.org/10.1097/md.00000000000019813>
9. Chan AJS, Cytrynbaum C, Hoang N, et al. Expanding the neurodevelopmental phenotypes of individuals with *de novo* *KMT2A* variants. NPJ Genom Med. 2019;4:9. <https://doi.org/10.1038/s41525-019-0083-x>
10. Hirst L, Evans R. Wiedemann-Steiner syndrome: A case report. Clin Case Rep. 2021;9(3):1158–1162. <https://doi.org/10.1002/ccr3.3704>
11. Aggarwal A, Rodriguez-Buritica DF, Northrup H. Wiedemann-Steiner syndrome: Novel pathogenic variant and review of literature. Eur J Med Genet. 2017;60(6):285–288. <https://doi.org/10.1016/j.ejmg.2017.03.006>
12. Grangeia A, Leão M, Moura CP. Wiedemann-Steiner syndrome in two patients from Portugal. Am J Med Genet A. 2020;182(1):25–28. <https://doi.org/10.1002/ajmg.a.61407>
13. Sheppard SE, Campbell IM, Harr MH, et al. Expanding the genotypic and phenotypic spectrum in a diverse cohort of 104 individuals with Wiedemann-Steiner syndrome. Am J Med Genet A. 2021;185(6):1649–1665. <https://doi.org/10.1002/ajmg.a.62124>
14. Mendoza C. Physical Therapy management of Wiedemann-Steiner syndrome from birth to 3 years. Pediatr Phys Ther. 2020;32(3):E64–E69. <https://doi.org/10.1097/PEP.0000000000000714>
15. Stoyle G, Banka S, Langley C, et al. Growth hormone deficiency as a cause for short stature in Wiedemann-Steiner syndrome. Endocrinol Diabetes Metab Case Rep. 2018;2018:18–0085. <https://doi.org/10.1530/EDM-18-0085>
16. Castiglioni S, Di Fede E, Bernardelli C, et al. *KMT2A*: Umbrella gene for multiple diseases. Genes (Basel). 2022;13(3):514. <https://doi.org/10.3390/genes13030514>
17. Fallah MS, Szarics D, Robson CM, et al. Impaired regulation of histone methylation and acetylation underlies specific neurodevelopmental disorders. Front Genet. 2021;11:613098. <https://doi.org/10.3389/fgene.2020.613098>
18. Ramirez-Montañó D, Pachajoa H. Wiedemann-Steiner syndrome with a novel pathogenic variant in *KMT2A*: a case report. Colomb Med. 2019;50(1):40–45. <https://doi.org/10.25100/cm.v50i1.3555>
19. Yu H, Zhang G, Yu S, Wu W. Wiedemann-Steiner syndrome: case report and review of literature. Children (Basel). 2022;9(10):1545. <https://doi.org/10.3390/children9101545>
20. Baer S, Afenjar A, Smol T, et al. Wiedemann-Steiner syndrome as a major cause of syndromic intellectual disability: A study of 33 French cases. Clin Genet. 2018;94(1):141–152. <https://doi.org/10.1111/cge.13254>
21. Kaplanis J, Ide B, Sanghvi R, et al. Genetic and chemotherapeutic influences on germline hypermutation. Nature. 2022;605(7910):503–508. <https://doi.org/10.1038/s41586-022-04712-2>
22. Sun Y, Hu G, Liu H, et al. Further delineation of the phenotype of truncating *KMT2A* mutations: The extended Wiedemann-Steiner syndrome. Am J Med Genet A. 2017;173(2):510–514. <https://doi.org/10.1002/ajmg.a.38025>