

Diagnosis and differentiation of infarction of the gastrocolic omentum and epiploic appendagitis – case description

Agnieszka Grudzińska-Raczek¹, Ewa Dziurzyńska-Białek¹, Anna Solińska¹, Wiesław Guz¹, Witold Krupski²

¹ Department of Radiology and Imaging Diagnostics Provincial Hospital No 2 by the name of St. Jadwiga the Queen in Rzeszów, Poland

² 2nd Department of Radiology, Medical University in Lublin, Poland

Grudzińska-Raczek A, Dziurzyńska-Białek E, Solińska A, Guz W, Krupski W. Diagnosis and differentiation of infarction of the gastrocolic omentum and epiploic appendagitis – case description. J Pre-Clin Clin Res. 2012; 6(2): 131-133.

Abstract

The article presents the history of the disease in a 43-year man who reported to hospital because of the sudden occurrence of strong, diffuse, abdominal pain. Diagnostic tests performed in the emergency mode, including abdominal cavity US, showed no pathology. Subsequent US performed 12 hours later showed the presence of a pelvic minor tumour of adipose texture. The presence of this pathology was then confirmed by abdominal CT. Four days after admission to hospital, the patient was operated on, revealing in the HP study a partial necrosis of the gastrocolic omentum against the epiploic appendix pedicle with adipose tissue fibrosis. There were no complications in the patient in the postoperative period, and after 13 days he was discharged in good general condition. Retrospective analysis of this case demonstrates the need for considering this pathology in the differential diagnosis of acute abdomen. This case deserves attention because of the rarity of this pathology in the literature, and the interesting documentation in two different imaging techniques (US and CT).

Key words

infarction of the gastrocolic omentum, epiploic appendagitis, acute abdomen

INTRODUCTION

Although an infarction of the gastrocolic omentum was first described over 100 years ago (in 1899) by Eithel [1, 2], even today it still causes a lot of problems in the diagnosis of acute abdomen, and not too often recognized. The much more common inflammation of the appendix, gallbladder, and colon diverticuli should be considered in the differential diagnosis, and often only laparotomy explains the background of the reported symptoms [1, 2, 3, 4, 5, 6]. Among these diseases, the most diagnostic trouble is caused by omental infarction or omentovolvulus. In US examination, changes of this type provide a picture of a hyperechoic mass located in the right mesogastric layers [7]. Computed tomography (CT) is very useful in the preoperative diagnosis [2, 4, 5, 8].

Gastrocolic omentum (lat. omentum majus) is a double-plate peritoneum, hanging from the greater curvature of stomach, creating a 'coat' covering the front of the intestinal loops. It often reaches up to the pubic symphysis and the inguinal ligament. Parts of the colon and intestine can be seen along the free edge of the omentum. If the gastrocolic omentum does not contain a more excessive amount of adipose texture, then the translucent elements of the transverse colon and below it the loops of the small intestine below the stomach can be seen [9].

Epiploic appendices (epiploic appendix) are small pouches of the peritoneum of 3 cm size filled with an excessive amount

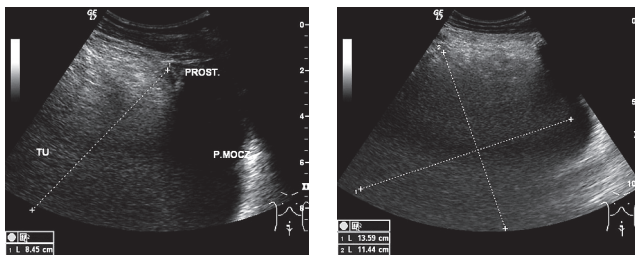
of adipose tissue. They are not present individually and lie in a double-line system on the front surface of the colon (only on the transverse colon there is one line). They most often occur in the sigmoid colon and are supplied with blood by the marginal artery branches. They are characterized by a narrow pedicle and high mobility, which can be the cause of their rotation, and thus ischemia, infarction, necrosis and inflammation [9, 10].

Case description. 43-year-old man presented to the emergency department of Provincial Hospital No 2 in the name of St. Jadwiga the Queen in Rzeszow at night (around 03:00-04:00) due to sudden, severe, and diffuse pain in the mesogastrium. The clinical characteristics were gastrointestinal obstruction. In an interview with the state of the right-sided incarcerated inguinal hernia.

In abdominal US performed immediately, no pathology was revealed, but the area was intensively obscured by reflections from the intestines, and urinary bladder was well filled with no compression or modelling from the outside. X-ray of the abdomen and the chest also showed no pathology. In laboratory studies, high CRP – 171.4 mg/l, increased leukocytes level 14.37 thousand / dl were observed as abnormalities. After application of conservative treatment, a reduction of pain was obtained. The control abdominal US performed approximately 12 hours after the first study revealed the presence of abnormal hyperechoic structures of size 14 × 12 cm, modelling and compressing the bladder. No pathological vascularisation of the changes and infiltration of the surrounding structures was revealed. However, with ultrasound, features of small intestine obstruction was stated and suggested the necessity for computed tomography (CT).

Address for correspondence: Agnieszka Grudzińska-Raczek, Department of Radiology and Imaging Diagnostics Regional Hospital No 2 by the name of St. Jadwiga the Queen in Rzeszow, 60 Lwowska, 35-301 Rzeszow, Poland
E-mail: awraczek@op.pl

Received: 10 October 2012; accepted: 12 December 2012



Figures 1-2. Abdominal US in peroneal and oblique cross-section: visible hyperchoic focal change exerting pressure on the bladder from the top and from the front

CT scan performed urgently on admission revealed the presence of a pathological tissue mass of size $10 \times 11 \times 13$ cm with a density corresponding to adipose tissue (-100 HU). Visible fibrous bands and compartments filled the pelvis, exerted pressure on the bladder, had moved the sigmoid colon to the left and exerted pressure on it.

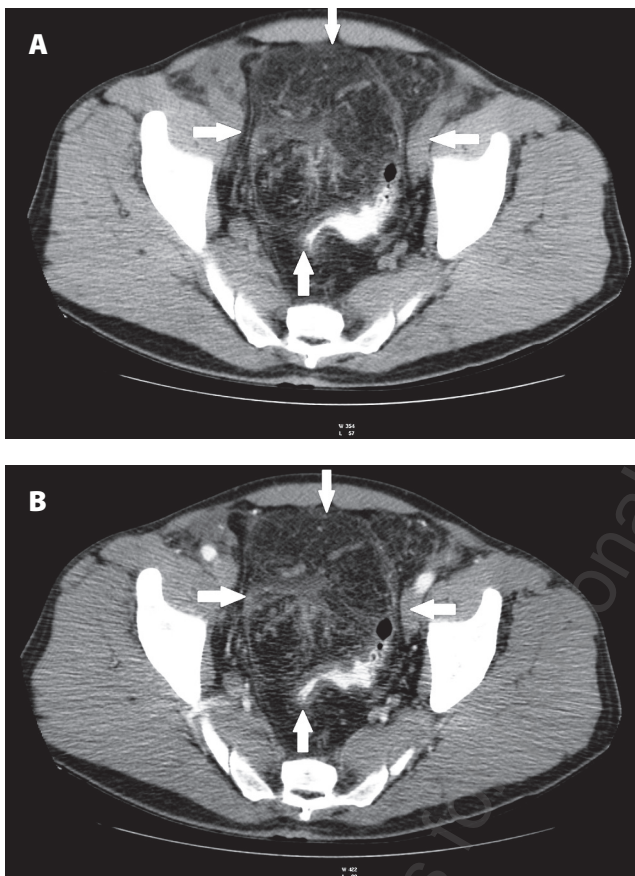


Figure 3. Pelvis minor (A): CT – unenhanced axial scan. (B): CT + CM – arterial phase, axial scan. Pathological mass of adipose tissue predominantly moving sigmoid colon to the left and exerting pressure on it

The US and CT results were the reason for the decision to perform surgical procedure, which was performed on the 4th day of hospitalization. Intraoperative found the site shown of the imaging tumor, and partial necrosis of omentum on the background of epiploic appendix pedicle. Resection of a portion of the greater omentum and appendix was performed. Postoperative course was uneventful during the 13 days of the patient's hospitalization, and was discharged home in a general and local good condition.

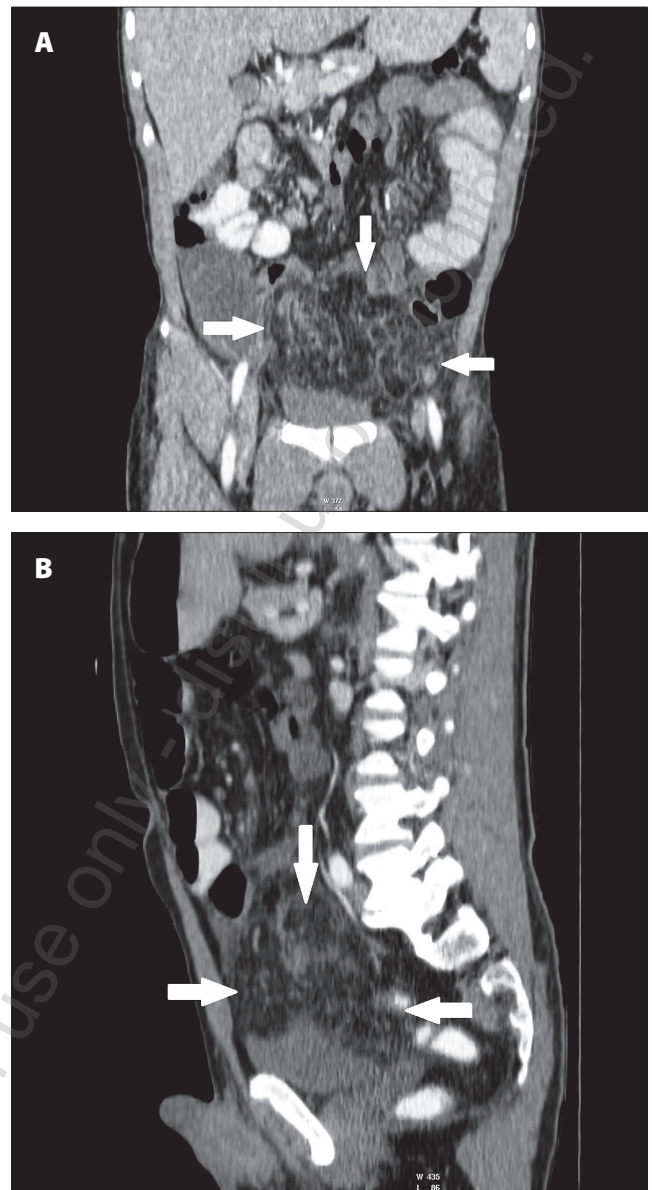


Figure 4 (A) (B). CT + CM in arterial phase. MPR reconstructions. Pathological tissue mass with predominance of adipose tissue in the abdomen exerting pressure on the top and front of the bladder

The histopathological material submitted after the operation was described as an inflamed epiploic appendix as a result of turning of its pedicle, with partial adipose tissue fibrosis.

DISCUSSION

Omentum infarction, the cause of which is not known, is called 'idiopathic', and 'secondary' when the cause is known and results from e.g. coagulopathy, vasculitis, omentovolvulus, cysts, tumours and adhesions. Idiopathic omental infarction is promoted by obesity (especially in children), local abdominal trauma, constipation caused by heavy ingestion food, strenuous, strong cough, sudden movement, consumption of constipation drugs, and increased intestinal peristalsis. [2, 6]. This infarction is most common in the right half of the abdominal cavity [2, 6].

Sometimes, epiploic appendagitis and infarction of the gastrocolic omentum are called (intra-abdominal fat focal infarction (IFFI) because, usually based on the clinical data and imaging studies, these pathologies cannot be distinguished. This results from a similar natural history and course of the two diseases, the prognosis and the same conservative therapeutic measures for confidence in the diagnosis of IFFI (analgesics and clinical observation) [6, 11, 12, 13]. Such a procedure at accurate IFFI diagnosis results in a rapid recovery, usually after two weeks [13]. Some authors describe the need sometimes for laparoscopy in the treatment of this pathology, especially in suspected omentum necrosis, which implies the need for its resection [1, 2, 3, 4, 5, 6, 8]. Thus, the different standpoints result from the rarity of this pathology i.e. in the Breda Viesmana article and in a retrospective assessment covering 10 years, 40 cases were stated; 20 were epiploic appendagitis, 11 infarction of the gastrocolic omentum, and 9 were the cases where the differentiation of these pathologies was not possible [11]. In the material of the Polish authors Andrzej Smereczyński et al. in 1996-2009, epiploic appendagitis was diagnosed in 45 patients, twice more often in men, and two patients were operated on [10]. Laparoscopy avoids complications that sometimes occur as a result of conservative treatment (abscess or adhesions) that may cause episodes of omentum infarction [6]. Many authors emphasize the rarity of this pathology – less than 4 cases per 1,000 of acute appendicitis [14]. Nevertheless, the possibility of this pathology, especially in the work of the so-called 'ER', should be kept in mind. US and CT examinations are particularly useful in the diagnosis of IFFI [12, 13].

Unchanged epiploic appendices are not visible among the peritoneal fat until rotated, when they cause sudden, clearly localized pain, and in US show up as a hyperechoic oval foci, sometimes surrounded by a hypoechoic capsule (fibrinous exudate). These changes are localized in the anterior or anterolateral wall of the colon, most often in the sigmoid or descending colon, less often in the caecum. When pressed with the US transducer, the point of pain is stated with no change of shape; and if they are attached to the abdominal wall, no sliding movement is present with deep breathing. In Doppler studies, no evidence of increased vascularity is stated, as inflammation due to the infarction is poorly expressed [10, 13, 15].

In CT scan, the omental infarction area is visualized as well as the demarcated focus of adipose tissue density (-100j.H.), with hyperdense concentric bands, or in a 'vortex' shape [2, 6, 12].

CONCLUSIONS

Infarction of the gastrocolic omentum, or epiploic appendagitis, is an extremely rare pathology that can successfully be recognized by the radiologist in abdominal US or CT scan, provided that one bears this pathology in mind, knows the clinical data and can eliminate other causes of acute abdomen.

Proper radiological diagnosis of infarction of the gastrocolic omentum can save the patient from the surgical procedure and make conservative treatment possible.

REFERENCES

1. Sözen S, Dölalan S, Yıldız F, Elkan H. Primary omental torsion as a cause of acute abdomen: case report. *Ulus Travma Acil Cerrahi Derg.* 2011 Nov; 17(6): 554-6.
2. Barai KP, Knight BC. Diagnosis and management of idiopathic omental infarction: A case report. *Int J Surg Case Rep.* 2011; 2(6): 138-140.
3. Yoon JH, Park YK, Sohn BK, Jeon YC, Sohn JH, Han DS. A case of primary omental torsion presenting as an acute abdominal pain. *Korean J Gastroenterol.* 2007 Jan; 49(1): 41-4.
4. Papaziogas B, Dragoumis D, Tsiaousis P, Giakoustidis D, Atmatzidis S, Sarlis G, et al. Primary torsion of the greater omentum. An obscure and unusual cause of acute abdomen. *Surgery (Bucur).* 2007 Jan-Feb; 102(1): 95-8.
5. Peirce C, Martin ST, Hyland JM. The use of minimally invasive surgery in the management of idiopathic omental torsion: The diagnostic and therapeutic role of laparoscopy. *Int J Surg Case Rep.* 2011; 2(6): 125-7.
6. Goti F, Höllmann R, Stieger R, Lange J. Idiopathic segmental infarction of the greater omentum successfully treated by laparoscopy: report of case. *Surg Today.* 2000; 30(5): 451-453.
7. Grattan-Smith JD, Blews DL, Brand T. Omental infarction in pediatric patients: sonographic and CT findings. *AJR.* 2002; 178: 1537-1539.
8. Sarvepalli R, Kyle SM. Omental torsion: a rare cause of acute abdomen. *N Z Med J.* 2010 Jan 29; 123(1308): 81-2.
9. Reicher M, Łasiński W. In: Bochenek A, Reicher M: *Human anatomy. Vol. II.* Wydawnictwo Lekarskie PZWL. Warszawa, 1992 p. 152-193.
10. Smereczyński A, Bojko S, Gałdyńska M, Kładna K, Lubiński J, Starzyńska, et al. Własne doświadczenia w rozpoznawaniu zmian przyczepków sieciowych. Cz. 1. Pierwotne zapalenie przyczepków sieciowych. (Own experiences in diagnostics of lesions of the epiploic appendages. Pt 1. Primary epiploic appendagitis). *Ultrasonografia.* 2010; 10(40): 32-39 (in Polish).
11. Breda Vriesman AC, Lohle PNM, Coerkamp EG, Puylaert JBCM. Infarction of omentum and epiploic appendage: diagnosis, epidemiology and natural history. *Eur Radiol.* 1999; 9: 1886-1892.
12. Naffaa LN, Shabb NS, Haddad MC. CT findings of omental torsion and infarction: case report and review of the literature. *Clin Imaging.* 2003 Mar-Apr; 27(2): 116-8.
13. Miguel Perelló J, Aguayo Albasini JL, Soria Aledo V, Aguilar Jiménez J, Flores Pastor B, Candel Arenas MF, et al. Omental torsion: imaging techniques can prevent unnecessary surgical interventions. *Gastroenterol Hepatol.* 2002 Oct; 25(8): 493-6.
14. Itenberg E, Mariadason J, Khersonsky J, Wallack M. Modern management of omental torsion and omental infarction: a surgeon's perspective. *J Surg Educ.* 2010; 67(January-February (1)): 44-47.
15. Smereczyński A. Colon epiploic appendagitis in USG. *Pol Przegl Radiol.* 1999; 64: 54-57.