



Echinococcus multilocularis – first recorded case of Norway rat (*Rattus norvegicus*) in Poland

Maria Bernadeta Studzińska^{1,A-D,F}, Marta Demkowska-Kutrzepa^{1,A-C}, Jacek Karamon^{2,C-D}, Tomasz Cencek^{2,E}, Krzysztof Tomczuk^{1,E}

¹ University of Life Sciences, Lublin, Poland

² Department of Parasitology and Invasive Diseases, National Veterinary Research Institute, Pulawy, Poland

A – Research concept and design, B – Collection and/or assembly of data, C – Data analysis and interpretation, D – Writing the article, E – Critical revision of the article, F – Final approval of article

Studzińska MB, Demkowska-Kutrzepa M, Karamon J, Cencek T, Tomczuk K. *Echinococcus multilocularis* – first recorded case of Norway rat (*Rattus norvegicus*) in Poland. *Ann Agric Environ Med*. 2019; 26(4): 674–676. doi: 10.26444/aaem/113470

Abstract

Introduction. *Echinococcus multilocularis* is a very dangerous zoonotic parasite threatening human health. The red fox is the main definitive host, and cats and dogs less commonly. Rats can be intermediate hosts.

Objective. The aim of the study was to determine the parasitofauna of Norway rats and some cats and dogs living on a farm near a forest.

Materials and method. A parasitological section on 15 Norway rats was conducted. The internal organs were examined by means of macroscopic and microscopic methods. For molecular examination, a QIAmp DNA Mini Kit (Qiagen) was used.

Results. Based on necropsy, parasitological and molecular examinations, of the 15 examined rats, 1 was found to have larvae of *E. multilocularis*, while 3 others had eggs of *Hymenolepis diminuta*, *H. nana* and *Syphacia obvelata*. The faeces of the pets did not contain any developmental forms of parasites.

Conclusions. This is the first case of *Echinococcus multilocularis* infestation in a rat in Poland.

Key words

Echinococcus multilocularis, rodent, *Rattus norvegicus*, intermediate host, Poland

INTRODUCTION

Echinococcus multilocularis is one of the most dangerous zoonotic parasites that pose a threat to human health [1, 2, 3]. The literature abounds in studies devoted to this invasion in animals in different areas of the world and the resultant threat to human health. In Poland, 121 cases of alveococcosis in humans have been described, of which 23 (19%) died [1].

E. multilocularis is an armed tapeworm belonging to the *Taeniidae* family. It reaches 2–4 mm in length and its strobila consists of only 4–5 segments. It undergoes an indirect life cycle, and the definitive host is predominantly the red fox (*Vulpes vulpes*) [2]. The literature indicates that other animals are also definitive hosts, such as the racoon dog [4, 5, 6], Arctic fox [7], golden jackal [8], and the wolf [9, 4] as well as two domestic species, dogs and cats [10, 11, 12]. Intermediate hosts are found mainly among rodents, such as muskrats, arvicolid and voles, in which the larval form develops in the liver. Less frequently, *E. multilocularis* are found in murids and coypus [2]. In contrast, pigs and horses, similarly to humans, are not typical intermediate hosts, which rarely develop the invasive form [12, 14, 15]. Intermediate hosts, including humans acting as aberrant intermediate hosts, are infected through the ingestion of eggs excreted in the faeces of definitive hosts.

Studies on the prevalence of *E. multilocularis* in foxes have been conducted in Poland, the same as in other European countries, yielding a mean prevalence at 16.5%, with significant variation in different regions of the country (which

in the case of the north-east and south-east reached 50%). In the area of the Lublin Province, where the studies presented in the article were carried out, the prevalence of foxes was 18.2 [16]. In Poland, an invasion by *E. multilocularis* was found in 2 dogs, which was confirmed by molecular examinations [10]. However, no tapeworms have been reported in cats. No studies into the presence of its larval stages in rodents have been performed. Earlier research by Malczewski et al. [17] did not yield positive outcomes.

OBJECTIVE

The aim of the study was to determine the prevalence of parasitofauna in the Norway rat (*Rattus norvegicus*), with particular regard to its role as an intermediate host for the *E. multilocularis* tapeworm, and also to determine the prevalence of parasitofauna in companion animals (cats and dogs) living on the farm where the examined rats were obtained.

MATERIALS AND METHOD

The research covered 15 Norway rats collected during routine rat extermination. All of them originated from one farm in the Lublin Province, located about 1 km from forest areas. Additionally, red foxes were very often seen on this farm.

A parasitological dissection of the rodents was conducted. The internal organs (liver, lungs, heart, kidney and gastrointestinal tract) were examined by means of parasitological macroscopic and microscopic methods. The macroscopic examination involved a visual inspection and

Address for correspondence: Krzysztof Tomczuk, University of Life Sciences in Lublin, Poland
E-mail: krzysztof.tomczuk@up.lublin.pl

Received: 26.07.2019; accepted: 16.10.2019; first published: 26.11.2019

incision of the internal organs. The microscopic examinations of intestinal content were carried out using a flotation technique involving a saturated solution of salt and sucrose (specific gravity 1.28–1.30), and a decantation method to evaluate qualitatively the composition of parasitofauna [18]. Particular species were identified morphologically with cell light microscope system software (Olympus) [19]. The mucous membrane and scraped fragments of the bowels were inspected using a biological microscope.

For identification, the isolated parasites were immersed in 70% ethanol with 5% glycerin [20, 21]. The tissues and internal organs in which lesions had been identified were placed into 70% ethanol for molecular examination. The diaphragm muscles and other striated muscles were examined using the digestion method in order to detect *Trichinella spiralis* larvae [18].

For molecular examination, the DNA of the tissues with lesions was isolated using a QIAmp DNA Mini Kit (Qiagen) in accordance with the manufacturer's instructions. A nested PCR method was used, as described by Dinkel et al. [22], with some modifications concerning the reaction mixture and time conditions of amplification [14]. The sequence for amplification was a section of the *E. multilocularis* mitochondrial 12S rRNA gene. The fragment specific to *E. multilocularis* (250 bp) was amplified. The *E. multilocularis* positive products of nested PCR were sequenced. The samples for sequencing were purified in Sephadex G-50 columns. Sequencing was performed using a BigDye™ Terminator v3.1 Cycle Sequencing kit (Applied Biosystems) on an ABI3730xl Genetic Analyzer (Applied Biosystems). The sequenced data were analyzed and compared in the GenBank using BLAST searchers.

Additionally, the parasitological examination covered faeces from 2 dogs and 7 cats living on the farm. These animals live mainly outdoors and can freely access the area surrounding the farm. Their faeces was examined 3 times at 24-hour intervals using a flotation technique involving a saturated solution of salt and sucrose (specific gravity 1.28–1.30) and a decantation method to evaluate qualitatively the composition of parasitofauna [18]. Particular species were identified morphologically with cell light microscope system software (Olympus) [23].

RESULTS

In the liver of 1 rat, the macroscopic examination revealed cystic, soft, 2–4 mm large follicles, attached to one another and filled with fluid. The lesions were extensive and encompassed over half the liver (Fig. 1,2). The whole isolated liver was placed in 70% alcohol and sent to the State Veterinary Institute in Puławy, Poland, for further molecular examination, which found the follicles to be *E. multilocularis* larvae. The specific PCR product (250 bp) was found in nested PCR. A comparison of the sequencing results of the obtained amplicons with the GenBank database confirmed that the causative agent, in all 3 cases, was *E. multilocularis* (sequences corresponding to *E. multilocularis* mitochondrial 12S rRNA gene).

Microscopic examination of the intestinal content in 3 other rats, employing both flotation and decantation, revealed the presence of parasitic eggs. In 2 rats, eggs of the *Hymenolepis diminuta* tapeworm were detected, and were

single invasions (with 1 species). In contrast, a mixed invasion was detected in 1 rat, with eggs of *H. nana* and eggs of the *Syphacia obvelata* nematode. For the rat which was found to have *E. multilocularis* larvae; microscopic examination was negative. No *Trichinella* spp. larvae were found in the muscles of the examined rats.

The faeces obtained from the companion animals (cats and dogs) did not contain any developmental forms of parasites.

DISCUSSION

Rodents, including rats, are often subject to other pathogens while living in various environments (silvatic or synanthropic), including those parasites which threaten human health. One of them is *E. multilocularis*, with humans serving as aberrant, non-specific intermediate hosts. In this role, humans are infected through ingestion of eggs excreted in the faeces of a definitive host [2]. As definitive hosts, carnivores living in the wild (mainly red fox) and domesticated animals, such as cats and dogs, become infested by ingesting intermediate hosts. Various authors have confirmed the presence of the larval forms in small rodents, e.g. the common vole (*Microtus arvalis*), water vole (*Arvicola amphibius*), bank vole (*Myodes glareolus*), field vole (*Microtus agrestis*), and various *Apodemus* species [24]. However, there are few reports concerning Norway rats as intermediate hosts for *E. multilocularis*. In Europe, the larvae of this tapeworm were found in *Rattus norvegicus* in Romania [25]. Outside Europe, its presence has been demonstrated in rat liver in Japan. Of the 42 examined animals, only 1 exhibited protoscolexes in large liver cysts [26].

CONCLUSIONS

The discovery of the larval forms of the *E. multilocularis* tapeworm in a rat is the first recorded case in Poland. This proves that rats can indeed be an important link in the spread of this invasion on farms and in the immediate vicinity of humans. Companion animals (cats, dogs) which hunt and reside on farms can become infested, and consequently pose a significant danger to human health. Although the

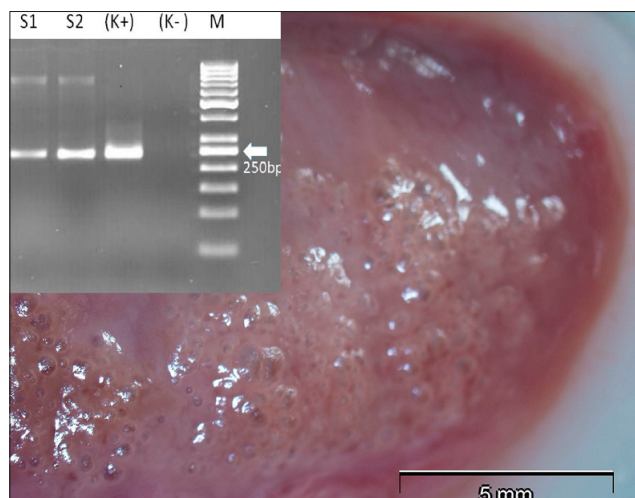


Figure 1. Macroscopic photos of Norway rat liver containing *Echinococcus multilocularis* metacestode lesions

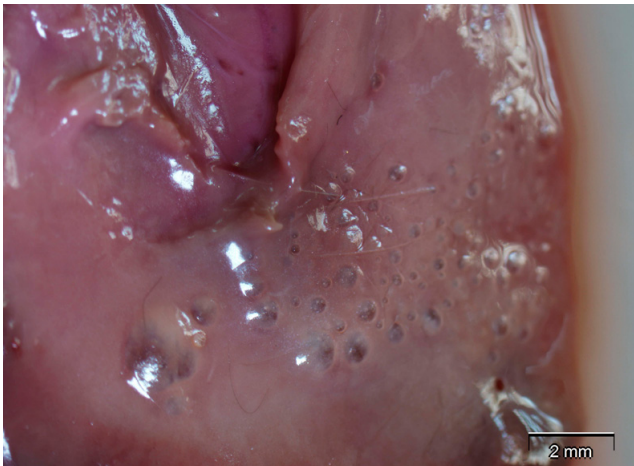


Figure 2. Macroscopic photos of Norway rat liver containing *Echinococcus multilocularis* metacestode lesions

result of the parasitological examination of the companion animals was negative, the risk of them becoming infested cannot be excluded. It should be remembered that these are hunting animals which live mainly outdoors and are in contact with the natural environment surrounding the farms. The detection of the larval form in a rat confirms the fact that foxes living in the vicinity of the farm are infested. The farm has been monitored and the companion animals periodically examined for the presence of parasites.

REFERENCES

- Nahorski WL, Knap JP, Pawlowski ZS, Krawczyk M, Polanski J, Stefaniak J, Patkowski W, Szostakowska B, Pietkiewicz H, Grzeszczuk A, Felczak-Korzybska I, Gołąb E, Wnukowska N, Paul M, Kacprzak E, Sokolewicz-Bobrowska E, Niscigorska-Olsen J, Czyrznikowska A, Chomicz L, Cielecka D, Myjak P. Human Alveolar Echinococcosis in Poland: 1990–2011. *Plos Neglect Trop D.* 2013; 7: 1986.
- Oksanen A, Siles-Lucas M, Karamon J, Possenti A, Conraths FJ, Romig T, Wysocki P, Mannocci A, Mipatrini D, La Torre G, Boufana B, Casulli A. The geographical distribution and prevalence of *Echinococcus multilocularis* in animals in the European Union and adjacent countries: a systematic review and meta-analysis. *Parasit Vectors.* 2016; 9: 519.
- Thompson ARC. Parasite zoonoses and wildlife: One health, spillover and human activity. *Int J Parasitol.* 2013; 43: 1079–1088.
- Bagrade G, Deksne G, Ozoliņa Z, Howlett SJ, Interisano M, Casulli A, Pozio E. *Echinococcus multilocularis* in foxes and raccoon dogs: an increasing concern for Baltic countries. *Parasit Vectors.* 2016; 9: 615.
- Laurimaa L, Süeld K, Moks E, Valdmann H, Umhang G, Knapp J, Saarma U. First report of the zoonotic tapeworm *Echinococcus multilocularis* in raccoon dogs in Estonia, and comparisons with other countries in Europe. *Vet Parasitol.* 2015; 212: 200–205.
- Machnicka-Rowińska B, Rocki B, Dziemian E, Kolodziej-Sobocinska M. Raccoon dog (*Nyctereutes procyonoides*) the new host of *Echinococcus multilocularis* in Poland. *Wiad Parazytol.* 2002; 48: 65–68.
- Stien A, Voutilainen L, Haukisalmi V, Fuglei E, Mørk T, Yoccoz NG, Ims RA, Henttonen H. Intestinal parasites of the Arctic fox in relation to the abundance and distribution of intermediate hosts. *Parasitology.* 2010; 137: 149–57.
- Széll Z, Marucci G, Pozio E, Sréter T. *Echinococcus multilocularis* and *Trichinella spiralis* in golden jackals (*Canis aureus*) of Hungary. *Vet Parasitol.* 2013; 197: 393–396.
- Martínek K, Kolárová L, Hapl E, Literák I, Uhrin M. *Echinococcus multilocularis* in European wolves (*Canis lupus*). *Parasitol Res.* 2001; 87: 838–839.
- Karamon J, Samorek-Pieróg M, Kochanowski M, Dąbrowska J, Sroka J, Gołąb E, Umhang G, Cencek T. First detection of *Echinococcus multilocularis* in dogs in a highly endemic area of Poland. *Folia Parasitol.* 2016; 63: 018.
- Umhang G, Comte S, Raton V, Hormaz V, Boucher JM, Favier S, Combes B, Boué F. *Echinococcus multilocularis* infections in dogs from urban and peri-urban areas in France. *Parasitol. Res.* 2014; 113: 2219–2222.
- Dyachenko V, Pantchev N, Gawłowska S, Vrhovec MG, Bauer C. *Echinococcus multilocularis* infections in domestic dogs and cats from Germany and other European countries. *Vet Parasitol.* 2008; 157: 244–253.
- Goto Y, Sato K, Yahagi K, Komatsu O, Hoshina H, Abiko C, Yamasaki H, Kawanaka M. Frequent isolation of *Echinococcus multilocularis* from the livers of racehorses slaughtered in Yamagata, Japan. *Jpn J Infect Dis.* 2010; 63: 449–451.
- Karamon J, Sroka J, Cencek T. The first detection of *Echinococcus multilocularis* in slaughtered pigs in Poland. *Vet Parasitol.* 2012; 185: 327–329.
- Kimura M, Toukairin A, Tazaki H, Tanak S, Harada K, Araiya J, Yamasaki H, Sugiyama H, Morishima Y, Kawanaka M. *Echinococcus multilocularis* detected in slaughtered pigs in Aomori the Northernmost prefecture of Mainland Japan. *Jpn J Infect Dis.* 2010; 63: 80–81.
- Karamon J, Kochanowski M, Sroka J, Cencek T, Różycki M, Chmurzyńska E, Bilska-Zajac E. The prevalence of *Echinococcus multilocularis* in red foxes in Poland – current results (2009–2013). *Parasitol Res.* 2014; 113: 317–322.
- Malczewski A, Borecka A, Malczewska M, Gawor J. An attempt to determine intermediate hosts of the tapeworm *Echinococcus multilocularis* in Poland. *Wiad Parazytol.* 2008; 54: 137–141.
- Gundlach JL, Sadzikowski AB. Diagnostyka i zwalczanie inwazji pasożytów u zwierząt. WAR, Lublin, Poland, 2005.
- Baker DG. Parasites of Rats and Mice. In: Baker DG, editors. *Flynn's Parasites of Laboratory Animals.* 2nd Edition. Wiley-Blackwell; 2007. p. 303–397.
- Smith PH, Wiles SE, Malone JB, Monahan CM. Collection, Preservation, and Diagnostic Methods. In: Baker DG, editors. *Flynn's Parasites of Laboratory Animals.* 2nd Edition. Wiley-Blackwell; 2007. p. 1–13.
- Furmaga S. Helmintofauna gryzoni polnych (Rodentia) okolic Lublin. The helminth fauna of field rodents (Rodentia) of the Lublin environment. *Acta Parasitol Pol.* 1957; 5: 9–50.
- Dinkel A, von Nickisch-Rosenegk M, Bilger B, Merli M, Lucius R, Romig T. Detection of *Echinococcus multilocularis* in the definitive host: Coprodiagnosis by PCR as an alternative to necropsy. *J Clin Microbiol.* 1998; 36: 1871–1876.
- Zajac AM, Conboy GA. *Veterinary Clinical Parasitology 8th.* American Association of Veterinary Parasitologists, Wiley-Blackwell, 2012.
- Miller AL, Olsson GE, Walburg MR, Sollenberg S, Skarin M, Ley C, Wahlström H, Höglunda J. First identification of *Echinococcus multilocularis* in rodent intermediate hosts in Sweden. *Int J Parasitol Parasites Wildl.* 2016; 5: 56–63.
- Siko Barabasi S, Marosfoi L, Siko Barabasi Z, Cozma V. Natural alveolar echinococcosis with *Echinococcus multilocularis* in wild rodents. *Sci Parasitol.* 2011; 12: 11–21.
- Okamoto M, Fujita O, Arikawa J, Kurosawa T, Oku Y, Kamiya M. Natural *Echinococcus multilocularis* infection in a Norway rat, *Rattus norvegicus*, in southern Hokkaido, Japan. *Int J Parasitol.* 1992; 22: 681–684.



Ministry of Science
and Higher Education

Republic of Poland

Generation of the DOI (Digital Object Identifier) – task financed under the agreement No. 618/P-DUN/2019 by the Minister of Science and Higher Education