

*Andrzej MAX, Piotr JURKA, Bartłomiej J. BARTYZEL<sup>1</sup>, Beata GRZEGRZÓŁKA<sup>2</sup>*

## FOETAL MORTALITY IN DOGS AND CATS NOT RELATED TO SPONTANEOUS ABORTIONS

### ZAMIERANIE PŁODÓW U PSÓW I KOTÓW NIEZWIĄZANE Z RONIENIEM

Department of Small Animal Diseases with Clinic, Warsaw University of Life Sciences – SGGW, Warsaw, Poland

<sup>1</sup>Department of Morphological Sciences, Warsaw University of Life Sciences – SGGW, Warsaw, Poland

<sup>2</sup>Department of Genetics and Animal Breeding, Warsaw, Poland

**Streszczenie.** Obumieralność zarodków jest związana z całkowitą resorpcją tkanek i płynów z jamy macicy. Zamieranie płodów zwykle skutkuje całkowitym lub częściowym poronieniem. Czasem jednak martwe płody i błony płodowe pozostają w macicy do czasu porodu, a nawet dłużej. Informacje w tym obszarze są skąpe, bez badań epidemiologicznych. Każdy nowy przypadek poszerza wiedzę w tym zakresie. Celem pracy było ustalenie zróżnicowanych następstw zamierania płodów u małych zwierząt. Na podstawie wybranych przypadków pochodzących z praktyki ginekologiczno-położniczej udokumentowano następstwa zamieralności płodów bez ich ronienia. Wymieniono następujące następstwa: całkowitą resorpcję zarodka/płodu i błon płodowych, resorpcję tkanek płodu z pozostaniem błon płodowych, mumifikację lub macerację płodu.

**Key words:** cat, dog, foetal mortality, maceration, mummification.

**Słowa kluczowe:** kot, maceracja, mumifikacja, obumieralność zarodków, pies.

## INTRODUCTION

Foetal or embryonic deaths in dogs and cats, as well as in other animal species, may occur at any stage of a pregnancy. As early as in the initial stage of reproduction we can observe defects in germ cells, which result in unsuccessful fertilization, or, when fertilization does take place, death of the conceptus. Of particular importance are chromosome aberrations, which occur spontaneously or as a result of mutagenic factors and most often lead to a death of a defective embryo, especially in the case of autosomal aberrations. Other, external factors, both non-infectious (e.g. toxins) and infectious (bacterial, viral or protozoal), that are harmful to initially normal embryos and then fetuses may, too, cause their deaths. The embryonic period in dogs and cats lasts 28–30 days following fertilization. Therefore, a partial or total loss of a pregnancy in that period results from embryonic mortality. Most often it entails the resorption of all fluids and tissue. At a later stage of a pregnancy, foetal

---

Corresponding author – Adres do korespondencji: PhD Andrzej Max, Department of Small Animal Diseases with Clinic, Faculty of Veterinary Medicine, Warsaw University of Life Sciences – SGGW, Nowoursynowska 159c, 02-776 Warsaw, Poland, e-mail: andrzej\_max@sggw.pl

deaths are usually caused by their spontaneous abortion. However, blighted foetuses and foetal membranes sometimes remain in the uterus until the term of parturition or even longer (Serin and Parin 2009). If they develop a bacterial infection, it may result in the septicaemia and toxæmia in mothers, causing the appearance of general symptoms. Sometimes a vaginal discharge, usually russet in colour and sometimes malodorous, can be observed (Holyoak et al. 2009). However, if a foetus is not expelled, there are usually no clinical symptoms suggesting a death of one, several or all foetuses (Serin and Parin 2009). Retention of dead foetuses may result in their mummification, maceration or expulsion on the physiological date of parturition (Romagnoli 2002), depending on the reason for the death of a foetus, stage of a pregnancy and immunological interactions between the mother and the foetus. One basic clinical problem is the lack of a test that would enable an assessment of a normal development or death of an embryo/foetus (Romagnoli 2002), especially taking into account the fact that in the case of animals with a multiple pregnancy, normal foetuses may accompany dead ones. Data on foetal stillbirths is varied, and their percentage is estimated at 7–29% of all reproductive losses in the period from the birth to the late neonatal period (Gill 2001, Lawler 2008). Detailed data published in 2001 shows that out of 2574 analysed puppies, 180 (7%) were stillborn, including 13 (0.5%) mummified foetuses, 18 (0.7%) foetuses that died prior to the delivery, 23 (0.9%) underweight puppies, and 71 (2.8%) puppies whose death was caused by primary congenital defects. The total number of delivered newborns with abnormal build was at 4.9% ( $n = 125$ ) of all the observed puppies (Gill 2001).

Unlike the problem of perinatal and neonatal deaths, which was analysed in depth based on extensive research material (Gill 2001, Tønnessen et al. 2012), there is no epidemiological data on prenatal deaths that are not related to a spontaneous abortion, and the scope of the phenomenon is not known. As often there are no general symptoms in mothers, prompting breeders to seek professional medical help, a lot of such cases are not revealed, diagnosed or are wrongly interpreted. As information of the problem are primarily acquired from casuistic publications, records and descriptions of such atypical cases increase the knowledge in this area.

The aim of the study was to analyse the results of foetal deaths in dogs and cats that did not end in a miscarriage.

## **MATERIAL AND METHODS**

The study was performed on selected clinical cases of embryonic/foetal deaths in dogs and cats without a spontaneous abortion observed in relation to the help provided during deliveries. The cases were analysed in order to reconstruct the course of events. In addition, the analysis was documented with photographs. According to Latshaw (1987) embryonic period is completed from 30 to 35 days in dogs and from 29+ days in cats. It is not always possible to estimate precisely the age of the conceptus under clinical conditions. To this reason the term “embryonic/foetal death” is used sometimes. The analysis included five own cases, and namely 4 dogs (unknown breed, rottweiler, Akita-inu and miniature pinscher) and one cat Devon Rex. They were compared to other cases described in the literature.

## RESULTS AND DISCUSSION

Deaths of part of all of foetuses and embryos may occur at different stages of their development. Mortality that occur before the confirmation of a pregnancy remain clinically unrecognized. It can be assumed that in the case of normal fertility, all ovulated oocytes are fertilized. Figure 1 shows ovaries of a female dog with at least 11 corpora lutea, which suggests that 11 embryos should develop.

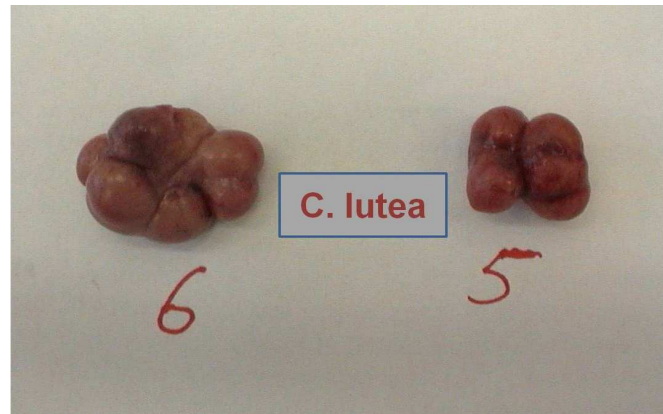


Fig. 1. Ovaries with visible corpora lutea of a pregnant female dog  
Rys. 1. Jajniki ciężarnej suki z widocznymi ciałkami żółtymi

However, only 8 chorioallantoic vesicles were found in the uterus of the animal (Fig. 2).

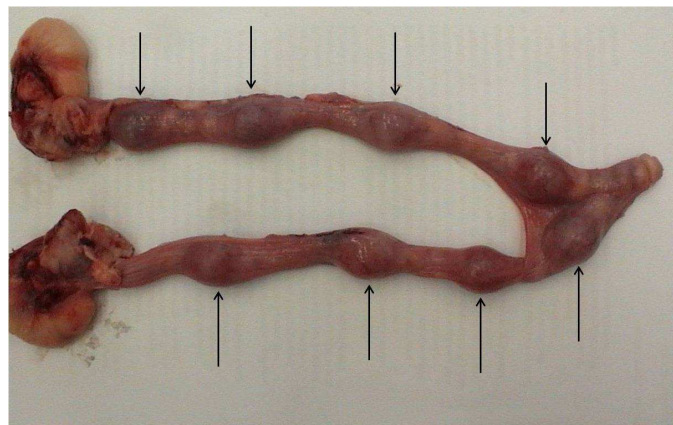


Fig. 2. Uterus of the same dog – visible extension of the horns in the sites of embryonic vesicles (arrows)  
Rys. 2. Macica tej samej suki – widoczne rozszerzenia rogów w miejscach pęcherzy owodniowych (strzałki)

Therefore, it can be assumed that not all oocytes underwent the maturation and fertilization process, which seems less likely, or – which is more likely – that 3 embryos had died, while other continued to develop. Exploratory laparotomies showed 5–13% differences between the number of corpora lutea in the ovaries and the number of embryonic vesicles (Romagnoli 2002). In cases of embryonic mortality, ultrasound examinations show a lack of development or an abnormal shape of amniotic vesicles, a decrease in the size of the

embryo and in the volume of amniotic fluid and an increase in its echogenicity (Romagnoli 2002). A death of one or several embryos does not influence the further development of the remaining ones, located in the same or the other uterine horn. Most frequently no other additional signs can be observed clinically. One other example confirmed an embryonic/foetal death in a female Rottweiler of 5 years of age. Two previous pregnancies in the bitch ended with a caesarean section. The animal underwent ovariohysterectomy 2 months after the last mating. No signs of pregnancy were observed around the expected term of delivery. At the request of the dog's owner, a laparotomy was performed in order to remove the uterus and the ovaries. There were no foetuses in the uterus, but placental remnants were clearly visible (Fig. 3), which suggests that the pregnancy had been developing for at least four weeks, after which all the foetuses died. It could be related to numerous endometrial cysts as a result of which the contact between the allantochorion and the endometrium was strongly limited.

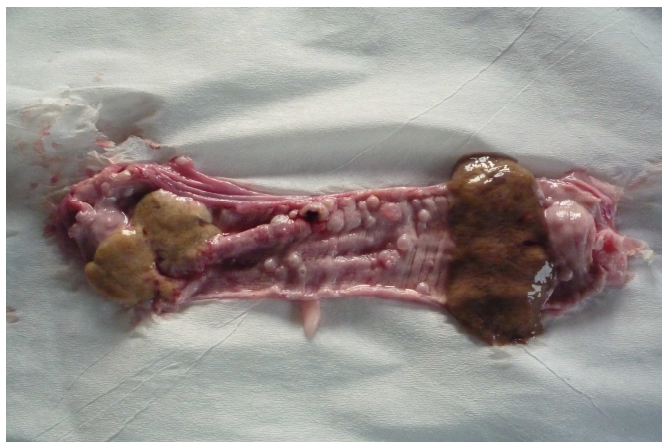

Fig. 3. Uterine mucous membrane of a dog – visible cysts and remnants of placenta  
Rys. 3. Błona śluzowa macicy suki – widoczne torbiele i pozostałości łożyska

Another proof of an embryonic/foetal death was the remnant of a partly mummified placenta expelled during the delivery together with normally developed foetuses in a female Devon rex cat (Fig. 4).

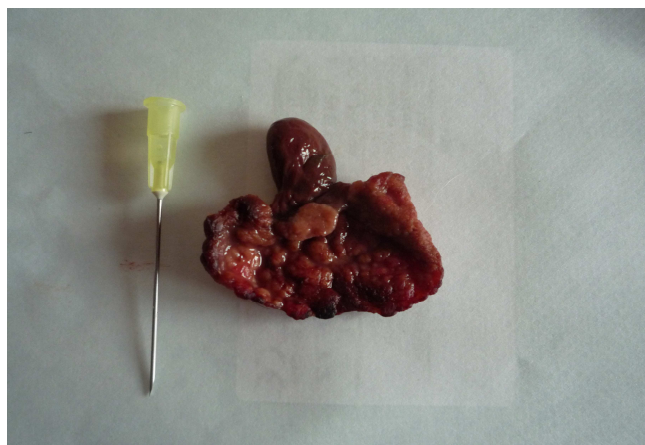


Fig. 4. Partly mummified placenta of a cat expelled at a natural delivery  
Rys. 4. Częściowo zmumifikowane łożysko kota wydalone podczas naturalnego porodu

If only some foetuses die, while other continue to develop until the end of a pregnancy, the dead and mummified foetuses and foetal membranes may remain in the uterine cavity until the delivery, at which time they are expelled (Fig. 5) or found during a caesarean section.

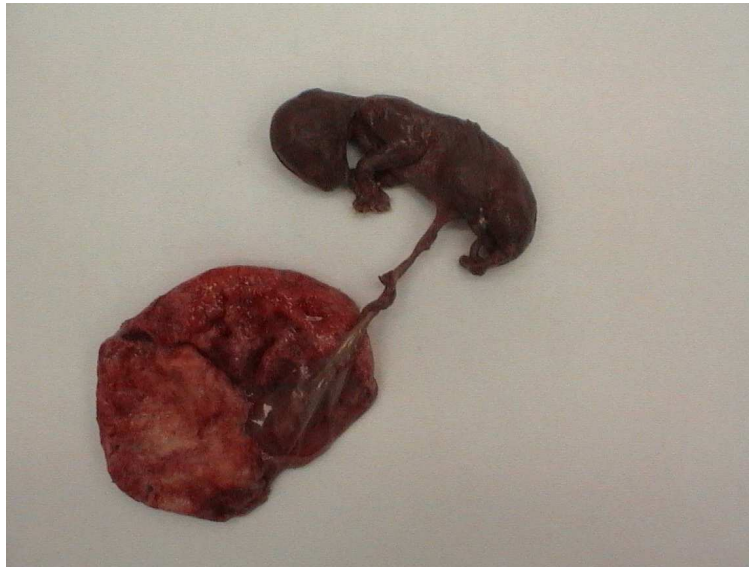

Fig. 5. Mummified foetus with a placenta expelled at a natural delivery  
Rys. 5. Zmumifikowany płód z łożyskiem wydalony podczas naturalnego porodu

The latest took place in the Akita inu female dog, in which one dead foetus (Fig. 6) and eight alive foetuses were found. The mummification of foetuses is a nonbacterial process, but it may sometimes be related to viral or protozoal infections, including the herpes virus infection or neosporosis in dogs.



Fig. 6. Mummified foetus surrounded by the foetal membranes removed during caesarean section together with normally developed puppies  
Rys. 6. Zmumifikowany płód otoczony błonami płodowymi wyjęty podczas cięcia cesarskiego razem z normalnie rozwiniętymi szczeniętami

Another example was the case of a female Pinscher dog of 2.5 years of age, in which a pseudopregnancy was observed 2.5 months after the oestrus. The animal was treated with cabergoline (Galastop). The bitch was brought to the clinic 3.5 months later due to a rust-coloured vaginal discharge, which, in the owner's opinion, was indicative of another heat. A physical examination did not reveal any external signs of the ovarian follicular activity, including vulvar oedema, bloody outflow, redness of the mucous membrane. The owners, who also have a male dog, did not notice its interest in their female dog. The examination showed compact structures in the abdominal cavity, which seemed to be hard faecal masses, but which were located below the normal position of the rectum. A rectal examination confirmed the presence of the masses, but they could not be directly accessed. It was possible that the bodies were present in the uterus. As the owner wanted the bitch to be sterilized, a laparotomy was promptly performed. After a midline abdominal incision was made, making it possible to access the uterus, it was found that the uterus was enlarged and filled with compact tissue masses in the area of the horn and body of the uterus (Fig. 7).

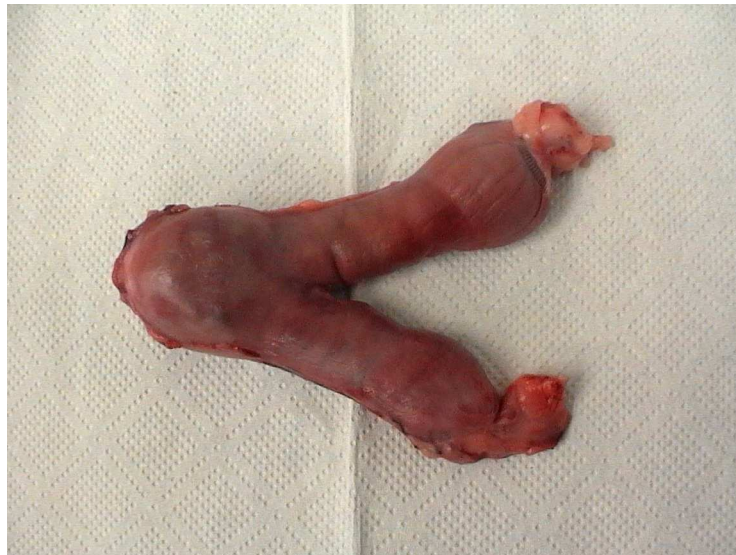

Fig. 7. Canine uterus with macerated foetuses  
Rys. 7. Macica psa ze zmacerowanymi płodami

Ovariohysterectomy was performed, followed by the opening of the uterus and removal of its content, i.e. macerated foetal tissues. The analysis of bones showed that the tissues belonged to two foetuses (Fig. 8).

The described pregnancy was a consequence of unplanned mating during the oestrous cycle about 6 months earlier. At the first visit foetuses were not identified in the uterus (however, it is possible that they had already died), which resulted in the wrong diagnosis of a pseudopregnancy. In consequence, the foetal tissues underwent maceration, which is sporadically observed in dogs. Maceration results from a bacterial infection of the content of the uterus, causing the liquefaction, autolysis and resorption of soft tissues, while bones remain in the uterus.



Fig. 8. Bones of the macerated foetuses  
Rys. 8. Kości zmacerowanych płodów

One specific cause of the retention of dead foetuses is the use of long-acting progestagens during a pregnancy in female dogs (England 1998) and cats (Dejneka and Bielas 1995). The other interesting case of foetal deaths occurred after human chorionic gonadotropin (hCG) was administered to a pregnant female dog, which resulted in a significant prolongation of the activity of corpora lutea (Urhausen et al. 2009). González-Dominguez and Maldonado-Estrada (2006) described the case of a 5-year-old female fox terrier dog, which was treated with long-acting medroxyprogesterone acetate for contraception. On the 74<sup>th</sup> day following the unwanted mating macerated foetuses were diagnosed by clinical and radiographic findings and ovariohysterectomy was performed. Similarly, a treatment with corticosteroids during a late pregnancy resulted in foetal mortality with maceration in a bulldog and a German shepherd dog (<http://kmbase.medic.or.kr/Main.aspx?d=KMBASE&m=VIEW&i=1094019970140010112>). Exceptional cases, such as necrotizing metritis with capillary granulomas resulting from a long (lasting about 5 months) retention of a foetus in a 5-year-old female boxer dog (Günzel-Apel et al. 2008), are very rare. Occasionally other concurrent symptoms may be observed, which accompany specific complications. One example was a 10-month-old female pointer dog, in which the retention of a foetus and its partial resorption resulted in both endometritis and a severe hypercalcemia. The administered pharmacological treatment did not lower the calcium blood concentration to the physiological level. The decrease occurred in four days following the removal of the uterus and ovaries (Hirt et al. 2000).

The presented overview of the authors' clinical cases in small animals shows that the death of a conceptus which was not expelled may result in the total resorption of embryos/foetuses and foetal membranes, resorption of foetal tissues with the retention of foetal membranes mummification or maceration of the foetus. This situation may be due, at least in part, to scarcity of hormonal factors inducing activity of the myometrium or block of this activity.

## REFERENCES

- Dejneka G.J., Bielas W.** 1995. A case of overdue pregnancy in a queen (in Polish). *Mag. Weter.* 4, 489–489.
- England G.C.W.** 1998. Complications of treating presumed pseudopregnancy in pregnant bitches. *Vet. Rec.* 142, 369–371.
- Gill M.A.** 2001. Perinatal and late neonatal mortality in the dog. PhD thesis, The University of Sydney, 50–51.
- Givens M.D., Marley M.S.D.** 2008. Infectious causes of embryonic and fetal mortality. *Theriogenology* 70, 270–285.
- González-Domínguez M.S., Maldonado-Estrada J.G.** 2006. Prolonged pregnancy associated to an inappropriate medroxyprogesterone acetate prescription in a bitch: Is rational and ethics the use of exogenous progestin in the bitch? *Rev. Colomb. Cien. Pecuarias* 19, 442–450.
- Günzel-Apel A.R., Fehr M., Seefeldt A., Reischauer A., Schoon H.A.** 2008. Prolonged foetal retention in a bitch resulting in trichogranulomatous panmetritis and re-establishment of fertility after unilateral ovariohysterectomy. *Reprod. Domestic Anim.* 43, 117–120.
- Hirt R.A., Kneissl S., Teinfalt M.** 2000. Severe hypercalcemia in a dog with a retained fetus and endometritis. *J. Am. Vet. Med. Assoc.* 216, 1423–1425.
- Holyoak G.R., Makloski C., Morgan G.L.** 2009. Abortion, Abnormal Estrous Cycle, and Infertility [in: Lorenz M. D., T. M. Neer, P. DeMars: *Small Animal Medical Diagnosis*, (3 Rev ed.)] Iowa State University Press, 337–356.
- Latshaw W.K.** 1987. *Veterinary Developmental Anatomy*. B.C. Decker Inc., Toronto, 86.
- Lawler D.F.** 2008. Neonatal and pediatric care of the puppy and kitten. *Theriogenology* 70, 384–392.
- Romagnoli S.** 2002. Complications in canine pregnancy and their clinical approach. *Proceedings of the Veterinary Sciences Congress, SPCV, Oeiras*, 10–12 Oct., 159–162.
- Serin G., Parin U.** 2009. Recurrent vaginal discharge causing by retained foetal bones in a bitch: a case report. *Veter. Med.* 54, 287–290.
- Tønnessen R., Borge K.S., Nødtvedt A., Indrebø A.** 2012. Canine perinatal mortality: A cohort study of 224 breeds. *Theriogenology* 77, 1788–1801.
- Urhausen C., Schöne J., Meyer-Lindenberg A., Günzel-Apel A.R.** 2009. An extraordinary iatrogenic prolongation of pregnancy in a German Shepherd Dog. A case report. 6th EVSSAR Annual Symposium, Wrocław, 79.

**Abstract.** Embryonic mortality is associated with full resorption of tissues and fluids from the uterine cavity. Foetal mortality usually results in complete or partial abortion. Sometimes, however, dead fetuses and foetal membranes retain in the uterus till term or even longer. There are only scant information in this area, without epidemiological studies. Each new case widens the knowledge of this condition. The objective of the study was to determine the variations of follow-up of foetal mortality in small animals. On the basis of chosen clinical cases coming from gynaecological and obstetric practice the consequences of foetal mortality without a miscarriage were documented. They were listed as follow: total resorption of the embryo/foetus and foetal membranes, resorption of foetal tissues with remaining of foetal membranes, foetal mummification and foetal maceration.