

Computed tomographic and densitometric analysis of tibiotarsal bone mineral density and content in postnatal Peking ducks (*Anas platyrhynchos var. domestica*) as influenced by age and sex

A. Charuta¹, R.G. Cooper²

¹ Vertebrates Morphology Department, Siedlce University of Natural Sciences and Humanities, 08-110 Siedlce, Poland

² Physiologist, Eurohouse, D/Kennel Lane, Walsau WS1 2BU, England, UK

Abstract

The bone mineral density BMD and content BMC were analysed in the tibiotarsal bones of ducks in the postnatal development as influenced by age and sex. One hundred birds from the nesting till the slaughtering maturity were included in the experiment. The analysis was conducted using a densitometer, Norland – Excell Plus and pQCT computed tomography, XCT Research SA Plus.

The statistical analysis was conducted using the Kruskal-Wallis one-way analysis of variance (age) and the U-Mann -Withney test (sex). All calculations were performed in Statistica 9.0 (StatSoft, Inc. Tulsa, USA), at $P \leq 0.05$. Two-factor analysis of variance ANOVA was applied and Pearson's correlation coefficients were calculated.

The densitometer research showed that BMD and BMC increased in the postnatal development for both sexes. The volumetric bone mineral density vBMD analysis using computed tomography showed that volumetric bone mineral density vBMD of the middle of the diaphyses *in situ* gradually attenuated during the postnatal development both in males and females, i.e. from 620 mg/cm³ (2 wk) to 500 mg/cm³ (8 wk). The biggest vBMD loss was observed in the diaphyses of females in 4 and 6 wk ($r = -0.63$ and $r = -0.79$; $P \geq 0.05$).

The BMC decrease was observed in the proximal metaphyses between 4 and 6 wk for both sexes, $r = -0.52$ (males), $r = -0.53$ (females); $P \leq 0.05$. The gradual loss may be the cause of deformities and fractures of the tibiotarsal bones observed from 4 wk in particular bone sections of both sexes. The achieved results may constitute a helpful source of information for water poultry breeders to prevent limb diseases.

Key words: bone mineral density (BMD), volumetric bone mineral density (vBMD), bone mineral content (BMC), tibiotarsal bone, duck meat, mineralisation

Introduction

Vertebrates' bones constitute a special type of the connective tissue which undergoes constant forming and rebuilding. It should be emphasised that a bone of a mature bird, after reaching sexual maturity, differs from that in the first weeks especially in the bone weight. Current farming conditions based on intensive feeding and nutrition as well as genetic selection of birds focus mainly on attainment of a fast growth rate expressed as body weight. Introducing birds of high productive parameters to breeding predisposes to frequent and unexplained etiopathogenetic health and skeletal problems. High body weight in poultry as well as lack of balance in the growth of the muscle mass and bones potentiate deformities and bone fractures, specifically of the tibiotarsal bones of poultry like chicken broilers (Celo and Diniz 1997), ducks (Charuta et al. 2011), geese (Charuta et al. 2012), turkeys (Burs et al. 2008, Charuta et al. 2012) and ratites (Bezuidenhout 1993, Horbańczuk et al. 2004, Cooper et al. 2008a, Cooper et al. 2010).

Taking into account the frequency of pathologies of the bone tissue in poultry and observing clear health problems connected with the locomotor function and the shape of limbs of domestic ducks growing intensively, an attempt was made to explore this illness. As a consequence, it is very important to know the structure of the bone tissue in the postnatal development. Studying densitometric features of the tibiotarsal bones with the use of computed tomography pQCT is one of the methods allowing the determination of the structure of bones, their mineralisation and the recognition of disorders in the structure of bones, which may be connected with dynamic forces and deforming loading. There are many methods of intravital evaluation of the skeletal system in poultry, e.g. radiography (Poulos 1978), dual X-ray absorptometry (Hester et al. 2004), digital fluoroscopy (Fleming et al. 2004), quantitative computed tomography (Tatara et al. 2004, 2005), and microcomputed tomography microCT (Martinez-Cummer 2006). The programme which enables the determination of parameters of the bone structure through analysis of radiograms is the Trabecula[®] system (Czerwiński 1994). The method was used in the diagnostics of fluorine and osteopathic changes in humans (Czerwiński 1994), as well as in veterinary medicine: in horses to examine the structure of the pastern bones (Dzierżęcka 2006), in ostriches (Charuta et al. 2008) and in ducks (Charuta et al. 2011). The bone mineral density (BMD) and content (BMC), (Talaty et al. 2009, 2009a, 2010), and radiological density of bones (BRD) (Barreiro et al. 2009), were previously inves-

tigated. The aim of the current investigation was to determine changes in the bone mineral density BMD and BMC in the whole bones and in particular sections i.e. the proximal metaphysis and in the middle of the diaphysis of the tibiotarsal bones of ducks during postnatal development affected by age and sex using computed tomography and a densitometer. Hopefully, the attained results, despite their cognitive value, may also have a practical application as they may be used by poultry breeders.

Materials and Methods

The research was conducted on 100 Peking ducks (10 cocks and hens from each age group) obtained from France, Grimaud Freres Company (STAR 53 H.Y.: ♀GL30 X ♂GL50). For determining changes in the BMD and changes in the BMC in the bone tissue *in situ* in the postnatal development of the tibiotarsal bones, the birds were divided into age subgroups: 1-day-old (\bar{x} bw. 50.94 g), 2-wk-old (\bar{x} bw. 561.5 g), 4-wk-old (\bar{x} bw. 1750 g), 6-wk-old (\bar{x} bw. 2390 g), 8-wk-old (\bar{x} bw. 2910 g) – the age when they reach slaughtering maturity. The birds were fed *ad libitum* with industrial mixtures for water birds: KB₁ – all mash feed for ducks from the first days to the third week of life and KB₂ (a mixture for older ducks from the 3rd week of life till the end of fattening). Birds were kept in a closed building, on deep bedding. The first stage was to determine BMD and BMC in the whole tibiotarsal bones without dividing into particular sections (the proximal metaphyses and the middle of the diaphyses). The study was conducted applying a densitometer Norland – Excell Plus (Fort Atkinson WI, USA), which uses a technology of a collimated X-ray beam and a programme for animal research (Research Scan – version 3.9.6) at the following parameters:

1. Duck bones at 2, 4, 6 and 8 wk: scanning resolution – 1.5x1.5 and scanning speed – 30 mm/s.
2. Duck bones at 1 day: scanning resolution – 0.5 x 0.5 and scanning speed – 10 mm/s.

BMD- Bone Mineral Density – mineral density of the bone tissue expressed in g/cm²

BMC- Bone Mineral Content – mineral content of the bone tissue expressed in g

The research was conducted intravitaly.

Then, using a high resolution peripheral quantitative computed tomography (pQCT) XCT Research SA Plus (Stratec Medizintechnik GmbH, Pforzheim Germany), the analysis of *in situ* structure of the proximal metaphysis and the middle of the diaphysis of the tibiotarsal bones was conducted.

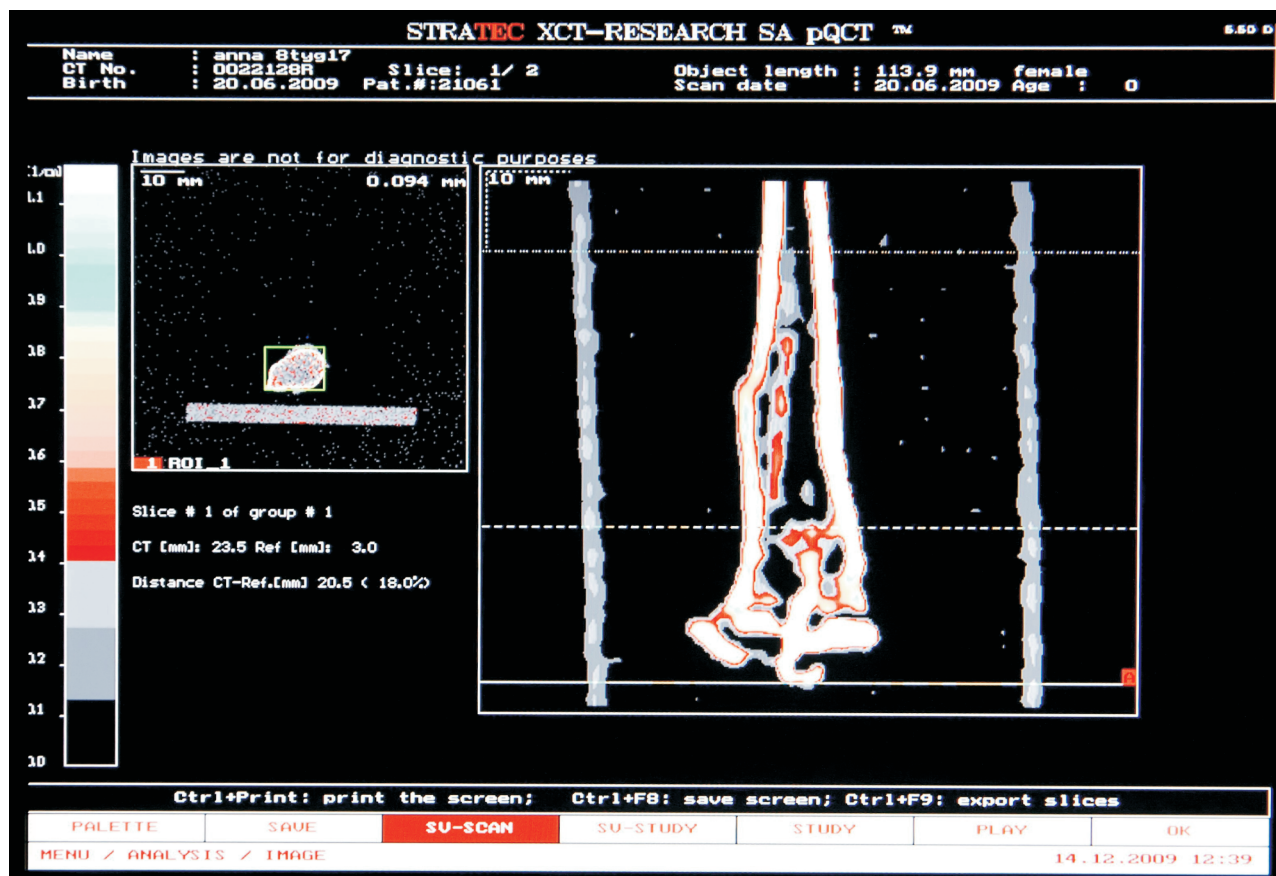


Fig. 1. Tomographical analysis of the proximal metaphysis and the middle of the diaphysis of a properly built tibiotarsal bone with marked places for analysis (18% of the length of the metaphysis and 50% of the length of the diaphysis of the tibiotarsal bone).

The following densitometric parameters were determined in the bones:

vBMD – The average volumetric bone mineral density in the proximal metaphyses and the middle of the diaphyses (mg/cm³).

BMC – The average mineral bone content in the proximal metaphyses and the middle of the diaphyses per 1mm slice (mg/mm). The mineral content of the total bone within a 1 mm slice (BMC).

The tibiotarsal bones were cleaned off the soft tissues for the analysis with the use of computed tomography and frozen for storing at -25 to -30°C.

Tomographic analysis of the proximal metaphysis was conducted in 18% of the bone length, whereas the analysis of the middle of the diaphysis of the tibiotarsal bone was performed in the middle (50%) of the bone length, at the voxel of 0.07 mm and the scanning speed of 4 mm/min. The area of the analysis was determined after the initial scanning (20 mm/s) and morphometric bone measurements (Fig. 1). The threshold coefficient, differentiating the compact bone from the cancellous bone, was determined and estimated at 0.900 cm⁻¹.

The achieved results were analysed statistically. The first stage of the analysis was to check the confor-

mance of the data with the normal distribution. Densitometric parameters (BMD and BMC) were compared and the ones which appeared not to be consistent with the normal distribution were analysed using non-parametric tests: i.e. the Kruskal-Wallis one-way analysis of variance (to compare age). Differences between particular parameters and the area of the studied bone are presented in the diagrams. The non-parametric U Mann-Whitney test was used to compare sexes. All calculations were conducted with the use of Statistica 9.0 programme (StatSoft, Inc. Tulsa, USA) at P ≤ 0.05. Two-factor analysis of variance ANOVA was applied to analyse densitometric results.

The following overall linear model for comparison of analysed traits was used:

$$y_{ijl} = m + a_i + b_j + ab_{ij} + e_{ijl}$$

where:

- y^{ij} – value of the studied feature,
- a_i – i-effect of factor A,
- b_j – j – effect of factor B,
- ab_{ij} – effect of interaction between A and B,
- e_{ijl} – random error.

Correlation coefficients for the analysed features were calculated in relation to the body weight and the bone weight (Table 5).

The research was conducted after achieving the acceptance of the Local Bioethical Committee (nr 55/2008) for the planned procedures on animals.

Results

Average values of the BMC and BMD of the tibiotarsal bones of ducks as influenced by age, sex and body weight with the use of a densitometer are presented in the table below.

When analysing the BMC in the tibiotarsal bones using a densitometer, it was observed that BMC of females increased from the moment of nesting till the slaughtering maturity. In a group of males, BMC increased from 1 day to 6 wk (Table 1). BMD in the postnatal development increased from the first day up to six wks, whereas in the group of females up to eight wks (Table 1).

Average BMC values in the bone tissue and vBMD *in situ* in particular bone sections as influenced by age, sex and body weight achieved using computed tomography are presented in the diagrams below. The tables show values of the Kruskal-Wallis test (H) and the U-Mann -Withney test (Z).

When analysing the mineral content BMC in the tibiotarsal bones, it was stated that

BMC was higher in the proximal metaphyses than in the middle of the diaphyses (Fig. 2). BMC in the proximal metaphyses of the tibiotarsal bones *in situ* was the highest in 4wk individuals of both sexes (app. 45 mg/mm). It is worth emphasising that a decrease of BMC was observed between 4 and 6 wk, both in males and females in proximal metaphyses. (Table 2, 3, 4).

In 6 wk females, BMC in proximal metaphyses attenuated by 16 mg/mm (Fig. 2). Pearson's correlation coefficient of 4 wk females amounted to $r = -0.53$, and in 6 wk to $r = -0.39$, at $P \leq 0.05$. It proved that when the body weight BW increased, the mineral content BMC significantly decreased in proximal metaphyses in 6 wk females (Table 5).

Table 1. Average values of the mineral content BMC and mineral density BMD of the tibiotarsal bones of ducks as influenced by age, sex and body weight.

Item	Age	Males	Females	Average
SDBW (g)	1 day	51.84 ^A ± 4.04	50.1 ^A ± 5.37	50.92 ^A ± 4.78
	2 wk	547.50 ^B ± 41.1	586.7 ^B ± 118.32	574.6 ^B ± 100.55
	4 wk	1912.00 ^C ± 133.1	1669.1 ^C ± 336.26	1745.0 ^C ± 305.98
	6 wk	2510.91 ^D ± 391.6	2382.5 ^D ± 344.99	2456.8 ^D ± 368.44
	8 wk	3184.00 ^E ± 192.5	2905 ^E ± 441.66	2987.1 ^E ± 400.68
	Average	1733.9 ^a ± 1205.8	1587.7 ^a ± 1128.6	
BMD (g/cm ²)	2 wk	0.11 ^B ± 0.008	0.10 ^B ± 0.01	0.10 ^B ± 0.01
	4 wk	0.21 ^C ± 0.01	0.18 ^C ± 0.02	0.19 ^C ± 0.02
	6 wk	0.22 ^C ± 0.04	0.18 ^C ± 0.01	0.21 ^C ± 0.04
	8 wk	0.20 ^C ± 0.01	0.19 ^C ± 0.01	0.20 ^C ± 0.01
	Average	0.17 ^B ± 0.08	0.14 ^A ± 0.07	
BMC (g)	1 day	0.01 ^{a,A} ± 0.002	0.01 ^{a,A} ± 0.004	0.01 ^{a,A} ± 0.003
	2 wk	0.97 ^{b,A} ± 0.19	0.79 ^{b,A} ± 0.21	0.84 ^{b,A} ± 0.21
	4 wk	3.11 ^{c,B} ± 0.41	2.46 ^{c,B} ± 0.61	2.67 ^{c,B} ± 0.62
	6 wk	3.81 ^{c,d,B} ± 1.29	2.79 ^{c,d,B} ± 0.39	3.47 ^{c,d,B} ± 1.17
	8 wk	3.62 ^{d,B} ± 0.312	3.24 ^{d,B} ± 0.59	3.33 ^{d,B} ± 0.55
	Average	2.67 ^B ± 1.77	2.02 ^A ± 1.32	

Statistically significant differences in columns, averages marked with different letters ^{a,b} significant at $P \leq 0.05$, ^{A,B} significant at $P \leq 0.01$.

Table 2. Values of the Kruskal-Wallis test comparing features influenced by age.

Item	Males		Females	
	Middle of the diaphysis	Proximal metaphysis	Middle of the diaphysis	Proximal metaphysis
BW	H = 29.10*	H = 21.08*	H = 42.75*	H = 8.67*
Weight of tibia	H = 24.78*	H = 12.29*	H = 35.59*	H = 5.36
BMC	H = 26.18*	H = 12.57*	H = 38.56*	H = 4.41
vBMD	H = 17.21*	H = 8.21	H = 22.28*	H = 0.02

* statistically significant differences at $P \leq 0.05$. BW – body weight changed with age.

Table 3. Values of the Mann-Whitney U test (the comparison between males and females).

“Sections within bones”	Age	BW(g)	Weight of tibio-tarsal (g)	BMC	vBMD
Proximal metaphysis	0 wk	Z = 0.25	Z = -0.36	Z = -0.27	Z = -0.26
	2 wk	Z = 0.16	Z = 0.19	Z = -0.17	Z = 0.17
	4 wk	Z = 1.01	Z = 1.69	Z = 0.60	Z = 0.84
	6 wk	Z = 0.26	Z = 2.19	Z = 1.64	Z = 0.47
	8 wk	Z = 1.68	Z = -0.28	Z = 1.58	Z = -0.73
Middle of the diaphysis	0 wk	Z = 0.24	Z = 0.56	Z = -0.24	Z = -0.48
	2 wk	Z = 1.25	Z = 1.12	Z = 1.34	Z = -0.24
	4 wk	Z = 1.02	Z = 1.17	Z = 1.24	Z = -0.56
	6 wk	Z = 0.63	Z = 1.00	Z = 2.03	Z = 0.45
	8 wk	Z = 0.88	Z = -0.63	Z = 1.88	Z = -0.12

* statistically significant differences at P ≤ 0.05. Analysed feature – BW – body weight, Weightof the tibio-tarsal bones, BMC, vBMD. The relation between males and females was not observed.

Table 4. Values of the Mann-Whitney U test, comparing differences between particular sections of bones for males and females.

Item	Age	Males	Females
BMC	1 day	Z = -1.07	–
	2 wk	Z = -2.44*	Z = -3.46*
	4 wk	Z = -2.44*	Z = -4.02*
	6 wk	Z = -3.19*	Z = -3.09*
	8 wk	Z = -2.23*	Z = -3.49*
vBMD	1 day	Z = 2.14*	–
	2 wk	Z = 2.44*	Z = 3.55*
	4 wk	Z = 2.44*	Z = 4.02*
	6 wk	Z = 3.62*	Z = 3.09*
	8 wk	Z = 1.93	Z = 4.26*

* differences at P ≤ 0.05.

Table 5. Pearson’s correlation coefficient for BMC and BMD as influenced by the body weight and the bone weight for particular “sections within bone” (proximal metaphysis and middle of the diaphysis).

	Age	BW	Bone weight	Age	BW	Bone weight
Males	Proximal metaphysis			Middle of the diaphysis		
BMC	1 day	–	–	1 day	–	–
	2wk	0.88*	0.06	2wk	0.91*	-0.15
	4wk	-0.52	-0.44	4wk	0.86*	0.85*
	6wk	0.32	0.44	6wk	0.01	-0.47
	8wk	-0.38	0.67*	8wk	-1.0	-1.0
vBMD	1 day	–	–	1 day	–	–
	2wk	-0.69	0.25	2wk	-0.07	0.66*
	4wk	-0.97*	-0.91*	4wk	0.42	-0.58
	6wk	0.52	-0.05	6wk	-0.72*	0.03
	8wk	-0.00	0.34	8wk	1.0	1.0
Females	Proximal metaphysis			Middle of the diaphysis		
BMC	1day	–	–	1 day	–	–
	2wk	0.36	0.27	2wk	0.91*	-0.15
	4wk	-0.53	0.78*	4wk	0.12	0.41
	6wk	-0.39	0.48	6wk	0.61*	0.25
	8wk	0.12	0.85*	8wk	-0.12	0.41
vBMD	1 day	–	–	1 day	–	–
	2wk	0.88*	-0.60*	2wk	-0.07	0.66*
	4wk	0.15	0.16	4wk	-0.63*	-0.40
	6wk	0.52	-0.45	6wk	-0.79*	-0.09
	8wk	0.85*	0.22	8wk	0.50	-0.40

* significant at P ≤ 0.05. BW body weight.

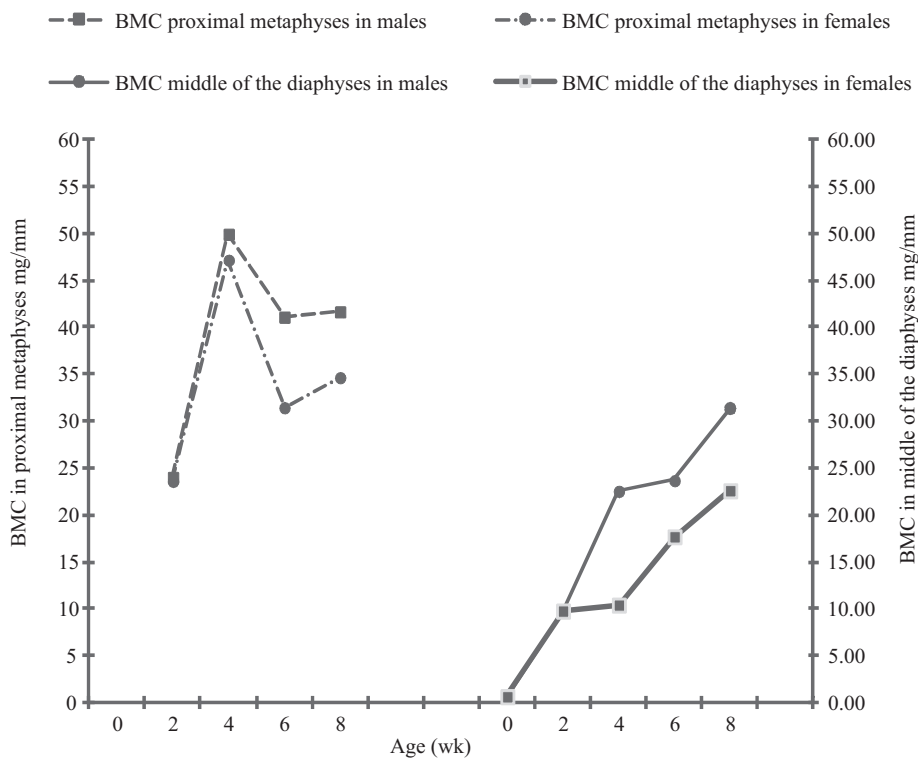


Fig. 2. Average bone mineral content (BMC) values in the proximal metaphyses and the middle of the diaphyses of the tibiotarsal bones of ducks as influenced by age and sex.

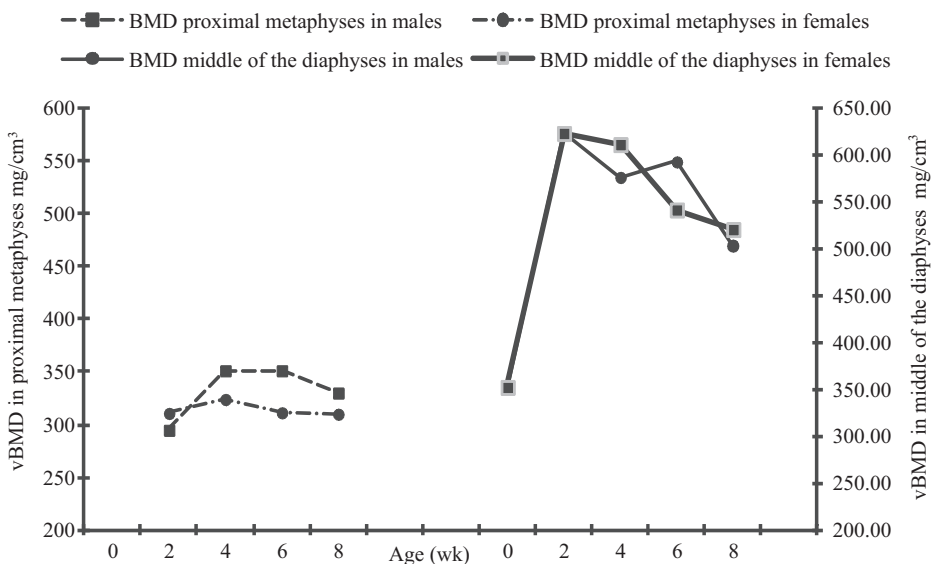


Fig. 3. Average bone mineral density (vBMD) values in the proximal metaphyses and the middle of the diaphyses of the tibiotarsal bones of ducks as influenced by age and sex.

The mineral content, BMC, in the middle of the diaphyses *in situ* increased with age for both sexes (Fig. 2). Pearson’s correlation coefficient confirmed statistically significant relations between the mineral content BMC and the body weight BW. The coefficient amounted to $r = 0.91$ and $r = 0.86$, $P \leq 0.05$ for 2 and 4 wk males, respectively. In the group of 2 and

6 wk females, significant statistical relations between BMC and BW were also observed.

In proximal metaphyses of the tibiotarsal bones of males and females, vBMD was twice lower than in the diaphyses and amounted to app. 300 mg/cm^3 in the proximal metaphyses and app. 600 mg/cm^3 in the middle of the diaphyses.

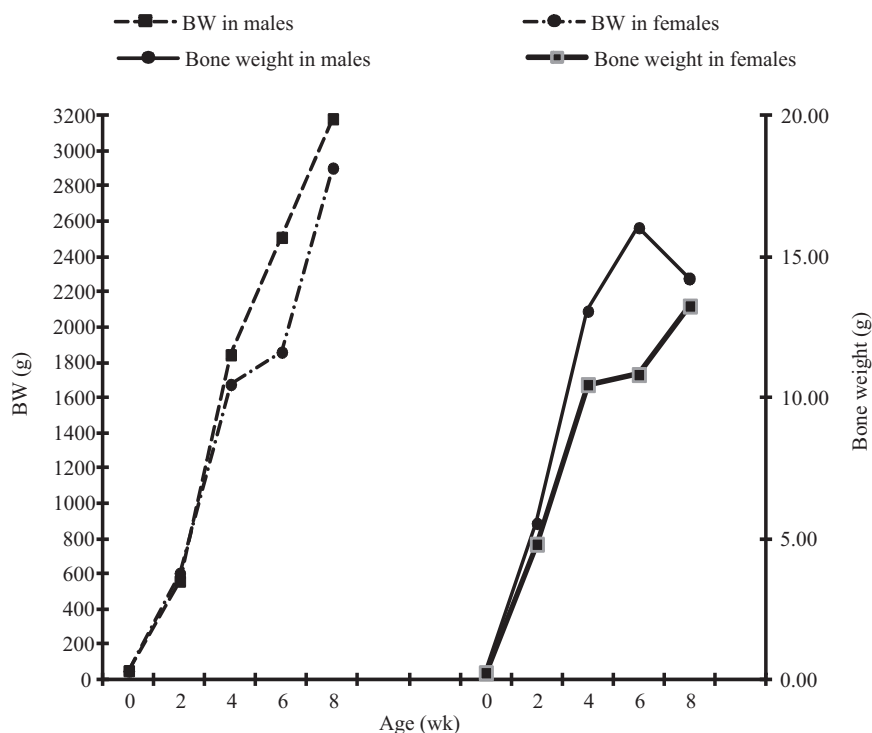


Fig. 4. Average values of the body weight (BW) and the bone weight as influenced by age and sex.

A decrease of vBMD was observed in both bone sections from 6 wk in both sexes. Fig. 3.

It is worth noting that the highest number of deformities of the tibial bones and movement problems was observed between 4 and 6 wk in females. Attenuation of bone mass was also found in males, however, it occurred a bit later, in the 6 wk (Fig. 3). It should be emphasised that an intense growth of the body weight of the studied birds took place between 2 and 6 wk (Fig. 4).

Using Pearson’s correlation coefficient, it was stated that it amounted to $r = -0.97$ in proximal metaphysis in 4 wk males and it proved that when the body weight BW increased, vBMD significantly decreased in proximal metaphyses. In 6 wk males, vBMD also decreased in the middle of diaphyses when BW increased ($r = -0.72$, at $P \leq 0.05$) (Table 5). The correlation coefficient in 4 and 6 wk females confirmed the decrease of vBMD in the middle of diaphyses when BW increased and it amounted to $r = -0.63$ and $r = -0.79$ at $P \leq 0.05$, respectively (Table 5).

Discussion

Deformities and fractures of the tibiotarsal bones are recorded in various species of poultry, especially of the meat-type birds, both in the *Galliformes* (Lilburn 1994, Simsa et al. 2007, Tykałowski et al. 2010)

and the *Anseriformes* (Charuta et al. 2011). Ducks of the meat type, growing fast between 4 and 6 wk, experience illnesses of the tibiotarsal bones and disorders in the bone formation processes as at that age there is a sudden rebuilding and modelling of the bone tissue (Charuta et al. 2011), whereas older birds experience fractures of long bones (own research). Taking into account the frequency of pathologies of the bone tissue in poultry, including ducks, conducting studies aiming at recognising disorders in the post-natal development of bones is justified.

The research of Charuta et al. (2011) reported changes in the structure of the spongy substance of the tibio-tarsal bones of domestic ducks using Trabecula® programme to examine the bone tissue. It showed that 6-wk.-old female ducks had the lowest number of trabeculae (8.14 mm²), thus the lowest density of trabeculisation (39.84%). At that age the frequency of deformities of the tibial bones is also the highest in 4- and 8-wk-old birds, which means that the process of modelling of the spongy bone tissue triggered by the increase of the body weight takes place. Comparing the parameters characterising radiological trabeculae in the proximal metaphysis of the tibiotarsal bone from the previous research with vBMD and BMC (pQCT) of the proximal metaphysis of the same bones, it can be stated that these values are also the lowest in 6-wk.-old hens and amount to 310 mg/cm³ and 30 mg/mm, respectively. Using computed tomography as a research method allowed to analyse the

vBMD and BMC in particular bone sections. vBMD in the diaphyses was twice higher than in the metaphyses. Moreover, it was stated that vBMD of the diaphyses attenuated from 2 wk for both sexes i.e. from 650 mg/cm³ to 500 mg/cm³ (8 wk). The vBMD decrease may be the cause of deformities and fractures of bones in ducks. It was found that building of the bone mass took place from 1 day until 4 wk of the birds' life. In 4 wk vBMD and BMC of hens had the highest values. Similar relations were recorded in the number and the density of the radiological trabeculae, i.e. the number (12.47 mm²) and the density (47.71%) of the trabeculae was the highest in the hens in the 4 wk of life (Charuta et al. 2011). Another investigation conducted by Talaty (Talaty et al. 2009, Talaty et al. 2010) on the bone density of poultry related to age and sex analysed changes in the mineralisation of the humeral and tibial bones of chicken broilers, cocks and hens, aged 2-8 wk, using dual X-ray absorptometry (DEXA). They found that the bone mineral density was highest in 4-wk-old chicken broilers and slightly higher in cocks (Talaty et al. 2009). Similar results were observed in ducks (own research). The mineral content and the mineral density of the proximal metaphysis was the highest in 4 wk of life and slightly higher in cocks. The mineral density in the middle of the diaphysis was the highest in 2-wk-old birds (males and females). Barreiro et al. (2009) studied the radiological density of the tibial bones of broilers (BRD) in the proximal metaphysis, the diaphysis and the distal metaphysis of bones. It was stated that proximal metaphyses of the tibial bones had the highest density compared with the diaphysis and the distal end of the bone. Ducks (own research) had the highest mineral density vBMD in the diaphysis of bones (600 mg/cm³), in the proximal metaphyses the bone weight was almost twice lower and amounted to 350 mg/cm³. The BMD and the BMC in the bone tissue in selected bones of the thoracic and pelvic limbs were analysed also in ostriches (Dzierżęcka & Charuta 2010). The research was conducted with the use of a densitometer. It was found that analysed bones differed significantly with regard to BMD and BMC in the bone tissue. Significantly higher values of both analysed parameters (BMD and BMC) were observed in bones of the pelvic limb in comparison with bones of the thoracic limb.

Conclusion

The presented research showed that BMC decreased in proximal metaphyses of the tibiotarsal bones in males and females between 4 and 6 wk. vBMD attenuated in diaphyses of the tibial bones in

females from 4 wk and in males from 6 wk. The changes in BMC and vBMD were the reason for numerous fractures and deformities of the tibial bones in 6 week-old ducks.

Our results suggest that the analysis of the BMD, vBMD and the BMC in postnatal development of the tibiotarsal bones of ducks using a densitometer and computed tomography may be a relatively new method applied in the early diagnostics of bone mineralisation disorders in ducks bred in flocks which is especially significant for the well-being of animals and may contribute to health improvement of duck flocks.

References

- Barreiro FR, Sagula AL, Junqueira OM, Pereira GT, Baraldi-Artoni SM (2009) Densitometric and biochemical values of broiler tibias at different ages. *Poult Sci* 88: 2644-2648.
- Bezuidenhout A, Burger WP (1993) The incidence of tibiotarsal rotation in the ostrich (*Struthio camelus*). *J S Afr Vet Assoc* 64: 159-161.
- Burs M, Zdybel A, Faruga A, Laskowski J (2008) Effect of housing conditions on the mechanical strength of the femur and tibia in turkeys. *Med Weter* 64: 202-206.
- Charuta A, Cooper RG, Pierzchała M, Horbańczuk JO (2012) Computed tomographic analysis of tibiotarsal bone mineral density and content in turkeys as influenced by age and sex. *Czech J Anim Sci*. In press.
- Charuta A, Dzierżęcka M, Czerwiński E, Cooper RG, Horbańczuk JO (2012) Analysis of differences in the structure of the spongy substance of the tibiotarsal bone in domestic goose (*Anser domesticus*) as influenced by age and sex. *Folia Biol-Kraków*. In Press.
- Charuta A, Dzierżęcka M, Majchrzak T, Czerwiński E, Cooper RG (2011) Computer-generated radiological imagery of the structure of the spongy substance in the postnatal development of the tibiotarsal bones of the Peking domestic duck (*Anas platyrhynchos var. domestica*). *Poult Sci* 90: 830-835.
- Charuta A, Majchrzak T, Czerwiński E, Cooper RG (2008) Spongy matrix of the tibio-tarsal bone of ostriches (*Struthio camelus*) – a digital analysis. *Bull Vet Inst Pulawy* 52: 285-289.
- Coelho HE, Eurides D, Diniz JM (1997) Tibial dyschondroplasia in broilers of the Hubbard-Peterson line. *Vet Not* 3:61-65.
- Cooper RG, Horbańczuk JO, Naranowicz H, Maliszewska E (2010) Unilateral tibio-tarsal rotation in a 14-month old ostrich hen destined for slaughter. *Tanz Vet J* 27: 11-13.
- Cooper RG, Naranowicz H, Maliszewska E, Tennett A, Horbańczuk JO (2008a) Sex-based comparison of limb segmentation in ostriches aged 14 months with and without tibiotarsal rotation. *Journal of the South African Veterinary Association* 79: 142-144.
- Czerwiński E (1994) Quantitative evaluation of changes occurring in the spongy cortical bone influenced by fluorine and their diagnostics meaning. Habilitation thesis, Collegium Medicum UJ, Kraków.

- Dzierżęcka M, Charuta A (2006) Modern methods in the evaluation of bone tissue quality and the possibility of their application in veterinary medicine. *Med Weter* 62: 617-620.
- Dzierżęcka M, Charuta A (2010) Influence of sex on bone mineral density and content of the skeleton of the thoracic and pelvic limb in the ostrich – *struthio camelus var. domesticus*. *Bull Vet Inst Pulawy* 54: 601-604.
- Fleming RH, Korver D, McCormack HA, Whitehead CC (2004) Assessing bone mineral density in vivo: digitized fluoroscopy and ultrasound. *Poult Sci* 83: 207-214.
- Hester PY, Schreiweis MA, Orban JI, Mazzuco H, Kopka MN, Ledur MC, Moody DE (2004) Assessing bone mineral density in vivo: dual energy X-ray absorptiometry. *Poult Sci* 83: 215-221.
- Horbańczuk JO, Parada R, Huchzermeyer FW, Płaza K (2004) Four-legged ostrich (*Struthio camelus*) chick. *Vet Rec* 154: 736.
- Lilburn MS (1994) Skeletal growth of commercial poultry species. *Poult Sci* 73: 897-903.
- Martinez-Cummer MA, Heck R, Leeson S (2006) Use of axial X-ray microcomputed tomography to assess three-dimensional trabecular microarchitecture and bone mineral density in single comb white leghorn hens. *Poult Sci* 85: 706-711.
- Poulos PW Jr (1978) Tibial dyschondroplasia (osteochondrosis) in the turkey. A morphologic investigation. *Acta Radiol* 358: 197-227.
- Simsa S, Hasdai A, Dan H, Ornan EM (2007) Induction of tibial dyschondroplasia in turkeys by tetramethylthiuram disulfide (thiram). *Poult Sci* 86: 1766-1771.
- Talaty PN, Katanbaf MN, Hester PY (2009) Life cycle changes in bone mineralization and bone size traits of commercial broilers. *Poult Sci* 88: 1070-1077.
- Talaty PN, Katanbaf MN, Hester PY (2009a) Variability in bone mineralization among purebred lines of meat-type chickens. *Poult Sci* 88: 1963-1974.
- Talaty PN, Katanbaf MN, Hester PY (2010) Bone mineralization in male commercial broilers and its relationship to gait score. *Poult Sci* 89: 342-348.
- Tatara MR, Pierzynowski SG, Majcher P, Krupski W, Brodzki A, Studziński T (2004) Effect of alpha-ketoglutarate (AKG) on mineralisation, morphology and mechanical endurance of femur and tibia in turkey. *Bull Vet Inst Pulawy* 48: 305-309.
- Tatara MR, Sierant-Roźmiej N, Krupski W, Majcher P, Śliwa E, Kowalik S, Studziński T (2005) Quantitative computed tomography for the assessment of mineralization of the femur and tibia in turkeys. *Med Weter* 61: 225-228.
- Tykałowski B, Stenzel T, Koncicki A (2010) Selected problems related to ossification processes and their disorders in Bird. *Med Weter* 66: 464-469.