

P.Ch. KONTUREK\*, S.J. KONTUREK, A. BOBRZYŃSKI, N. KWIECIEN,  
W. OBTUŁOWICZ, J. STACHURA, E.G. HAHN\*  
K. REMBIARZ

## HELICOBACTER PYLORI AND IMPAIRED GASTRIC SECRETORY FUNCTIONS ASSOCIATED WITH DUODENAL ULCER AND ATROPHIC GASTRITIS

Institute of Physiology, Jagiellonian University School of Medicine, Cracow, Poland and

\*Department of Internal Medicine, Erlangen-Nurnberg University, Erlangen, Germany

Previous study showed that duodenal ulcer (DU) patients infected with *Helicobacter pylori* (*H. pylori*) have increased basal and pentagastrin- or GRP-induced gastric acid secretion and that these disturbances reversed fully after eradication of *H. pylori*. This study was designed to compare the gastric acid secretory profile, plasma gastrin levels and growth factors (EGF and TGF $\alpha$ ) expression in gastric mucosa in DU patients with those in atrophic gastritis patients before and six months after verified eradication of *H. pylori*. In DU patients, basal and stimulated (GRP and pentagastrin) gastric acid secretion was significantly higher than in healthy controls. Six months following the eradication of *H. pylori* with triple therapy (omeprazole + clarithromycin + amoxicillin), this secretion returned to normal value. In contrast, in patients with atrophic gastritis, such eradication of *H. pylori* resulted in a significant increase in basal and pentagastrin- and GRP-stimulated acid secretion. Mucosal expression of immunoreactive EGF and TGF $\alpha$  was significantly enhanced in *H. pylori* positive DU and atrophic gastritis patients but this elevation disappeared or was markedly decreased 6 months upon the eradication of *H. pylori*. We conclude that 1) *H. pylori* infection is accompanied both in DU and atrophic gastritis patients by an enhanced plasma gastrin and increased mucosal expression of EGF and TGF $\alpha$ , 2) basal and GRP-induced acid secretion is significantly elevated in DU, whereas that in atrophic gastritis patients is greatly reduced, and 3) the *H. pylori* eradication restores gastric acid and plasma gastrin release as well as the mucosal expression of growth factors in DU and atrophic gastritis.

Key words: duodenal ulcer, atrophic gastritis, gastrin, gastric acid, EGF, TGF $\alpha$

### INTRODUCTION

It is now well established that *H. pylori* is the major risk factor in the pathogenesis of duodenal ulcer (DU) and that more than 95% of patients with DU exhibit the *H. pylori* infection. Furthermore, eradication of *H. pylori*

---

Presented at the Second International Symposium "Helicobacter pylori infection and gastric pathology", Cracow, April 25—26, 1997.

markedly decreases the ulcer relapse rate (1—3). The mechanism of the predisposition of the *H. pylori* infected gastroduodenal mucosa to ulceration has not been explained but several studies showed that DU patients with *H. pylori* infection exhibit an increased basal and meal- or gastrin releasing peptide-induced gastric acid secretion and plasma gastrin concentrations (4—8). This increase, in plasma gastrin was probably due to the impaired feedback control of the release of this hormone due to the deficiency of its paracrine suppression by somatostatin (9, 10).

Epidermal growth factor (EGF) that originates mainly from the salivary secretion (11, 12) and transforming growth factor alpha (TGF $\alpha$ ), that is produced by the gastric mucosa (13), are potent inhibitors of gastric acid secretion and promoters of mucosal proliferation, growth, repair and ulcer healing (14). We found recently (15) that *H. pylori* infection is accompanied by enhanced expression of EGF and TGF $\alpha$  and that immediately after the *H. pylori* eradication there is further increase in mucosal content and luminal release of EGF and TGF $\alpha$  suggesting that these growth factors may contribute to ulcer healing following eradication of *H. pylori*.

*H. pylori* is the cause of (type B) chronic gastritis and has been shown in epidemiological studies to be the major risk factor in the development of gastric cancer (16, 17). It was found that mucosal cell proliferation was increased in *H. pylori* associated chronic atrophic gastritis and following successful *H. pylori* eradication there was a marked fall of mucosal cell proliferation (18).

The aims of the present study were to compare the gastric secretory profile and the mucosal expression of EGF and TGF $\alpha$  before and after eradication of *H. pylori* in patients with DU and atrophic gastritis.

## METHODS

Patients undergoing routine diagnostic endoscopy were recruited after informed consent. Those taking non-steroidal anti-inflammatory drugs, H<sub>2</sub>-antagonists, proton pump inhibitors or bismuth salts and these who undergone gastric surgery, were excluded from the study. Using standard biopsy forceps, tissue specimens from each site of gastric corpus and antrum were routinely processed, and stained with hematoxylin and eosin.

### *Subjects studied*

Ten *H. pylori*-negative male healthy subjects aging 20—40 years (group A) without any endoscopic and histological findings were included. Twenty *H. pylori*-positive patients with active DU disease and chronic superficial gastritis (group B) and ten *H. pylori*-positive patients with dyspeptic symptoms (group C) and the presence of mucosal atrophy in the corpus and antrum of the stomach were selected for the study. The three groups were matched for age and sex. *H. pylori* infection was confirmed by antral biopsy rapid urease test (CLO test) and by <sup>13</sup>C urea breath test.

For the eradication of *H. pylori*, one week triple therapy including omeprazole 20 mg bd, clarithromycin 500 mg bd and amoxicillin 500 mg bd was used. The eradication of *H. pylori* was confirmed by urea breath test one month later.

## STUDY DESIGN

### *Assessment of gastric acid secretion and plasma gastrin*

Plasma gastrin concentration and gastric acid outputs were examined after an overnight fast under basal conditions for 60 min and then in response to i.v. infusion of gastrin releasing peptide (GRP) at 0.1 µg/kg-h for 60 min followed by 60 min i.v. infusion of pentagastrin (2.0 µg/kg-h). The gastric juice was collected in four 15-min aliquots and analyzed for acid concentration and acid output was expressed in mmoles per hour (mmol/h).

Plasma gastrin was determined by radioimmunoassay under basal state (just before infusion of GRP) and during GRP administration using antiserum 4562 (kindly donated by Professor J.E. Rehfeld, Aarhus, Denmark) as described previously (10).

### *Immunohistochemistry*

During endoscopy, at least six biopsy samples were taken from the fundic mucosa for the immunocytochemical detection of EGF and TGFα. The samples were fixed in buffered formalin and then serial sections obtained from the paraffin blocks were dewaxed, rehydrated, pretreated with citrate buffer (pH 6.0) in microwave Oven at 700 watts for 10 min and incubated with specific monoclonal antibody for EGF (1/40; GF 0.1, Oncogen Sci., New York, USA) and for TGFα (1/20, G10, Oncogen Sci., New York, USA) followed by ABC method (ABC kit, Oncogen, New York, USA). The cytoplasm staining reactions were graded in accordance to the intensity of staining by examining 100 consecutive cells in three regions of the gastric mucosa, the surface epithelium, the neck region and the basal portion of gastric glands as described before (15). The intensity of staining was graded as follows: 0 — no staining, 1+ — weakly staining, 2+ — moderately positive staining and 3+ — densely staining, equal to the simultaneously stained positive control. Negative control sections were processed immunohistochemically after replacing the primary antibody with irrelevant monoclonal antibody or PBS. Positive control sections were obtained from pancreatic carcinoma (TGFα) and submandibular salivary gland (EGF) showing maximal labeling with the appropriate antibody.

### *Statistics*

All data are means and standard deviations. The Wilcoxon signed rank test was used with paired data and the Mann-Whitney U test with unpaired data. A P value less than 0.05 was considered significant.

## RESULTS

### *Effects of H. pylori eradication on gastric acid secretion and plasma gastrin level*

In healthy *H. pylori*-negative subjects basal acid output averaged  $2.3 \pm 0.7$  mmol/h (Fig. 1). Following GRP infusion, acid output rose to about  $16 \pm 3$  mmol/h and after pentagastrin stimulation, it reached maximum of about  $27 \pm 4$  mmol/h. In DU patients with *H. pylori* infection basal acid output

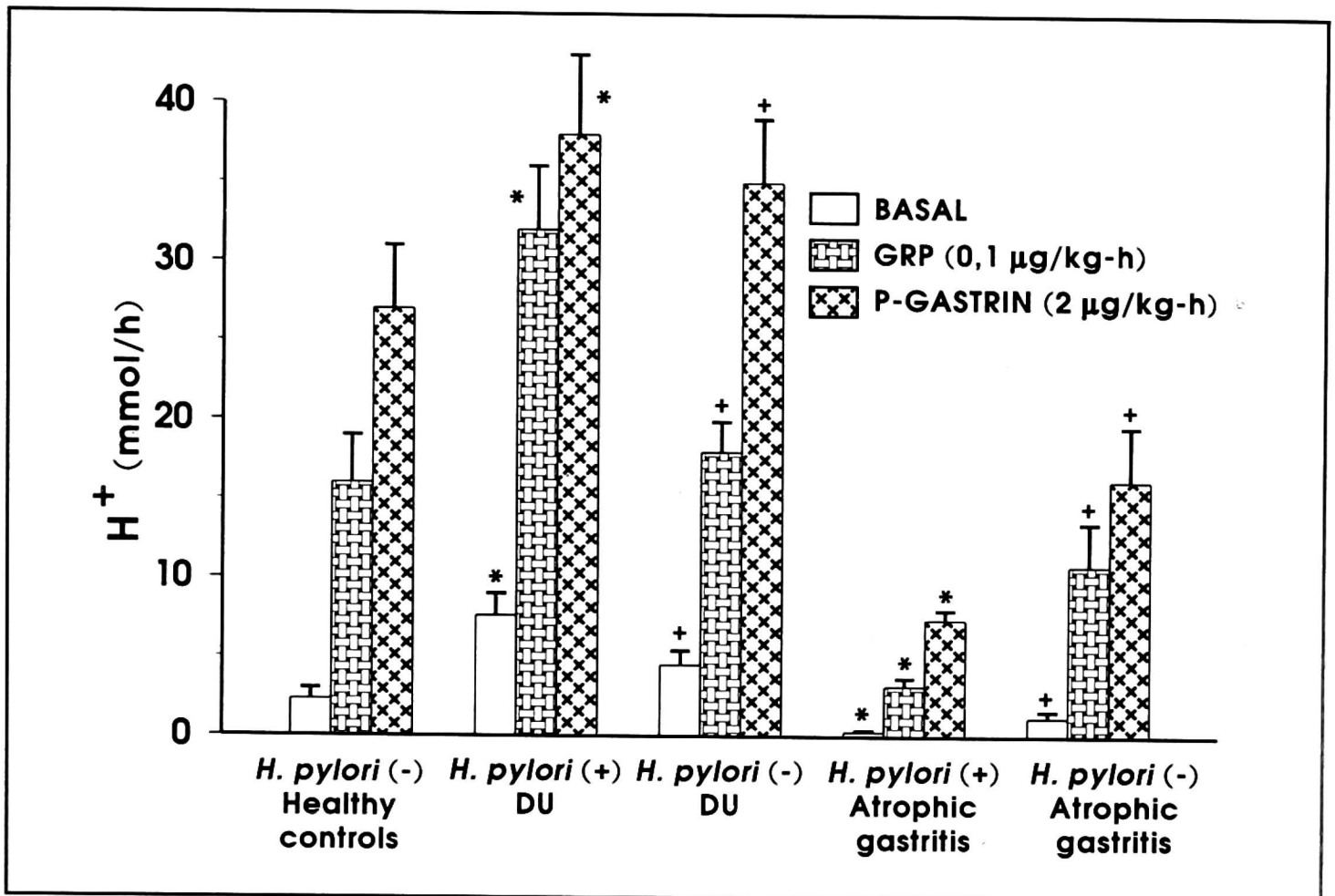


Fig. 1. Gastric acid output under basal conditions and following GRP (0.1 µg/kg-h i.v.) and then pentagastrin (2 µg/kg-h i.v.) stimulation in healthy subjects, in duodenal ulcer (DU) patients and atrophic patients before and 6 months after eradication of *H. pylori*. Asterisk indicates significant increase above the value obtained in healthy controls. Cross indicates significant decrease below the value obtained in the same patients before eradication of *H. pylori*.

was significantly higher than in healthy controls, averaging  $7.6 \pm 1.4$  mmol/h. Following GRP and pentagastrin infusion acid secretion rose significantly to about  $32 \pm 4$  and  $38 \pm 5$  mmol/h, respectively. No significant difference in the maximal acid outputs between GRP and pentagastrin stimulation was observed in *H. pylori*-positive DUs. Six months after eradication of *H. pylori*, basal acid output was significantly reduced to about  $4.5 \pm 0.9$  mmol/h, GRP-induced acid output was also significantly lowered to  $18 \pm 1.9$  mmol/h, while that stimulated by pentagastrin tended to decline (to about  $35 \pm 4$  mmol/h), but this fall did not reach statistical significance as compared to the pre-eradication value.

In atrophic gastritis patients with *H. pylori* infection, basal acid output was absent or negligible and there was only a small increase in acid output to about  $3.2 \pm 0.5$  mmol/h after GRP infusion and to about  $7.4 \pm 0.6$  mmol/h after pentagastrin infusion. Following the eradication of *H. pylori*, basal acid output rose significantly to about  $1.2 \pm 0.4$  mmol/h and acid responses to GRP and pentagastrin increased significantly to  $10.8 \pm 2.7$  and  $16.2 \pm 3.4$  mmol/h, respectively.

Basal plasma gastrin concentration in healthy *H. pylori*-negative subjects averaged  $25 \pm 4$  pM/L and it rose to about 75 pM/L following GRP infusion (Fig. 2). In DUs with *H. pylori* infection, basal plasma gastrin was about 3 times higher ( $72 \pm 10$  pM/L) than that in healthy controls and it rose to about  $210 \pm 32$  pM/L after infusion of GRP. After the *H. pylori* eradication, basal gastrin was reduced to the value ( $28 \pm 4$  pM/L) not significantly different from that observed in healthy subjects. Also the gastrin response to GRP infusion in these DUs returned to the value not significantly different from that in healthy controls ( $92 \pm 12$  pM/L).

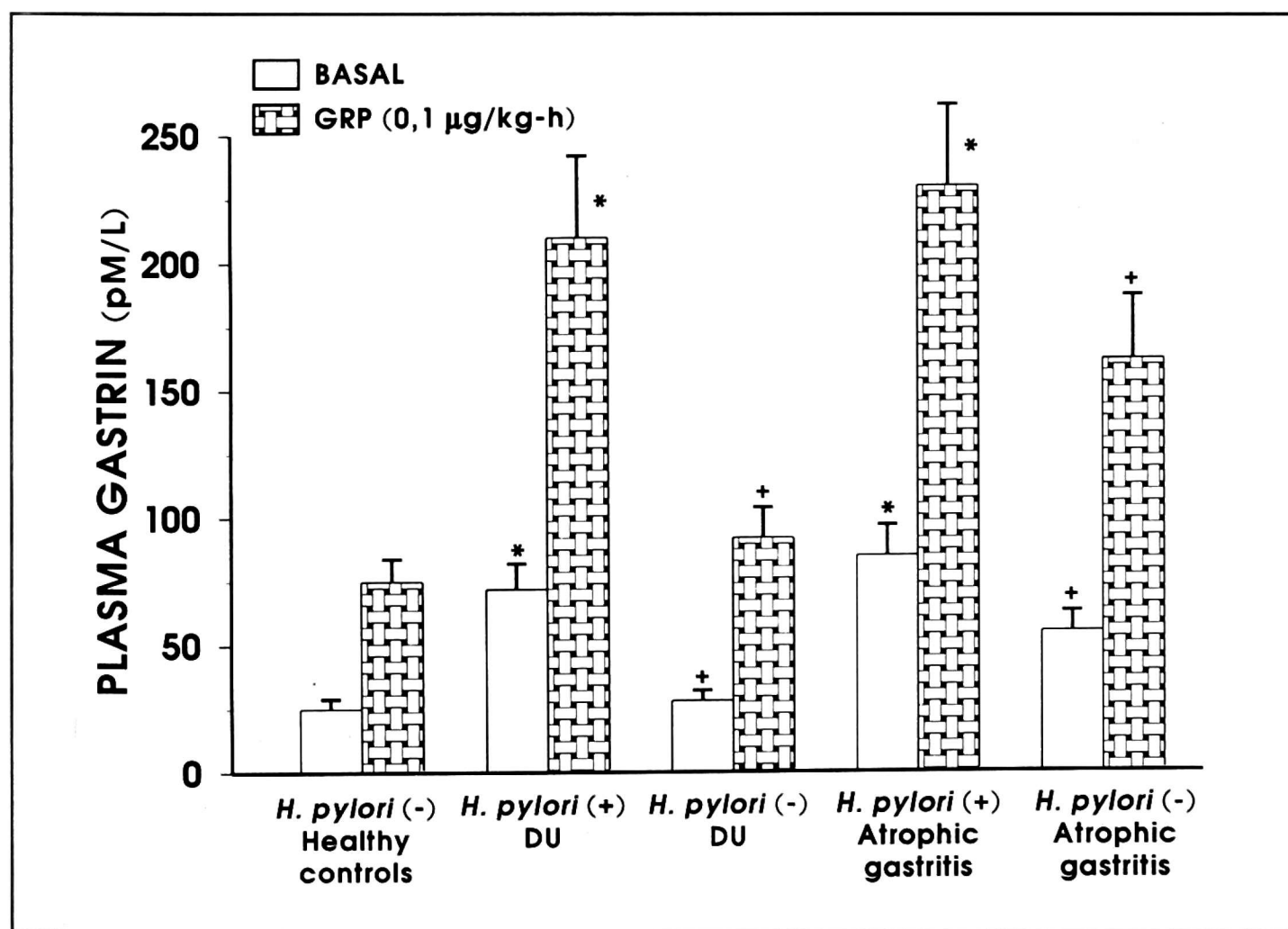


Fig. 2. Basal and GRP-stimulated plasma gastrin concentrations in healthy subjects and in DU patients and atrophic gastritis patients before (*H. pylori*+) and after eradication of *H. pylori* (*H. pylori*-). Asterisk indicates significant increase above the value obtained in healthy controls. Cross indicates significant decrease below the value obtained in the same patients before eradication of *H. pylori*.

Patients with atrophic gastritis and *H. pylori* infection showed significantly elevated basal ( $85 \pm 12$  pM/L) and GRP-induced plasma gastrin ( $230 \pm 32$  pM/L). After the eradication of *H. pylori*, both basal and GRP-induced plasma gastrin levels were significantly reduced but remained higher than those observed in healthy controls.

*Effect of H. pylori eradication on mucosal expression of EGF and TGF in gastric mucosa*

In healthy subjects, there was only a negligible EGF immunoreactivity localized mainly in the lumen of gastric glands (Fig. 3). The TGF $\alpha$  immunoreactivity was more prominent and confined mainly to the surface epithelial cells and parietal cells.

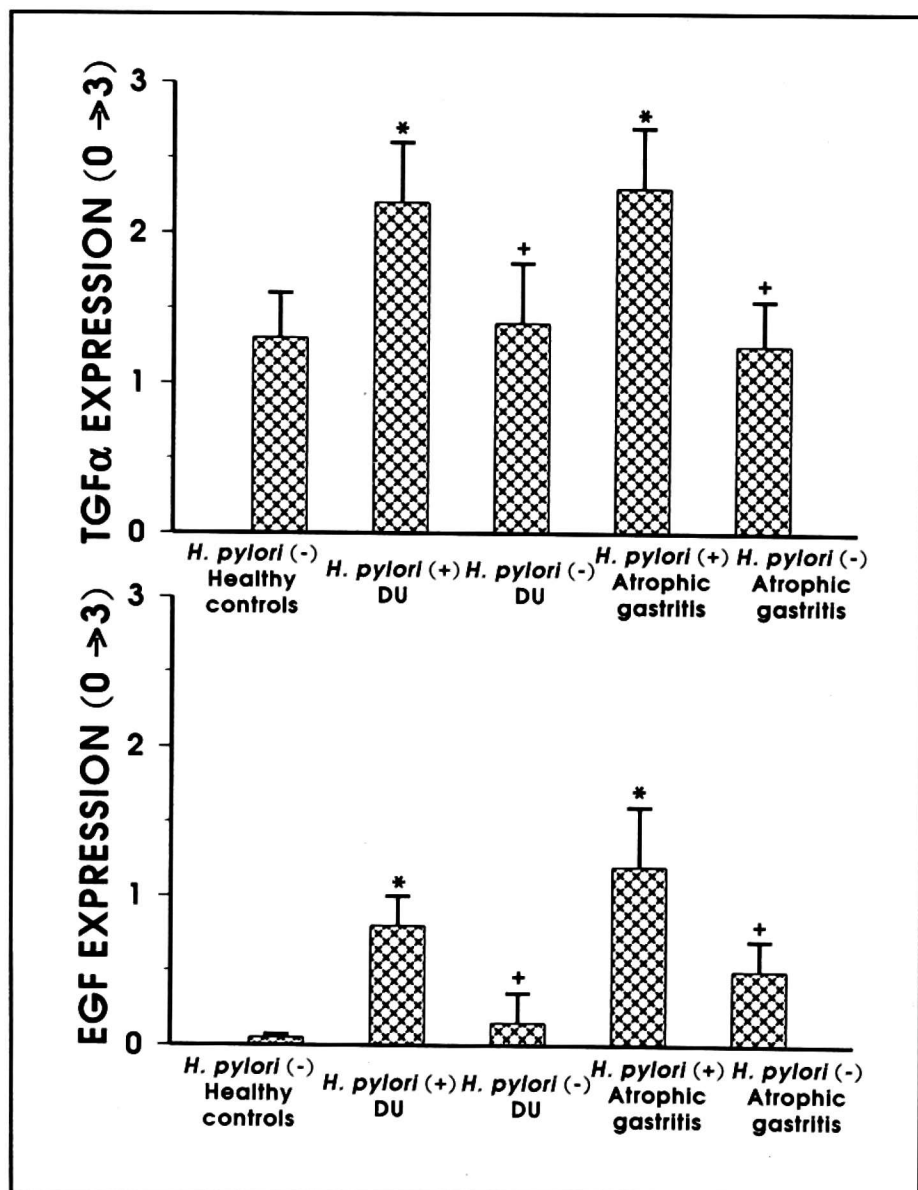


Fig. 3. Immunostaining for TGF $\alpha$  and EGF in antral biopsy samples in healthy controls and in DU and atrophic gastritis patients before (*H. pylori*+) and after six months after eradication of *H. pylori* (*H. pylori*-). Asterisk indicates significant increase above the value obtained in healthy controls. Cross indicates significant decrease below the value obtained in the same patients before eradication of *H. pylori*.

In *H. pylori* infected DUs, the EGF immunoreactivity was several folds higher and TGF $\alpha$  immunoreactivity was about 60% higher than that in *H. pylori* negative healthy subjects. Following the eradication of *H. pylori*, the EGF and TGF $\alpha$  expression was significantly reduced as compared to that observed in the same subjects before the eradication of *H. pylori*.

In patients with atrophic gastritis and *H. pylori* infection, the mucosal EGF immunoreactivity also increased by several folds, while the TGF $\alpha$  rose by about 80% as compared to healthy controls. This elevated EGF and TGF $\alpha$  immunoreactivity significantly declined six months after the eradication of *H. pylori* but it remained significantly higher than in the mucosa of *H. pylori* negative healthy subjects.

## DISCUSSION

This study demonstrates that *H. pylori* infected stomach in DU disease is capable of expressing EGF and shows augmented expression of TGF $\alpha$  as compared to healthy non-infected controls and that 6 months following eradication of *H. pylori* in these DU patients there is almost complete disappearance of EGF and a marked decrease of TGF $\alpha$ -immunostaining. Since EGF and TGF are potent mitogens for epithelial cells both *in vitro* and *in vivo*, it is reasonable to assume that overexpression of these growth factors could contribute to the increase in the mucosal cell proliferation observed in *H. pylori*-infected stomach (18—20). This increased epithelial cell proliferation observed during the long-term *H. pylori* infection such as occurs in atrophic gastritis could serve as an indicator of the risk for the gastric cancer.

Additional factor that could explain increased cell turnover and mucosal proliferation induced by *H. pylori* infection might be a marked increase in basal and GRP-induced plasma gastrin level resulting most probably from the reduced paracrine release of somatostatin (10, 21).

It is of interest that unlike DU patients with *H. pylori* infection showing enhanced basal and GRP-induced gastric secretion, patients with atrophic gastritis and *H. pylori* infection show negligible basal acid secretion and markedly reduced acid response to maximal stimulation by pentagastrin or GRP. These secretory responses to pentagastrin or GRP were much below the value observed in healthy controls. This hyposecretion occurred despite the fact that both basal and GRP-induced plasma gastrin levels were several times higher than those in healthy controls. The major finding of this study is that following the eradication of *H. pylori* there was a partial restoration of gastric acid secretion suggesting that the suppression of acid secretion is due to *H. pylori* infection itself.

Studies on *H. pylori*-infected patients with atrophic gastritis who develop chronic acid hyposecretion despite the increased plasma gastrin level may explain the link between the *H. pylori* infection and gastric cancer. Such hypoacidity might allow overgrowth of the stomach with mixed bacterial flora capable of producing nitrosoamines that may damage epithelial cell DNA. This could result in the development of atrophy, intestinal metaplasia, dysplasia and finally cancer. Eradication of *H. pylori* and restoration, at least in part, of the acid secretory activity could prevent the progression of atrophic gastritis to gastric cancer (22).

## REFERENCES

1. Marshall BJ, Goodwin CS, Warren JR *et al.* Prospective double-blind trial of duodenal ulcer relapse after eradication of *Campylobacter pylori*. *Lancet* 1988; 2: 1237—1441.
2. Rauws EAJ, Tytgat GNJ. Cure of duodenal ulcer associated with eradication of *Helicobacter pylori*. *Lancet* 1990; 335: 1233—1235.

3. Hentschel E, Brandstatter G, Dragosics B *et al.* Effect of ranitidine and amoxicillin plus metronidazole on the eradication of *Helicobacter pylori* and the recurrence of duodenal ulcer. *N Engl J Med* 1993; 328: 308—312.
4. McColl KEL, Fullarton GM, Chittajallu R *et al.* Plasma gastrin, daytime intragastric pH, and nocturnal acid output before and at 1 and 7 months after eradication of *Helicobacter pylori* in duodenal ulcer subjects. *Scand J Gastroenterol* 1991; 26: 339—346.
5. Prewett EJ, Smith JTL, Nwokolo CU, Hudson M, Sawyer AM, Pounder RE. Eradication of *Helicobacter pylori* abolishes 24-hour hypergastrinemia: a prospective study in healthy subjects. *Aliment Pharmacol Ther* 1991; 5: 283—290.
6. Levi S, Beardshall K, Swift I *et al.* Antral *Helicobacter pylori*, hypergastrinaemia and duodenal ulcers: effect of eradicating the organism. *BMJ* 1989; 299: 1504—1505.
7. Graham DY, Opekun A, Lew GM, Evans DJ, Klein PD, Evans DG. Ablation of exaggerated meal-stimulated gastrin release in duodenal ulcer patients after clearance of *Helicobacter (Campylobacter) pylori* infection. *Am J Gastroenterol* 1990; 85: 394—398.
8. El-Omar EM, Penman ID, Ardill JES, Chittajally RS, Howie C, McColl KEL. *Helicobacter pylori* infection and abnormalities of acid secretion in patients with duodenal ulcer disease. *Gastroenterology* 1995; 109: 681—691.
9. Levi S, Haddad G, Ghosh P, Beardshall K, Playford R, Calam J. *Campylobacter pylori* and duodenal ulcer: the gastrin link. *Lancet* 1989; 1: 1167—1168.
10. Konturek JW, Bielański W, Konturek SJ, Domschke W. Eradication of *Helicobacter pylori* and gastrin-somatostatin link in duodenal ulcer patients. *J Physiol Pharmacol* 1996; 47: 161—175.
11. Gregory H. Isolation and structure of urogastrone and its relationship to epidermal growth factor. *Nature* 1975; 257: 325—327.
12. Konturek JW, Bielański W, Konturek SJ, Bogdał J, Oleksy J. Distribution and release of epidermal growth factor in man. *Gut* 1989; 30: 1194—1200.
13. Polk WH, Dempsey PJ, Russel WE *et al.* Increased production of transforming growth factor alpha following acute gastric injury. *Gastroenterology* 1992; 102: 1467—1474.
14. Barnard JA, Beauchamp RD, Russell WE, Dubois RN, Coffey RJ. Epidermal growth factor — related peptides and their relevance to gastrointestinal pathophysiology. *Gastroenterology* 1995; 108: 564—580.
15. Konturek PC, Ernst H, Konturek SJ, Hahn EG. Mucosal expression and luminal release of epidermal growth factor and transforming growth factor in duodenal ulcer patients before and after eradication of *Helicobacter pylori*. *Gut* 1997; 40: 463—469.
16. Nomura A, Stemmermann GN, Chyou P, Kato I, Perez-Perez GI, Blaser MJ. *Helicobacter pylori* infection and gastric carcinoma among Japanese Americans in Hawaii. *N J E Med* 1991; 325: 1132—1136.
17. Forman D, Newell DG, Fullerton F *et al.* Association between infection with *Helicobacter pylori* and risk of gastric cancer: evidence from a prospective investigation. *BMJ* 1991; 302: 1302—1305.
18. Lynch DAF, Mapstone NP, Clarke AMT *et al.* Cell proliferation in *Helicobacter pylori* associated gastritis and the affect of eradication therapy. *Gut* 1995; 36: 346—350.
19. Caghill RJ, Xia H, Kilgallen C, Beattle S, Hamilton S, O'Marion C. Effect of eradication of *Helicobacter pylori* infection on gastric epithelial cell proliferation. *Dig Dis Sci* 1995; 40: 1627—1631.
20. Thomsen LL, Gavin JB, Tasman-Jones C. Relation of *Helicobacter pylori* to human gastric mucosa in chronic gastritis of the antrum. *Gut* 1990; 31: 1230—1236.
21. Konturek JW, Gillessen A, Konturek SJ, Domschke W. Eradication of *Helicobacter pylori* restores the inhibitory effect of cholecystokinin on postprandial gastrin release in duodenal ulcer patients. *Gut* 1995; 37: 482—487.



22. McColl KEL, El-Omar EE. *Helicobacter pylori* and disturbance of gastric function associated with duodenal ulcer disease and gastric cancer. *Scand J Gastroenterol* 1996; 31 (Suppl 215): 33—37.

Received: April 25, 1997

Accepted: May 1, 1997

Authors address: S.J. Konturek, Institute of Physiology, Jagiellonian University School of Medicine, 16 Grzegórzecka Str., 31-531 Cracow, Poland.