

Review article

C. PIASECKI

EVIDENCE FOR AN INFARCTIVE PATHOGENESIS OF ACUTE AND CHRONIC GASTRODUODENAL ULCERATION

Royal Free Hospital School of Medicine, London, U. K.

It is clear that all mucosal defensive mechanisms acting against aggressive ulcerogenic factors depend on adequate blood flow. When defence is active, ulcers tend to heal and do so faster when luminal aggression is prevented by reduction of acidity or eradication of *H. pylori*. Such successful treatment is so profitable that pharmaceutical companies invest vast fortunes on research into every aspect of therapy. This may explain why research on basic aetiology has been slower. Nevertheless there have been recent advances which increasingly point towards an ischaemic pathogenesis of both acute and chronic ulcers. We have been studying those ischaemic mechanisms that may be triggered by alteration of normal physiological processes, and we now have a body of evidence supporting an infarction-like mechanism induced by abnormal motility which might explain the initiation of both acute and chronic human ulceration. In this article we review the evidence for this and show that such a pathogenesis is compatible with the features and current concepts of gastro-duodenal ulceration. Perhaps the most striking feature of chronic ulcers is their singularity, and localisation to the lesser curvature and first part of the duodenum. Within the lesser curvature there is an increasing incidence from the oesophageal end towards pylorus, with maximal incidence in the incisural area (1). Duodenal ulcers occur on the anterior or posterior walls of the first 4 cm. uncommonly on the superior "cap" and rarely on the inferior wall. Such localisation points to a primary cause which, by analogy with other localised necroses eg coronary or stroke, is usually an infarction of an end-artery system.

Key Words: *Ischaemia; microvasculature; chronic, acute gastric and duodenal ulcer aetiology*

Early Vascular Theories

In the first half of the Century a number of theories attempted to show how the blood supply to the ulcer area may be compromised. As early as 1853 Virchow (2) suggested that emboli may occlude small gastric arteries, thus introducing the vascular aspect though without any localising explanation.



C-34496

A single deep chronic ulcer is the typical response to pressure, as exemplified by the bed-sore. Thus Ivy et al (1) reviewed the subject of external pressure, but they were only able to conclude that a period of fashionable tight lacing of women's corsets was associated with a high incidence of gastric ulcer in women! The study of Doll, Avery-Jones and Buckatsch (3) of occupational incidence (though revealing the susceptibility of doctors and unskilled workers), was insufficient to reveal what manoeuvre, e. g. leaning against the edge of a table, might be responsible.

In 1908 Mayo first described the well known phenomenon known as "Mayo's anaemic spot" (4); whereby traction produced by pulling the stomach downwards and to the left at operation results in pallor on the anterior wall of the first inch of the duodenum. This pallor disappears on relaxing the tension. Wilkie (5) suggested the pallor was due to traction on the supraduodenal artery, which according to his studies was an end-artery. However, subsequent studies and observations have gone against this theory. Kirk (6) whilst confirming the existence of "Mayo's anaemic spot" reported that the force of traction was taken up by connective tissues which became taut leaving the vessels patent. Wilkie's statement that the supraduodenal artery was an end-artery is erroneous, because his drawings show that he had examined only the sub-serous branches of the artery, and not the branches of the sub-mucous plexus. Subsequent studies showed a rich anastomosis at the sub-mucous level (7—12). In any case, if flow in this artery were to cease the most ischaemic region would be expected at the centre of the area of supply — the top of the duodenal bulb — but peptic ulcers there are rare.

In the middle of the century a number of post-mortem injection studies of the stomach in man (7, 11, 13—16) described the established pattern of blood supply. Vessels approaching in the mesenteries pierce the external muscle, and divide forming a rich sub-mucous plexus in all regions. Mucosal arteries arise from the sub-mucous plexus and after piercing the muscularis mucosae they ramify in the mucosa. Prior to piercing the muscularis they anastomose by small branches. All these injection studies exhibit one localising factor — in the lesser curvature and in the first 2½ cm of the duodenum, the sub-mucous plexus is poorer than elsewhere in terms of having fewer and smaller vessels. However, the efficiency of the sub-mucous collaterals even of those in the lesser curvature, is demonstrated clinically by the absence of complications following the operation of ligating the majority of vessels piercing both curvatures (17, 18).

The existence of end-arteries

Our own studies confirm these findings, but bring to light two new features (19, 20). Firstly, in previous work there was doubt as to whether there is any anastomosis between capillary beds of adjacent mucosal arteries within the

mucosa. Careful stereoscopy with micromanipulation of injected vessels revealed there were no anastomoses. What appeared as anastomoses were in fact “overlapping” capillaries. In some cases there was no overlap and then the clear unfilled intervals between mucosal capillary beds was easily visible. Secondly, the poverty of vascularity in the lesser curvature found by previous authors, is localised still further. In the lesser curvature there is a quantitative decrease in number and calibre of anastomosing vessels from cardiac to pyloric parts: with a similar decrease in the duodenum from the second part to the pylorus, i. e. the plexus is least in the pyloric 1/3 of the lesser curvature and in the first inch of the duodenum.

However the most significant finding was that in these areas of poorest plexus, there are small areas with no plexus at all. The mucosa underlying these patches is supplied by mucosal arteries which arise outside the stomach wall, pierce the external muscle as well as the muscularis mucosae, and each supplies an area between 2 and 12 mm² surface area of mucosa. They do not connect up with the submucous plexus nor with other mucosal arteries in the mucosa, and so appear to be end-arteries. They are found only in the lesser curvature and first part of the duodenum and we call them “mucosal end-arteries of extramural origin”. *Fig. 1* shows the distribution of 47 such vessels found in ten human specimens (19, 20). This distribution corresponds exactly with the sites of chronic gastric and duodenal ulcers, thus demonstrating an anatomical basis for their localisation and suggesting that existence of these end-arteries may be an indispensable feature for initiating chronic ulceration. Since these stomachs did not have ulcers, a second factor accounting for their occlusion was clearly not operative in these individuals. It is possible that Barlow et al (11) did not notice these vessels since some individuals do not possess them, and when they do there may be only one or two such vessels so they are easily missed; secondly they were specifically studying arterio-venous anastomoses in these specimens. (The latter structures initiated much interest since they could potentially starve the mucosa of blood flow. However in spite of intensive search for them neither we nor others have been able to confirm their existence in the stomach either by injection studies or by the passage of variously sized beads — 19, 21).

In those individuals possessing end-arteries the occlusive mechanism could be a localised vasospasm or obstruction by prolonged tonic contraction of muscle layers. This might fit well with the commonly recognised though scientifically unproven relationship of ulcers with stress (1, 22). The fact that some individuals do not have such end-arteries explains why some people are not prone to peptic ulcers in spite of having high acidity or *H. Pylori* infection, and this could account for familial occurrence, geographical distribution and time changes in incidence. The size of ulcers could be determined by the fact that two or more such endarteries are found side by side.

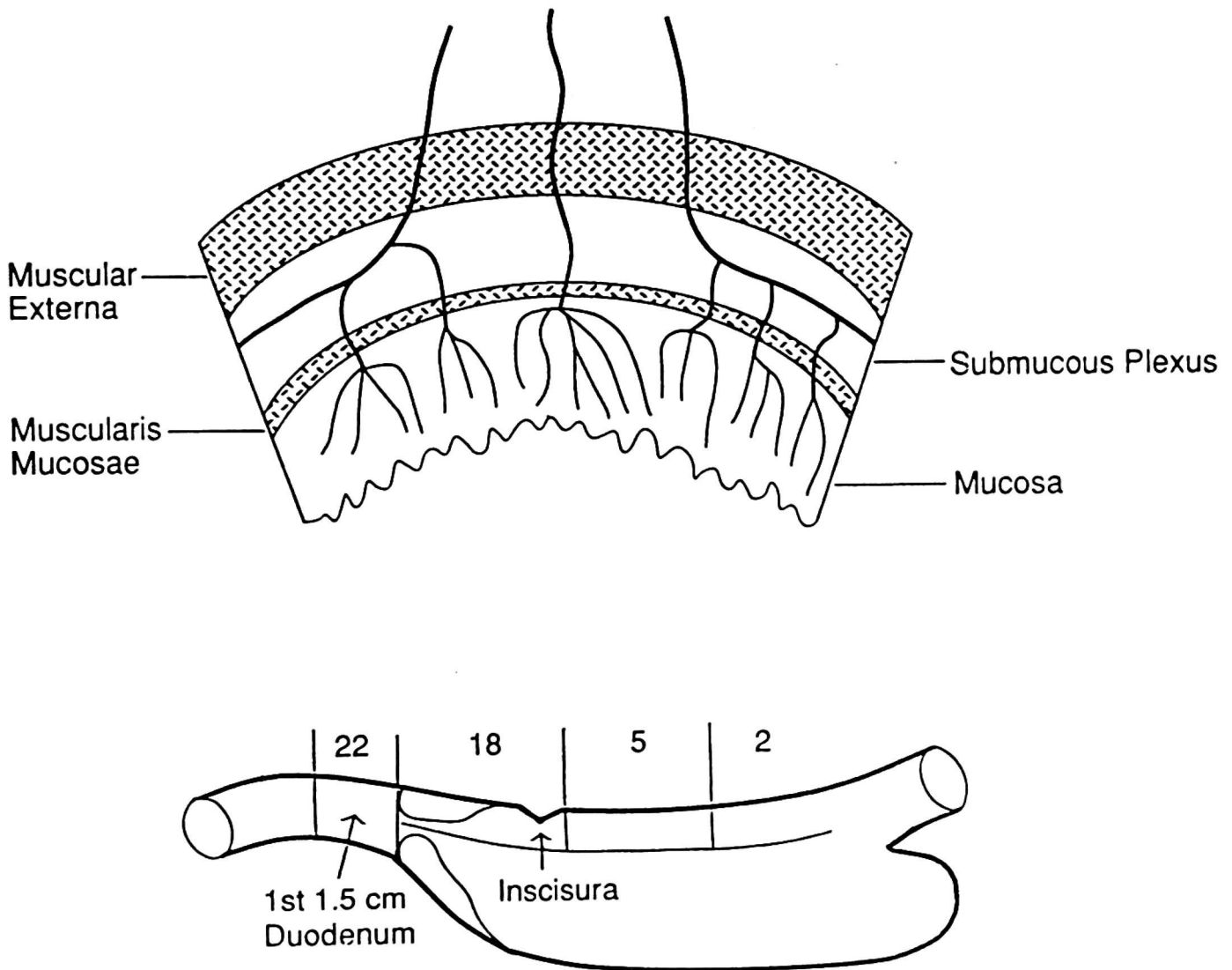


Fig 1. Upper: Diagrammatic representation in transverse section of the blood supply in the lesser curvature and adjoining walls in man. Note the single “mucosal end-artery of extramural origin in the centre which passes through both layers of muscle, (the centre represents the lesser curvature). On each side, normal inputs form a sub-mucous plexus, and mucosal arteries pass through one muscle layer, the muscularis mucosae.

Lower: Diagram to show the distribution of 47 end-arteries of extramural origin in 10 human specimens. Note the resemblance to the distribution of chronic peptic ulcers. (Reproduced by kind permission of Kluwer Acad. Publishers)

Unfortunately we were unable to find an *in vivo* animal model of end-arteries such as those found in man. Whilst post-mortem studies revealed that guinea-pigs and rabbits occasionally had such vessels we could not detect them *in-vivo* for dynamic studies (24).

We therefore turned our attention to ordinary mucosal arteries, which in post-mortem studies appeared to be end-arteries. In order to see if these are functional end-arteries we ligated 33 individual gastric mucosal arteries in guinea pigs. In 25 this resulted in necrosis of the whole thickness of the mucosa in the area supplied by each vessel. Thus three quarters of mucosal arteries are end-arteries in this species. Ligation of two or three adjacent mucosal arteries

resulted in necrosis in 95%, indicating that in the single ligations the remaining quarter of arteries survived because of an effective functional anastomosis from neighbouring vessels (25). This confirmed existing suspicions that ordinary mucosal arteries might be functional end-arteries, and suggested that focal ischaemia could be induced by vasoconstriction of these vessels or by their compression by the muscularis mucosae through which they or their branches pass. This mechanism could be invoked to explain the initiation of multiple-acute ulcers, since the required structural basis for infarction is present throughout the stomach.

Vulnerability of end-arteries to short periods of obstruction

In order to apply short obstructions to a single mucosal end-artery, it was necessary to find a way of ascertaining whether a particular vessel was an end-artery (since about a quarter of them were not end-arteries). We therefore developed a probe for continuously measuring oxygen delivery to small areas of mucosa. The instrument is basically a Clark-type oxygen electrode but modified to consume much oxygen, thus the instrument is blood flow dependent. It has been validated against the electromagnetic flowmeter in loops of

Oxygen Probe : Prediction of Necrosis

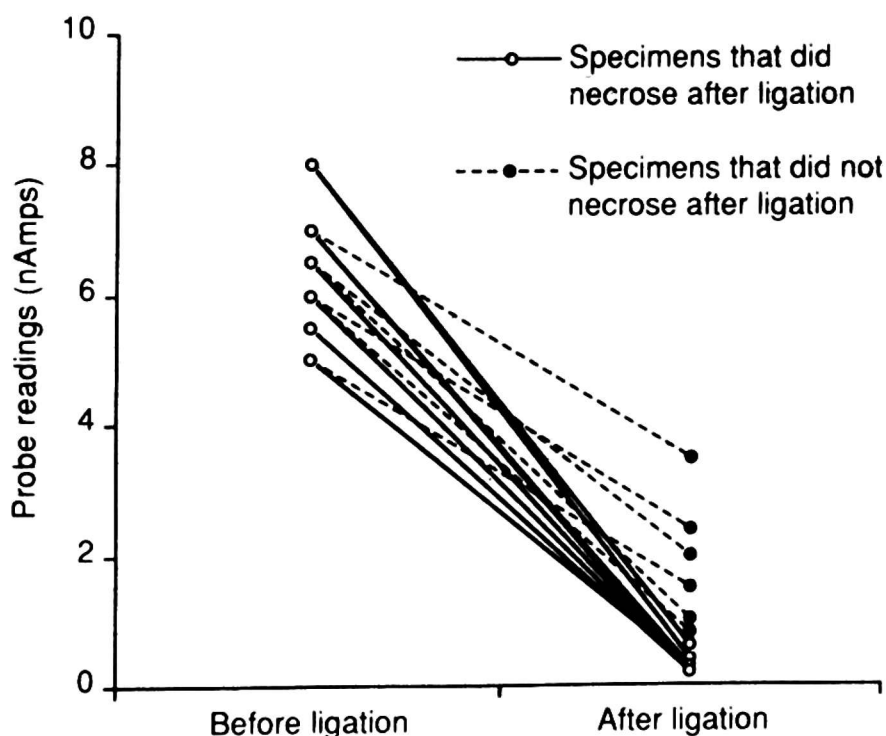


Fig 2. Use of the blood-flow dependent oxygen electrode to indicate the end-artery status of individual mucosal arteries. Measurements of blood perfusion are made in the area supplied by the artery, before and during a short temporary occlusion lasting one minute. A drop in reading as represented by solid lines indicates end-artery status. Dotted lines indicate necrosis will not occur.

By permission of Kluwer Academic Publishers.

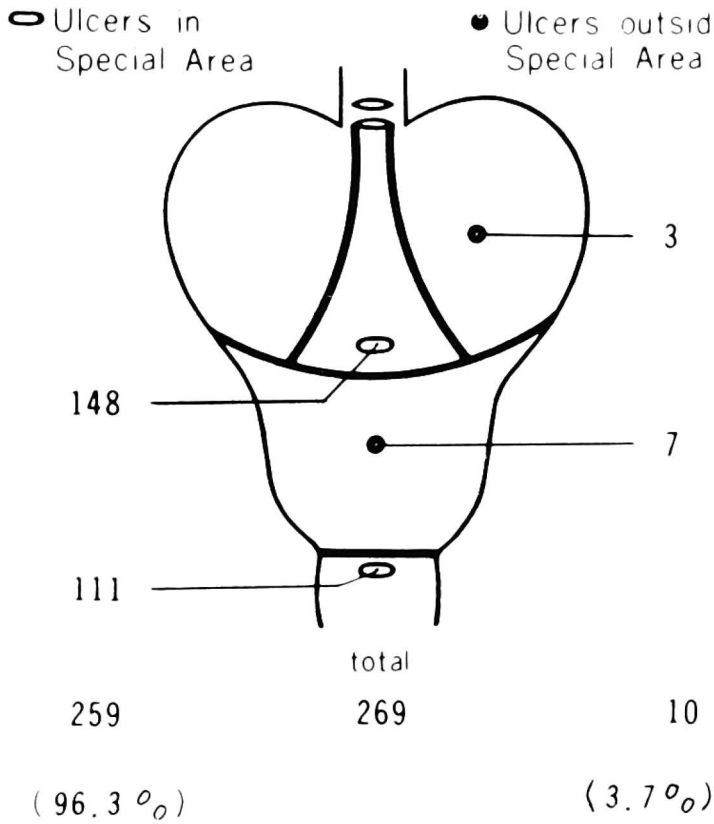
small and large intestine (26, 27). The electrode was embedded in the centre of a transilluminating light guide, and being visible it could be placed on the mucosa in the capillary distribution of a particular mucosal artery. Following permanent occlusion, we found that in those cases where necrosis occurred electrode readings fell to less than 7.5% of initial level, whilst in cases with no necrosis readings fell to between 13.7 and 50% of preligation levels (*Fig 2*). We thus calibrated our electrode so that immediately after occluding a vessel, the fall in the instrument's reading indicated the vessel's status.

The above method enabled selection of only mucosal end-arteries, which we temporarily obstructed for fixed durations using a snare, and allowed 3 hours recovery for histological necrosis to occur (28). In single obstruction experiments, there was no necrosis from a 20 minute obstruction, it sometimes occurred after 30 minutes and always after a 40 minute obstruction. However the results of shorter multiple obstructions were much more interesting. Necrosis began to occur in some cases after only 4 occlusions of five minutes duration, repeated at 1 minute intervals. It always occurred after 4 ten minute occlusions. Necrosis was always due to thrombosis in the vessel at the site of obstruction. Thrombosis began to occur after the 3rd five minute occlusion, but we were able to detach the thrombus by moving the vessel. After the 4th occlusion the thrombus could not be moved on, and the blockage became permanent. Now it could be argued that pulling a snare is unphysiological and unlikely to occur in life. However it has been shown by us and others (29) (see below) that contraction of muscle sheets through which arteries pass, causes complete obstruction of arteries, hence the snare technique does mimic real events as long as the minimum pull required to obstruct is used. In this case thrombosis is due to physical endothelial damage.

This shows that permanent thrombosis of end-arteries with subsequent ulceration, can be produced by relatively short and frequently repeated obstructions. This temporal aspect of obstruction is applicable to both ordinary mucosal arteries and the large end-arteries of extramural origin in man occurring in the areas prone to chronic ulcers.

Role of muscle layers

Whilst we do not deny the likelihood of vasoconstriction playing a part in occluding end-arteries, especially since this is a feature of stress, we feel the evidence is very strong for the occlusive factor being focal spasm of muscle layers, and we now outline the evidence supporting this mechanism.



External muscle

A very significant early work was that of Oi et al (30) who found that in man two thirds of gastric ulcers lie beneath thickened bundles of muscularis externa bordering the lesser curvature. There is also a gross thickening of the circular layer in a position suggestive of the incisura angularis. *Figure 3* shows the close relationship between the site of 63 gastric ulcers and the thickened muscle bundles. This seems strongly suggestive that this muscle plays a role in determining the site of ulceration.

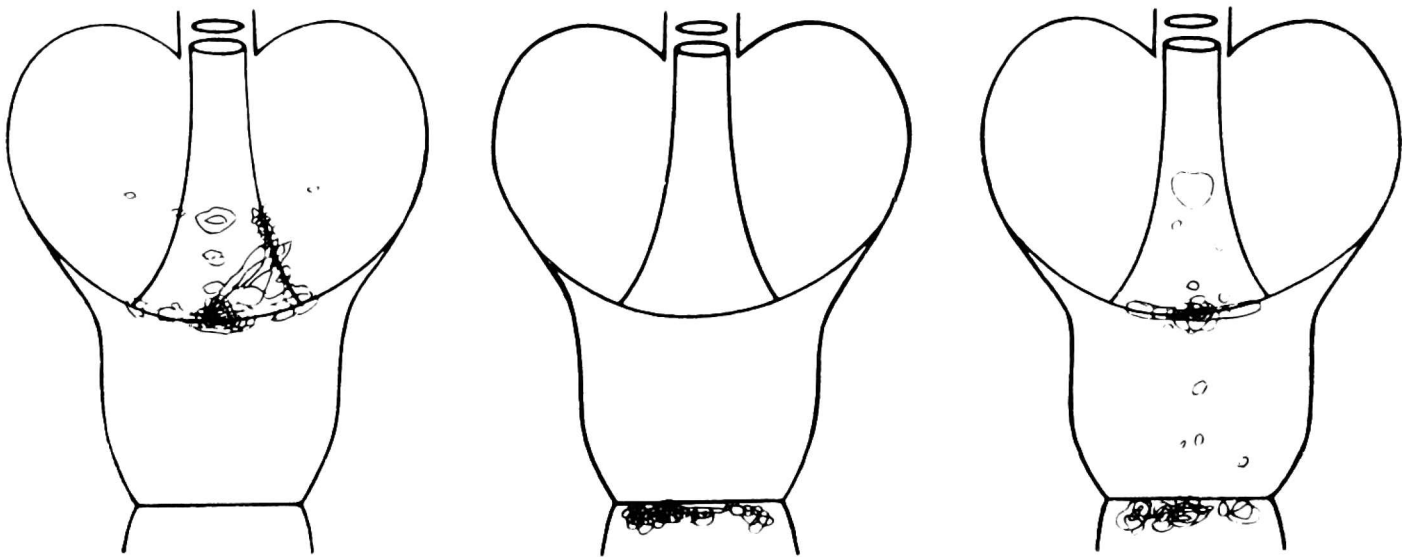


Fig 3. Upper: Location of chronic gastric and duodenal ulcers in relation to thickened muscle bundles. Two vertical curving lines within the stomach indicate muscles bordering the margins of the lesser curvature, whilst the horizontal curving line indicates thickened muscle at the incisura. The lowest horizontal line indicates the pylorus. Lower: A circle shows shape as well as location of an ulcer found on the musculature. Left, 64 ulcers single or multiple, of the stomach only which were found in 60 specimens selected at random. Middle, 56 ulcers, single or multiple, of the duodenum only which were found in 50 gastric specimens selected at random. Right, all of the combined gastric (30) and duodenal (25) ulcers. Numbers of specimens or ulcers had to be reduced to keep illustration of ulcer shape clear. (By permission of Gastroenterology)

Dynamic studies by Orator (31) and DeBuscher (32) show that in man the peristaltic wave tends to "stand still" at the incisura whilst the rest of it sweeps round the greater curvature (because of the greater length of this part), thus providing an association between sites of most prolonged contraction and the most frequent site of gastric ulceration. That contracting muscle obstructs flow in perforating arteries has been recently demonstrated by Livingston et al (29). We too confirmed (unpublished data) that vagally stimulated contraction of external musculature (peristaltic waves) in guinea pigs obstructs flow in perforating vessels. We were unable to produce tonic contractions at one site but the slowest wave caused arterial occlusion lasting 7 seconds. Simultaneous measurements with the oxygen electrode showed zero blood flow in the underlying mucosa. This was surprising — for it indicated that if compensation occurs via the sub-mucosal plexus it does not occur instantaneously.

These studies are relevant to human ulceration since abnormal motility has now been shown to be a feature in active ulceration, with hypomotility predominating (22, 33). Recently Read (34) showed that the major abnormality in duodenal ulceration is that the normal coordinated antral duodenal contractions are replaced by more complex non-propagated duodenal wave forms, i. e. suggesting focal spasm of external musculature. Such disturbances of motility occurring principally in the chronic ulcer bearing areas, would primarily affect the endarteries of extramural origin existing in those same areas. This, together with our finding that contraction of external muscle occludes vessels and that several 5 minute obstructions can result in thrombosis and ulceration, strongly support this theory.

It is in the light of the above musculo-vascular mechanism, that one can interpret certain recent studies in animals which favour muscular contraction as being important in ulcerogenesis. Thus in dogs chronic gastric ulcers have been induced by stimulating the muscle with chronically implanted electrodes (35). In stress produced by cold and restraint (36), or by hypothalamic stimulation (37) ulceration was associated with contractions that were increased fourfold in duration and amplitude. Hypermotility in the form of increased amplitude and frequency but not duration has also been associated with ulceration. Thus gastric ulcers in rats due to indomethacin have been associated with gastric hypermotility (38), and duodenal ulcers due to cysteamine with duodenal hypermotility (39). Whilst prolonged duration of contractions has not been detected in the latter two studies, it remains possible that in hypermotile states, foci of spasm might exist which would be undetected by the balloon methods used by the above authors.

Muscularis mucosae

Whilst the external musculature can obstruct the arterial supply and especially those end-arteries of extramural origin confined to the ulcer bearing area; the muscularis mucosae is in a position to obstruct all mucosal arteries throughout the stomach since in man these pass through it to reach the mucosa. In the rat, guinea-pig and rabbit however the sub-mucous plexus as well as the origins of mucosal arteries are all embedded within the muscularis mucosae which splits to enclose them (*Fig 4*) (24). It was Walder (40) who first

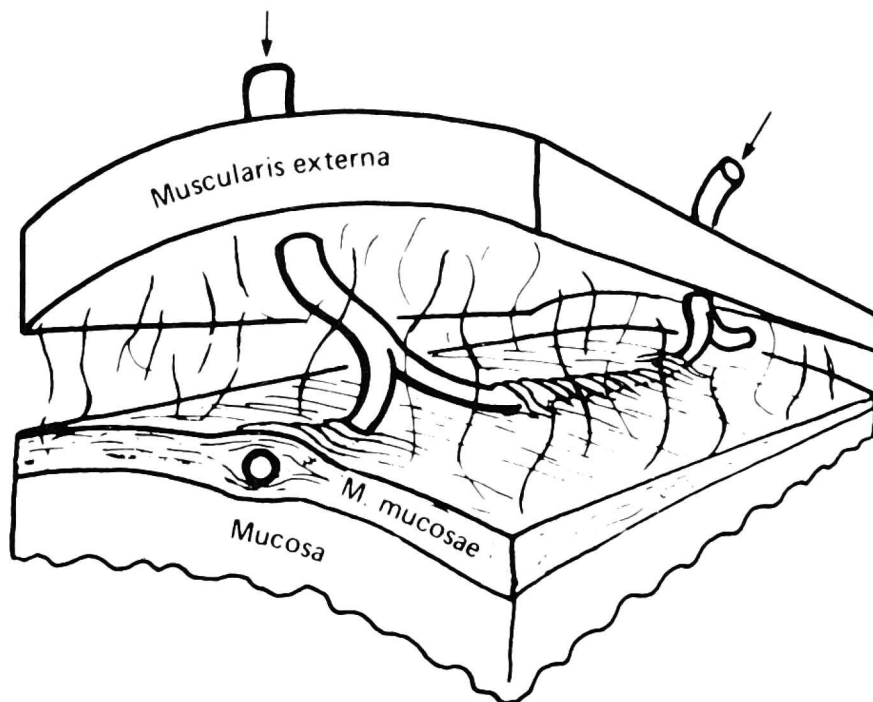
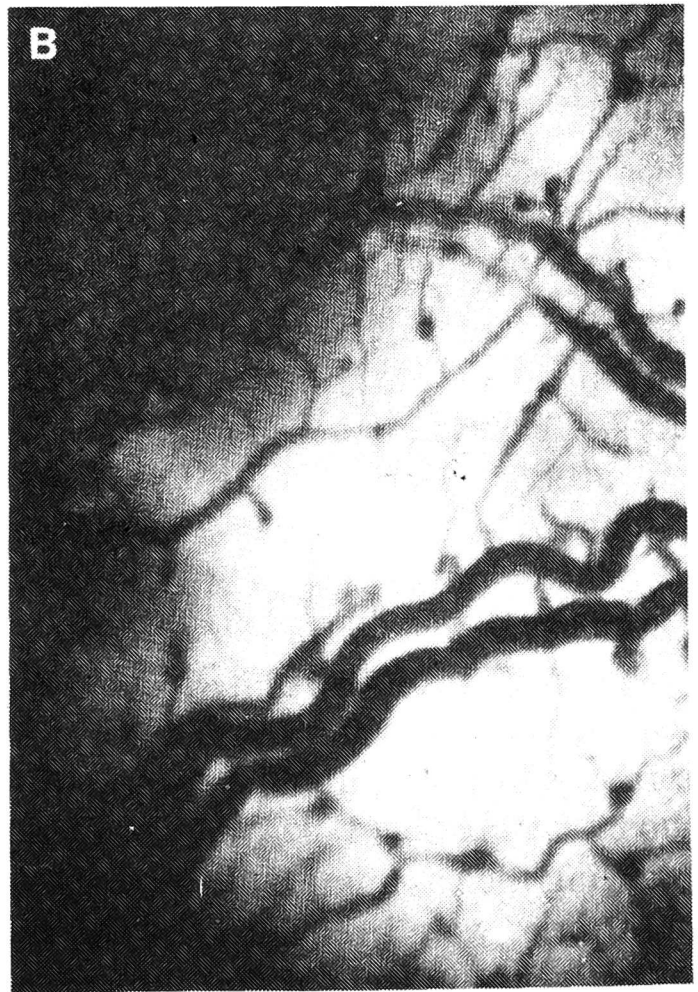
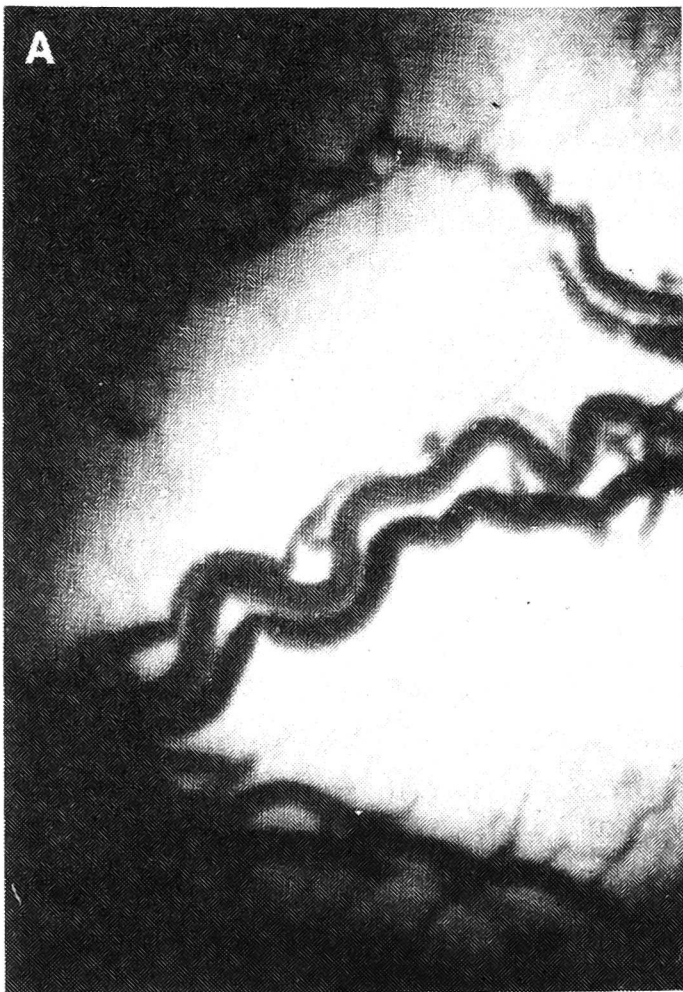


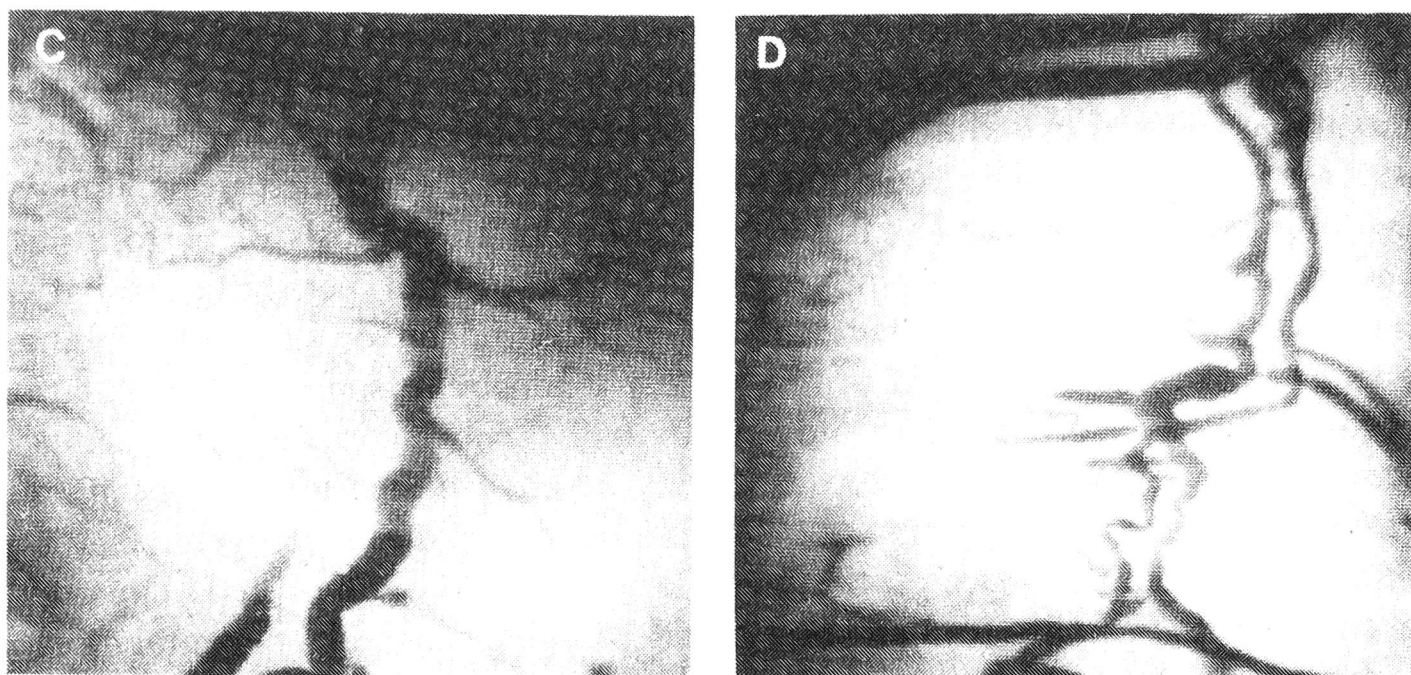
Fig 4. Three dimensional representation of vessels of the sub-mucosal plexus running along tunnels within the muscularis mucosae in guinea-pig. Contraction of muscularis mucosae in this pattern explains the appearance shown in *fig 5*. (By permission of the *Journal of Anatomy*).

suggested that the muscularis mucosae might obstruct mucosal arteries, and he performed the only pharmacological characterisation currently published of strips of gastric human muscularis mucosae. It responded strongly to pitressin and acetylcholine (1.3×10^7 -blocked by atropine), slightly to histamine (1.3×10^4), and variously to nicotine and adrenalin. But most importantly it was thicker in the lesser curvature and antrum than in other regions, and its contractions were stronger and more prolonged in this area.

Recently in our own in-vivo studies in guinea-pigs, we have seen irregular focal compression of arteries and veins of the submucosal plexus and mucosal arteries, which we putatively ascribe to compression by contracting muscularis mucosae, (*Fig 5*) (41). After removing a small piece of external muscle, and observing the vasculature by transillumination, foci were visible in which veins and arteries were irregularly compressed. When most severe, all small arteries veins were completely absent. In less severe cases veins were completely devoid

of blood with a sudden cut off at the point where they enter the muscularis mucosae, whilst arteries were clearly flattened by transverse bands, a picture quite different from intrinsic vasoconstriction. The phenomenon was not due to extramural pressure since it was present before the light guide touched the tissue. Moreover the size of the area exhibiting this „spasm” was shrunk by 27% as compared to its size when later relaxed, and this was manifested at the time of spasm by tortuosity of unaffected vessels. This phenomenon is new to the literature and we conclude it could only be caused by the one remaining muscle, the muscularis mucosae. There was a concomitant pallor of the mucosa which can only be explained by compression of the mucosa induced by prolongations of muscularis mucosae into the mucosa (42). Simultaneous recording of O₂ delivery to the pale mucosa showed severe ischaemia, oxygen content being only 2 to 5% of that when the spasm effect had passed off. This phenomenon, was also visible through the external musculature before the latter was cut, and indeed cutting it intensified the phenomenon. If left undisturbed these foci of spasm disappeared spontaneously within 3—5 minutes (whereupon a normal circulation reappeared), but they could also be abolished in 3—5 seconds by gentle mechanical stimulation of the mucosal surface. Indeed manipulation performed to produce the best possible illumination abolished the effect, and this explains why many workers have missed seeing this phenomenon.





- Fig 5.* A. Submucosa. Gastric submucosal vessels immediately after exposure, showing a focus in which small veins are completely obstructed, and small arteries partially, with pallor of the mucosa. $\times 40$.
- B. 5 seconds after mechanical stimulation of mucosa. Note appearance of venous network invisible in the left picture, more prominent small arteries and less pallor of mucosa. Note the diminished tortuosity of the two largest parallel vessels in the picture. Vessels now appear normal under conditions of the experiment. $\times 40$
- C. This is an enlarged view of a portion of Fig. 5A. Transverse bands appear to partially constrict the large artery running from top to bottom. The accompanying vein is completely obstructed and its stem is visible at the top of the picture. $\times 80$
- D A very severe case of spasm of small-mucosal vessels at low power. The central pale area is sub-mucosa and mucosa, whilst the darker surroundings are the edges of the external muscle which has just been cut. $\times 25$
- (Figs 5C, D by permission of Kluwer Academic Publishers)

This mucosal stimulation reflex is probably mediated by the capsaicin-sensitive neural reflex whereby nerve endings in mucosa increase blood flow (43). Its mediation by leukotrienes or opioids (44) suggest an area of possible pharmacological intervention for preventing focal ischaemia in alcohol ingestion and stressful situations. A very similar segmental constriction of submucosal veins has been shown to occur with leukotriene C₄ and ethanol (45, 46, 47). The effect of these substances on the gastric circulation may therefore be mediated in part by the muscularis mucosae, and the concomitant mucosal stasis and increased permeability may be secondary effects.

However another important feature of the spasm was that in 5 out of 25 cases it could not be abolished by mechanical stimulation. It remained and was observed for 3 hours, whereupon the underlying mucosa had full thickness necrosis, in contrast to surrounding areas which had normal mucosa underlying uncompressed vessels. In these cases thrombosis had occurred in the obstructed arteries and veins in the first 20 minutes.

Whilst it is generally thought that the muscularis mucosae acts to compress the mucosa in order to pump out secretions from the glands into the lumen, the above study shows that in the absence of motility this may happen at the expense of occluding the circulation. In the presence of continued stress, it may be prolonged in susceptible cases to the point, of thrombosis of perforating vessels and necrosis. This implies that during normal peristaltic activity, movements of opposing surfaces of an empty stomach or of food rubbing against the mucosa, will tend to reverse any tendency to spasm of muscularis mucosae. Conversely, reduced movements will favour spasm and ischaemia. Accordingly hypotonia and slow emptying as have been shown to occur in stress and in chronic ulceration (22, 23), can be regarded as ulcerogenic factors in so far as their influence on the muscularis mucosae is concerned. Thus the cycle of events leading to ulceration could be acute physical or mental stress inducing patchy contraction of the muscularis mucosae. This obstructs the circulation and when contractions of 5 or more minutes duration are repeated, an acute ulcer will result. Continued periodical stress, preferentially affecting the lesser curvature and antrum, and perhaps exacerbated by infection with *H. pylori*, will make a gastric ulcer chronic until rest and medication stop the process. In the case of duodenal ulcer, continued stress, and both acidity and *H. pylori* infection will act against healing. The same mechanism could be applied to ulcers whose acuteness would be due to single application of stress, and multiplicity due to multifocal distribution of spasm of muscularis mucosae. Several mucosal arteries are obstructed in such a focus, resulting in necrosis in a variably sized area, thus accounting for ulcer size and extension.

CONCLUSION

We have presented evidence that large end-arteries exist in man and are confined to the areas where chronic ulcers occur, and that many ordinary mucosal arteries are functional end-arteries. Five minute repeated compressions of such vessels are sufficient to produce ulceration. Such compression can occur from contraction of muscularis externa and of the muscularis mucosae, and we have seen acute stress causing focal spasm of muscularis mucosae resulting in ischaemia and ulceration. We therefore suggest the pathogenesis of ulceration may be as follows:-

STRESS → PROLONGED REPEATED MUSCLE SPASM → OBSTRUCTED
CIRCULATION → ISCHAEMIA → BREAKDOWN OF MUCOSAL BARRIERS → ULCERATION

A chronic ulcer will result if this mechanism is local, repeated and affects one of the large end-arteries in the lesser curvature or first part of the duodenum. Acute multiple ulcers will result if the mechanism involves the

muscularis mucosae affecting ordinary mucosal arteries throughout the organ. This pathogenesis accounts for the localisation and initiation of lesions. Subsequent healing or progression will depend on the balance of aggressive or defensive factors. It is totally compatible with the well established mechanisms of breakdown of mucosal barriers, with acidity and *H. pylori* preventing healing and with therapeutic regimens designed to promote healing. The missing step in this sequence, which may prove to be a fruitful line of future investigation, is whether patients develop abnormally prolonged focal spasm of external muscle or muscularis mucosae before the ulcer occurs. Perhaps the reason why current therapy has not been successful in preventing recurrence, is because it has not been aimed at attacking the initiating cause. A new approach could be development of drugs that will relax stress-induced spasm which, as we suggest, might be the most important cause of initiation and recurrence.

Acknowledgements: The various studies described here have been carried out with grants from the Peter Samuel Royal Free Fund and the Wellcome Trust.

REFERENCES

1. Ivy AC, Grossman MI, Bachrach WH. Peptic Ulcer, J. and A Churchill Ltd., London; 1950.
2. Virchow R. Historisches Kritisches und Positives zur Lehre der Unterleibasaffektionen. *Virchow Arch Pathol Anat Physiol* 1853; 5: 281—386, 632.
3. Doll R, Avery-Jones F, Buckatsch MM. Occupational factors in the aetiology of gastric and duodenal ulcers. *Spec Rep Med Res Council, HMSO, London* 1951; 276: 1—96.
4. Mayo WJ. Anaemic spot on the duodenum. *Surg Gyn & Obst* 1908; 6: 600.
5. Wilkie DPD. Blood supply to the duodenum with special reference to the supraduodenal artery. *Surg Gyn & Obst* 1911; 13: 399—405.
6. Kirk RM. Site and localisation of duodenal ulcers: a study at operation. *Gut* 1968; 9: 414—419.
7. Reeves TB. Study of arteries to the stomach and duodenum, and their relation to ulcer. *Surg Gyn & Obst* 1920; 30: 374—385.
8. Shapiro AL, Robillard GL. Morphology and variations of duodenal vasculature. *Arch Surg* 1946; 52: 571—602.
9. Wilmer HA. Blood supply to the first part of the duodenum. *Surg* 1941; 9: 679.
10. Dubas J. La vascularisation de premier part du duodenum. These de Fribourg. 1947.
11. Barlow TE, Bentley FH, Walder DN. Arteries, veins and arteriovenous anastomoses in the human stomach. *Surg Gyn & Obst* 1951; 93: 657—671.
12. Masturzo G. La vascolarizzazione della primera prozione del duodeno. *Rassegna Internazionale de clinica e terapia* 1953; 43: 660—667.
13. Disse H. Uber die Blutgefasse menschlichen Magenschleimhaut, besodners uber die Arterien derselben. *Archiv für mikroskopische Anat* 1903; 63: 512—531.
14. Jatrou S. Uber die arterielle Versorgung des Magens und ihre Beziehung zum Ulcus ventriculi. *Deutsche Zeitschrift für Chirurgie* 1920; 159: 196—223.
15. Hoffman L, Nather K. Zur Anatomie der Magenarterien. *Archiv für klinische Chirurgie* 1921; 115: 650—671.

16. Berlet K. Über die Arterien des menschlichen Magens und ihre Beziehungen zur Aetiologie und Pathogenese des Magengeschwurs. *Zeitschrift für Pathologie* 1923; 30: 472—489.
17. Somervell TH. Physiological gastrectomy: the operation of ligation of the arteries of the stomach to relieve hyperacidity and to prevent recurrent ulceration after gastroenterostomy. *Br J of Surg* 1945; 33: 146—152.
18. Wood WQ. Treatment of peptic ulceration by vascular ligation. *Arch Surg* 1949; 58: 455—462.
19. Piasecki C. Blood supply to the human gastroduodenal mucosa with special reference to ulcer bearing areas. *J Anat* 1974; 118: 295—335.
20. Piasecki C. A possible vascular factor in the aetiology of duodenal ulceration. *Br J Surg* 1971; 58 (9): 660—662.
21. Guth PH, Leung FW. Ch. 36. Physiology of the gastrointestinal tract. LR Johnson (Ed). Raven Press 1987.
22. Yabana T, Yachi A. Seminars on gastric mucosal injury VI: Stress induced vascular damage and ulcer. *Dig Dis Sci* 1988; 33: 751—761.
23. Guth PH, Smith E. Vasoactive agents in the gastric microcirculation. *Microvascular Res* 1974; 8: 125—131.
24. Piasecki C, Wyatt C. Patterns of blood supply to the gastric mucosa. A comparative study revealing an end-artery model. *J Anat* 1986; 149: 21—39.
25. Piasecki C, Thrasivoulou C, Rahim A. Ulcers produced by ligation of individual gastric mucosal arteries. *Gastroenterology* 1989; 97: 1121—1129.
26. Piasecki C. A new method for the assessment of gut viability. *Br J Surg* 1981; 68: 319—322.
27. Piasecki C. First experimental results with the oxygen electrode as a local blood flow sensor in canine colon. *Brit J Surg* 1985; 72: 452—453.
28. Piasecki C, Thrasivoulou C. Durations of complete focal mucosal ischaemia required to produce gastric ulceration at low acidity. *Eur J Gastroenterology and Hepatology* 1992; 4: 487—493.
29. Livingstone EH, Howard T, Passaro EP, Guth PH. Effect of gastric contractions upon gastric mucosal blood flow. *Gastroenterology* 1990; 98: A187.
30. Oi M, Ito Y, Jumagai F, et al. A possible dual control system in the origin of peptic ulcer. A study on ulcer location as affected by mucosa and musculature. *Gastroenterology* 1969; 57: 280—293.
31. Orator, V (1925). Cited by Ivy AC, Grossman, MI, Bachrach WH. In *Peptic Ulcer*. Churchill, London, 1950; p. 519.
32. Busscher G de. Les anastomoses arterio-veineuses. *Acta Neurol Morphologicae (Normalis et Pathologicae)* 1948; 6: 87—105.
33. Barbara L, Stranghellini V, De Giorio R, Paternico A, Corinaldesi R. Gastrointestinal motility in pathological conditions. *Gastric Motility*. R Cheli, E Bovero, N Pandolfo (Eds). Raven Press, New York; 1988: pp. 83—94.
34. Read NW. The role of gastroduodenal motor activity in peptic ulceration. *Mechanisms of Peptic Ulcer Healing: Falk Symposium 59*. F Halter, A Garner, G Tytgat (Eds). Kluwer, Lancaster; 1991 pp 195—203.
35. Quist G, Dormandy J, Brown C, Sloane D, Scott G. The experimental production of gastric ulcers by induced muscle spasm. *Br J Surg* 1974; 61: 259—263.
36. Garrick T, Leung FW, Buack S, Hirabayashi K, Guth PH. Gastric motility is stimulated but overall blood flow is unaffected during cold restraint in the rat. *Gastroenterology* 1986; 91: 141—148.
37. Garrick T, Grijalva C, Trauner M. High amplitude contractions are necessary for lateral hypothalamic lesion and tail shock mucosal injury. *Gastroenterology* 1990; 99: A1213.
38. Ueki A, Takeuchi K, Okabe S. Gastric motility is an important factor in the pathogenesis of indomethacin-induced gastric mucosal lesions in rats. *Dig Dis Sci* 1988; 33: 209—216.

39. Takeuchi K, Nishikawa H, Okabe S. Role of local motility changes in the pathogenesis of duodenal ulcers induced by cysteamine in rats. *Dig Dis Sci* 1987; 32: 295—304.
40. Walder DN. The muscularis mucosae of the human stomach. *J Physiol* 1953; 120: 373—382.
41. Piasecki C, Thrasivoulou C. Focal spasm of gastric muscularis mucosae can induce focal ischaemia and ulceration. *Gut* 1991; 32 A 1246.
42. Leeson CR, Leeson TS, Paparo AA. Textbook of histology. Saunders WB 1985; p. 337.
43. Holzer P, Pabst M, Lippe I et al. Afferent nerve-mediated protection against deep mucosal damage in the rat stomach. *Gastroenterology* 1990; 98: 838—848.
44. Esplugues JV, Whittle BJR. Morphine potentiation of ethanol-induced gastric mucosal damage in the rat. *Gastroenterology* 1990; 98: 82—89.
45. Whittle BJR, Oren-Wolman N, Guth PH. Gastric vasoconstrictor actions of leukotriene C₄, PGF₂α, and thromboxane mimetic U-46619 on rat submucosal microcirculation in vivo. *Am J Physiol* 1985; 248: G580—G586.
46. Bou-Abboud CF, Wayland H, Paulsen G, Guth PH. Microcirculatory stasis precedes tissue necrosis in ethanol-induced gastric mucosal injury in the rat. *Dig Dis Sci* 1988; 33 (7): 872—877.
47. Oates PJ, Hakkinen JP. Studies on the mechanisms of ethanol-induced gastric damage in rats. *Gastroenterology* 1988; 94: 110—121.

Received: October 14, 1991

Accepted: December 12, 1991

Author's address: Chris Piasecki, Royal Free Hospital School of Medicine, Rowland Hill Street, London, NW3 2PF, UK