



# A single-centre retrospective observational study of fungal keratitis in Poland with a review of findings in Europe

Katarzyna Ewa Nowik<sup>1,A,C-D</sup>, Adam Wylęgała<sup>1,C-D</sup>, Kamil Nowik<sup>2,A,C</sup>, Edward Wylęgała<sup>1,A-C,E-F</sup>

<sup>1</sup> Department of Ophthalmology, School of Medicine with the Division of Dentistry, Zabrze, Poland Medical University of Silesia, Katowice, Poland

<sup>2</sup> Department of Management and Financial Science, School of Economics, Warsaw, Poland

A – Research concept and design, B – Collection and/or assembly of data, C – Data analysis and interpretation, D – Writing the article, E – Critical revision of the article, F – Final approval of article

Nowik KE, Wylęgała A, Nowik K, Wylęgała E. A single-centre retrospective observational study of fungal keratitis in Poland with a review of findings in Europe. *Ann Agric Environ Med.* 2020; 27(3): 343–347. doi: 10.26444/aaem/109414

## Abstract

**Introduction.** Fungal keratitis is a severe condition which may lead to blindness. Fungal keratitis, also known mycotic keratitis or keratomycosis, has worldwide distribution, but is more common in tropical climates compared to moderate zones. In recent years, there have been several studies suggesting an increase in the number of mycotic keratitis cases in countries with a moderate climate. There is little data available with no literature review concerning fungal keratitis in European countries.

**Objective.** To analyse the causes, presentation, and clinico-pathological associations of fungal keratitis in a retrospective series of patients referred to the Department of Ophthalmology of the Railway Hospital in Katowice, south-west Poland, and comparing the findings to previously published studies in peer reviewed articles from other European countries published between 2000–2019.

**Materials and method.** Data were collected using the medical records of patients with fungal keratitis. Risk factors, clinical manifestation and treatment results were analysed from 45 patients (45 eyes) with fungal keratitis treated in the Department of Ophthalmology of Railway Hospital in Katowice between January 2013 – December 2017. The factors affecting the development of infection, visual acuity at baseline and at the end of treatment, as well as treatment method selection, were analysed. Literature review was performed using the Medline, Pubmed, Embase databases and Google scholar. The inclusion criteria were peer reviewed papers published between 2000–2019 which reported data from patients with fungal keratitis in at least one European country. 11 peer reviewed articles which matched the inclusion criteria were analysed.

**Results.** The mean BCVA of patients treated in the Department of Ophthalmology of the Railway Hospital in Katowice upon diagnosis was 2.3 (logMAR), compared to 1.95 (logMAR) at the end of treatment. Pearson's chi-squared test was used to establish the final mean BCVA in eyes with keratitis caused by *Candida spp.* compared with keratitis caused by *Filamentous spp.* The reviewed articles showed poor results of treatment and diagnostic difficulties in fungal keratitis.

**Conclusions.** Fungal keratitis is a significant diagnostic and therapeutic challenge and may occur in rural and urban areas. Early and accurate diagnosis followed by proper antifungal treatment can prevent blindness and improve BCVA results.

## Key words

fungal keratitis, keratomycosis, confocal microscopy, keratoplasty, yeast, filamentous

## INTRODUCTION

Fungal keratitis was first reported by Theodor Leber in 1879 in a farmer who sustained ocular trauma when working on his farm. The highest prevalence of fungal keratitis is shown in hot and humid climate zones, where it may constitute 30–62% of all cases of keratitis [1, 2, 3, 4, 5, 6]. However, in recent years, the prevalence of fungal keratitis in moderate climate zones has been increasing [7]. This can be linked to better availability and popularity of contact lenses and, as a result, fungal infections caused by *Fusarium spp.* The available literature has identified a number of risk factors of fungal infections.

Fungal keratitis poses a significant diagnostic and therapeutic challenge, due to limited diagnostic options, microbial isolation, poor penetration of deeper corneal layers, and the limited number of therapeutic agents available in Poland.

## OBJECTIVE

The purpose of this study was to review the causes, presentation, and clinico-pathological associations of fungal keratitis in a retrospective series of patients referred to the Department of Ophthalmology of the Railway Hospital in Katowice, south-east Poland, as well as to compare the findings to previously published studies from other European countries.

Address for correspondence: Katarzyna Ewa Nowik, Department of Ophthalmology, School of Medicine with the Division of Dentistry in Zabrze, Medical University of Silesia, Katowice, Poland  
E-mail: lek.katarzynaolejnik@onet.eu

Received: 30.03.2019; accepted: 16.05.2019; first published: 09.08.2019

## MATERIALS AND METHOD

Patients with fungal keratitis were identified by reviewing medical records from 2013–2017. Risk factors, clinical manifestation and outcome were recorded.

**Patients and study design.** The retrospective analysis is presented of 45 patients (45 eyes) with fungal keratitis treated in the Department of Ophthalmology of the Railway Hospital in Katowice between January 2013 – December 2017.

The study was performed in compliance with the Declaration of Helsinki.

**Ophthalmic investigations.** All subjects underwent a comprehensive assessment which included medical history, risk factor identification for fungal keratitis, slit lamp examination, confocal microscopy with Rostock Corneal Module on HRT3 (Heidelberg Engineering, Germany), and corneal scrapings (using 23G needle) or conjunctival smear for microbial testing. Depending on lesion location, limbal involvement and the presence of hypopyon, a dedicated treatment algorithm was followed involving systemic and topical antifungal agents, subconjunctival, intracorneal, intracameral injections and cross-linking. Corneal graft was performed in eyes not responding to antifungal treatments and those with corneal perforation. The factors affecting the development of infection, visual acuity at baseline and at the end of treatment as well as treatment method selection were analysed.

**Literature review of cases of fungal keratitis in Europe.** Literature review was performed using the Medline database and Google scholar. The inclusion criteria were peer reviewed papers published between 2000–2019 which reported observational data from patients with fungal keratitis in at least one European country. The following search terms were used: “fungal keratitis”, “keratomycosis”, “pattern of fungal keratitis in Europe” and “epidemiology of mycotic keratitis”. Ten published articles met the inclusion criteria [8–18]. The literature data was analysed in terms of gender, age, causes of fungal keratitis, and treatment outcomes in order to identify similarities and differences, and to enable further comparisons with the results obtained at the Department of Ophthalmology of the Railway Hospital in Katowice.

**Statistical analysis.** To assess the normality of distribution for the available data, the Shapiro-Wilk’s test was used. Excel (Office 365) and Statistica 13 bundles were used for calculations and design of graphs and diagrams. Normally distributed variables were reported as a mean and standard deviation (SD). The unpaired student’s t-test was used for comparisons between patients with yeast versus filamentous keratitis. Visual acuity was presented as a logMAR scale, assuming a 95% confidence interval (95% CI). Due to the non-normal distribution of visual acuity on the logMAR scale, the Wilcoxon test was used for the analysis of BCVA values at baseline and at the end of treatment. Pearson’s chi-squared test was used for comparing categorical variables between patients with yeast versus filamentous keratitis.

## RESULTS

**Retrospective observational study findings in Poland, 2003–2017.** A group of 45 patients with fungal keratitis hospitalised in the Department of Ophthalmology of the Railway Hospital in Katowice consisted of 20 women (44.4%) and 25 men (55.6%), with a mean age of 51.7 years (SD 16.3). The mean time from the onset of symptoms to the commencement of antifungal therapy was 12 days (SD 12.3).

The risk factors for fungal keratitis included eye injury involving organic matter (15 cases), wearing contact lenses (10 cases), long-term use of corticosteroids (6 cases), previous ocular surgery (7 cases) and ocular surface disorder, such as dry eye disease secondary to Sjögren’s syndrome, blepharitis with Meibomian gland dysfunction, or neurotrophic keratopathy (7 cases). The infectious agents were filamentous fungi – 25 cases (55.6%) and yeast – 20 cases (44.4%). Among the filamentous fungi, the most often isolated pathogen was *Fusarium solani*, whereas the most often isolated representative of yeast was *Candida albicans*. The most common factor associated with fungal infection was eye injury involving organic matter, followed by wearing contact lenses, ocular surface disorder, previous ocular surgery (keratoplasty), and previous use of corticosteroids. Eye injury involving organic matter was the main risk factor in cases of infections caused by *Fusarium spp.*, whereas keratitis caused by *Candida albicans* occurred more often in patients after previous ocular surgery, as well as those with ocular surface disorder, and – to a less extent – in contact lens wearers. Microbial analyses confirmed the fungal origin of keratitis in 25 patients (55.6%) with 15 cases (33.3%) of filamentous fungal keratitis and 10 cases (22.2%) caused by yeast. Confocal microscopy demonstrated features of fungal keratitis in 42 cases (93.3%).

The mean BCVA upon diagnosis was 2.3 (logMAR), compared to 1.95 (logMAR) at the end of treatment. The final BCVA was better in eyes with keratitis caused by yeast rather than filamentous fungi. Visual acuity improvement was demonstrated in 24 patients, it remained unchanged in 12 patients and worsened in 9 patients. The mean antifungal treatment duration was 110 days. The end of treatment was defined as a “calm eye”, with no signs of inflammation and/or corneal scarring. Upon this presentation, antifungal treatments were discontinued. The mean follow-up duration was 20 months. Treatment of fungal keratitis significantly affected the visual outcome in the study population ( $p = 0.04$ ).

The treatment protocol for keratitis caused by filamentous fungi included topical fluconazole (18 eyes) or voriconazole (15 eyes), administered every hour during the day and every 2 hours during the night throughout the first 48 hours. In cases of keratitis caused by yeast, topical amphotericin B was used (12 eyes). Where the corneal inflammatory infiltrate penetrated deep into the stroma or to the anterior chamber, intracorneal (12 eyes) or intracameral (8 eyes) injections of voriconazole, subconjunctival injections of fluconazole (25 eyes) and systemic fluconazole (p.o.) were administered.

Corneal cross-linking was used as an adjunctive to medical treatment in 7 selected cases of limited inflammation with only superficial (below 250  $\mu\text{m}$ ) corneal layer involvement. There were 8 cases of corneal perforation, which were treated with keratoplasty. Keratoplasty was also performed in eyes not responding to medical treatment, a total of 19 eyes (42.2%), including 4 eyes after CXL. During each

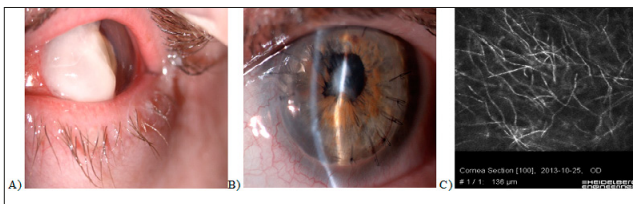
keratoplasty, fluconazole or voriconazole was administered as an intracameral or intracorneal injection. The mean time from the commencement of antifungal treatment to keratoplasty was 16.93 days. Two patients required subsequent corneal graft due to a decompensated primary flap.

Fungal keratitis reoccurred in 6 cases. Three of them were effectively treated with targeted antifungal agents, whereas 3 needed keratoplasty. In one male, evisceration was performed due to malacia of the corneal flap with extremely unfavourable vision prognosis. This particular patient had 4 previous corneal grafts. The first penetrating keratoplasty was performed due to post-traumatic ocular perforation, and all subsequent grafts were decompensated.

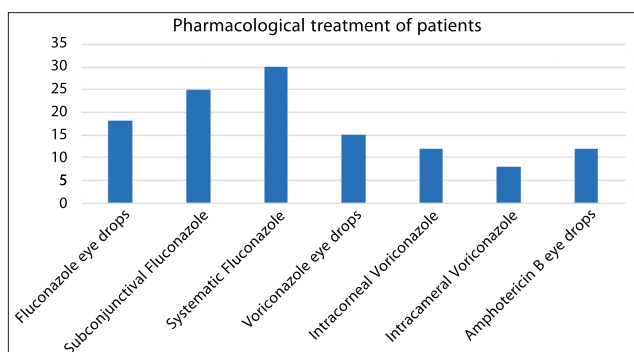
**Table 1.** Clinical features, statistical analysis and treatment outcomes in patients with fungal keratitis. Comparison of *Candida* versus filamentous fungi

Variables	Filamentous	Yeast	P value (<0.05)
Number of subjects	25	20	
Gender: women (%)	40% (10:15)	55% (11:20)	0.46 <sup>2</sup>
men (%)	60%	45%	0.49 <sup>2</sup>
Mean age (years)	46.68	56.65	0.0388 <sup>1</sup>
Risk factors:			
– Contact lenses	8	2	
– Trauma	12	3	
– Ocular surface disease	2	5	0.025 <sup>2</sup>
– Previous ocular surgery	1	6	
– Long term use of topical steroids	2	4	
Mean visual acuity upon diagnosis (logMAR)	2.5	2.081	0.2 <sup>2</sup>
Mean visual acuity after treatment (logMAR)	2.6 (0–4)	1.896	<0.01 <sup>2</sup>
Medical treatment only	11 (44%)	15 (75%)	
Corneal graft	14 (56%)	5 (25%)	
Mean time to heal (days)	130	86	<0.01 <sup>2</sup>

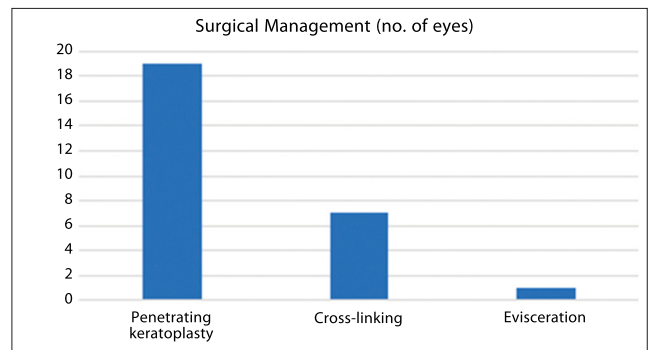
<sup>1</sup> – Student's T-test; <sup>2</sup> – Chi-squared test



**Figure 1.** Slit-lamp examination of a *Fusarium solani*-infected patient's cornea after organic material injury (Fig. 1A). Image of the same patient's eye one week after PK (Fig. 1B). HRT III with the Rostock Cornea Module (Heidelberg Engineering, Germany) of *Fusarium solani*-infected patient's cornea showing high-contrast lines resembling *Fusarium* hyphae, high-contrast structures consistent with corneal nerves (Fig. 1C)



**Figure 2.** Number of patients with fungal keratitis receiving medical management only



**Figure 3.** Surgical management – number of eyes

**Comparison of retrospective observational study findings in Poland, 2013–2017), with a literature review on fungal keratitis in Europe, 2000–2019.** In European countries with a moderate climate, outbreaks of fungal keratitis are much less common than in tropical areas of Asia, Australia or America [4, 5, 19]. The authors of this article have identified 11 epidemiological studies of fungal keratitis in the United Kingdom, France, Switzerland, Denmark, Germany and Ireland, which discussed such aspects as main risk factors, aetiology, patient age and gender, as well as treatment methods. The results are shown in Table 2.

## DISCUSSION

Although several studies of fungal keratitis in Europe have been published, the literature lacks a retrospective analysis of keratomycosis in Poland. Therefore, the aim of this study is to review the causes, presentation, and clinico-pathological associations of fungal keratitis in the Department of Ophthalmology in Katowice, Poland, in 2013–2017, and to compare the findings with previously published studies conducted in Europe in 2000–2019. The main difference here is that the presented study was a single centre study, whereas the other published data is from multicentre studies carried out in Ireland, United Kingdom, Germany, and Denmark [9, 10, 13, 14, 15]. In the current study, as well as in other European countries, the incidence of fungal keratitis was lower than reported by authors from, e.g. China, India or the USA [2, 4, 5]. This is associated with the fact that both in Poland and elsewhere in Europe, e.g. in Germany, United Kingdom, Ireland or Switzerland, fungal infections (including fungal keratitis) are significantly less common than in humid and hot climate zones, where fungi can be responsible for over 50% of all corneal ulcers [6, 20]. Even though fungal keratitis is not as common in Europe as it is in warmer climates. Hon Shing Ong demonstrated an increase of its incidence rate in the United Kingdom, compared to previous years [13]. The mean age of all patients in the current study was 51.5 years. Interestingly, keratitis caused by filamentous fungi was typically diagnosed in younger patients (mean age 47.7 years) than keratitis caused by *Candida spp.* (mean age 57.7 years). The mean age of patients reported in the studies from Denmark, Ireland, UK, Switzerland or France ranged between 47.4–63.7 years. In line with currently presented observations, Nielsen confirmed the presence of filamentous fungi as causal pathogens in keratitis in younger patients (mean age 45 years).

**Table 2.** Summary of fungal keratitis studies in European countries

First author	Country	Year of publication	Period of research	No. of subjects	Most common microbial agent	Main risk factor	Mean age of subjects (years)	Gender (% of females)	Only pharmacological treatment	Surical procedure (penetrating keratoplasty)
Iselin KC	Switzerland	2017	2010–2015	17	<i>Fusarium spp.</i>	Contact lenses	52	Not available	70.59%	23.53%
Nielsen Stine E.	Denmark	2015	2000–2013	25	<i>Candida spp.</i>	Contact lenses previous use of topical steroid	56.4	Not available	48%	52%
Tuff S.J.	United Kingdom	2009	2003–2005	39	<i>Candida spp.</i>	Trauma	56.58	61%	70.6%	29.4%
Bogurad A.	Switzerland	2019	2006–2007. 2015–2016	163	<i>Candida. Fusarium spp.</i>	Contact lenses	Not available	Not available	Not available	Not available
Rondeau N.	France	2002	1993–2001	19	<i>Candida spp.</i>	Previous use of topical steroids	56.2	63.2%	42.1%	26.3%
HON SHING ONG	United Kingdom	2016	2007–2014	112	<i>Fusarium spp.</i>	Contact lenses	47.2	58.9%	69.6%	30.4%
Farell S.	Republik of Ireland	2017	6 years	42	<i>Aspergillus spp.</i>	Ocular Surface disease	47.4	42.9%	73.8%	26.2%
Galaretta David J.	United Kingdom	2007	1993–2007	66	<i>Candida spp.</i>	Ocular Surface disease	63.7	46.1%	53.8%	46.2%
Nielsen E.	Denmark	2013	2011–2012	6	<i>Fusarium spp.</i>	Contact lenses	44.5	50%	50%	50%
Brasu E.	France	2007	Not available	5	<i>Fusarium spp.</i>	Contact lenses	45.2	80%	Not available	Not available
Roth M.	Germany	2019	2000–2017	102	<i>Fusarium spp.</i>	Contact lenses	52	64.3%	25.5%	65.7%

In the presented study, the main causal pathogen were filamentous fungi, especially *Fusarium spp.*, as opposed to yeast, which were found in previous studies [9, 10]. Similarly, Iselin et al. (Switzerland), Hon Shing Ong et al. (United Kingdom), Farell et al. (Ireland), Nielsen et al. (Denmark), Brasnu et al. (France), and Walther et al. (Germany) [8, 9, 13, 14, 17, 21] pointed to filamentous fungi as the main infectious agent, with most cases of fungal keratitis caused by *Fusarium spp.* However, Nielsen et al. in their study of 2015, indicated that most cases of fungal keratitis were caused by yeast, in particular *Candida spp.* This was in line with the studies by Tuft et al. of 2009 (United Kingdom), Rondeau et al. of 2002 (France), and Galaretta et al. of 2007 (United Kingdom).

The main causes of fungal keratitis in the Department of Ophthalmology in Katowice in 2013–2017 were ocular trauma, followed by contact lens wear, ocular surface disorder, and long-term use of topical corticosteroids, whereas in other European countries, contact lens wear predominated, followed by ocular surface disorder, long-term use of topical corticosteroids, and ocular trauma at the end of the list. Only Tuff mentioned ocular trauma as the main risk factor [10]. This difference can be explained by more common use of contact lenses in these countries compared to Poland, linked to their better economic status. Yeast causing fungal keratitis were mostly isolated in patients with known ocular surface disorders, those after previous ocular surgery (especially keratoplasty), and long-term users of topical corticosteroids. This is in keeping with the results of Nielsen et al. in a Danish population, Tuft et al. and Hon Shing et al. in a British population, Farell et al. in an Irish population and Rondeau et al. in a French population [9, 10, 12, 13, 14]. In the current study, *Fusarium spp.* was most often isolated from keratitis associated with ocular trauma and contact lens wear.

In the current study, patients with filamentous infections had significantly worse visual outcomes and were more likely to need a corneal graft than those with *Candida* infections (56% versus 25%). Hon Shing et al. demonstrated similar results in their study conducted in 2007–2014 in a British population [13]. On the contrary, previous studies from Denmark, Ireland, as well as the United Kingdom, indicated a better prognosis in terms of both the ultimate visual acuity and the need for keratoplasty in eyes with fungal keratitis caused by filamentous fungi. Patients with fungal keratitis were treated in the Department of Ophthalmology in Katowice with topical voriconazole, fluconazole and amphotericin B, with additional oral fluconazole in 30 cases. In other European countries, topical natamycine is used, which is unavailable in Poland. Medical treatment was used in all cases and proved to be sufficient in 26 (57.8%) cases. Corneal cross-linking was performed in 7 patients with limited, superficial inflammation (below 250 µm), in whom a complete response to medical treatment was not achieved. Whereas 3 of the patients responded well to CXL and the inflammation resolved, the remaining 4 (57%) patients needed keratoplasty. In the study by Alio et al., 38.5% of patients after previous CXL needed keratoplasty in later treatment [22]. The CXL proved to be more effective in bacterial or protozoan keratitis rather than in fungal infections.

In the presented sample, keratoplasty was eventually performed in 19 eyes (42.2%), more often in cases of keratitis caused by filamentous fungi. In the studies by Iselin et al. (Switzerland), Farell et al. (Ireland), Rondeau et al. (France), and Hon Shing et al. (United Kingdom), the percentage of patients receiving corneal grafts was lower than in the current sample, amounting to 24%, 26.2%, 31.6%, and 24.1%, respectively [8,12,13,14]. Nielsen E (Denmark) and Galaretta

DJ et al. (United Kingdom), however, reported higher keratoplasty rates (52% and 46.2%, respectively) than in the current study [9, 15]. In the Department of Ophthalmology in Katowice, more keratoplasties were performed in patients with infections caused by filamentous fungi than by yeast.

Currently, confocal microscopy, a non-invasive method which enables an *in vivo* histological assessment of individual corneal layers and detection of filaments or oval cells indicative of yeast origin, plays an important role as a diagnostic investigation method in fungal keratitis. In the presented sample, the diagnosis of fungal keratitis was based on confocal microscopy findings in 43 cases (95.6%), as opposed to microbial analyses, which confirmed the diagnosis in 55.6% of patients. These findings are contradictory to those by Brasnu, who found that confocal microscopy offered equal sensitivity to the direct microscopic evaluation or microbial cultures [17].

This study has several limitations. It provides a retrospective review of clinical data from a single centre as opposed to other papers published elsewhere in Europe which analysed data from several centres in one country. Nevertheless, it is the first study to analyse diagnosis, treatment and risk factors for fungal keratitis in Poland. A small number of patients were included in this observational study, although records covering a period of 5 years were collected. There is a need to continue research of aetiology, diagnostic and therapeutic management of fungal keratitis in Poland, as well as to compare data from a larger number of Polish ophthalmology departments.

## CONCLUSION

Fungal keratitis poses a therapeutic challenge due to poor prognosis, low number of available treatments, and poor ocular penetration, as well as difficult and expensive diagnostic investigations. Despite unfavourable treatment outcomes, early accurate diagnosis followed by intensive antifungal treatment can prevent vision loss.

## REFERENCES

1. Chang HY, Chodosh J. Diagnostic and therapeutic considerations in fungal keratitis. *Int Ophthalmol Clin*. 2011; 51: 33–42.
2. Gopinathan U, Sharma S, Garg P, Rao GN. Review of epidemiological features, microbiological diagnosis and treatment outcome of microbial keratitis: experience of over a decade. *Indian J Ophthalmol*. 2009; 57: 273–279.
3. Lam DS, Houang E, Fan DS, Lyon D, Seal D, Wong E. Incidence and risk factors for microbial keratitis in Hong Kong: comparison with Europe and North America. *Eye (Lond)*. 2002; 16(5): 608–18.
4. Keay LJ, et al. Clinical and microbiological characteristics of fungal keratitis in the United States, 2001–2007: a multicenter study. *Ophthalmology*. 2011; 118(5): 920–6.
5. Leck AK, Thomas PA, Hagan M. Aetiology of suppurative corneal ulcers in Ghana and south India, and epidemiology of fungal keratitis. *Br J Ophthalmol*. 2002; 86(11): 1211–1215.
6. Tilak R, Singh A, Maurya OP, Chandra A, Tilak V, Gulati AK. Mycotic keratitis in India: a five-year retrospective study. *J Infect Dev Ctries*. 2010; 4(3): 171–4.
7. Walkden A et al. Association Between Season, Temperature and Causative Organism in Microbial Keratitis in the UK. *Cornea*. 2018; 37(12): 1555–1560.
8. Iselin KC, Baenninger PB, Schmittinger-Zirm A, Thiel MA, Kaufmann C. Fungal keratitis: A Six-Year Review at a Tertiary Referral Centre. *Klin Monbl Augenheilkd*. 2017; 234(4): 419–425.
9. Nielsen SE, et al. Incidence and clinical characteristics of fungal keratitis in a Danish population from 2000 to 2013. *Acta Ophthalmol*. 2015; 93(1): 54–8.
10. Tuft SJ, Tullo AB. Fungal keratitis in the United Kingdom 2003–2005. *Eye (Lond)*. 2009; 23(6):1308–13.
11. Bograd A, Seiler T, Droz S, Zimmerli S, Früh B, Tappeiner C. Bacterial and Fungal Keratitis: A Retrospective Analysis at a University Hospital in Switzerland. *Klin Monbl Augenheilkd*. 2019
12. Rondeau N, et al. Fungal keratitis at the Centre Hospitalier National d'Ophtalmologie des Quinze-Vingts: retrospective study of 19 cases. *J Fr Ophtalmol*. 2002; 25(9): 890–6.
13. Hon Shing Ong, et al. Altered Patterns of Fungal Keratitis at a London Ophthalmic Referral Hospital: An Eight-Year Retrospective Observational Study. *Am J Ophthalmol*. 2016; 168: 227–236.
14. Farrell S, McElnea E, Moran S, Knowles S, Murphy CC. Fungal keratitis in the Republic of Ireland. *Eye (Lond)*. 2017; 31(10): 1427–1434.
15. Galarreta DJ, Tuft SJ, Ramsay A, Dart JK. Fungal keratitis in London: microbiological and clinical evaluation. *Cornea*. 2007; 26(9):1082–6.
16. Nielsen E, Heegaard S, Prause JU, Ivarsen, A, Mortensen KL, Hjortdal J. Fungal Keratitis – Improving Diagnostics by Confocal Microscopy. *Case Rep Ophthalmol*. 2013; 4:303–310.
17. Brasnu E, et al. In vivo confocal microscopy in fungal keratitis. *Br J Ophthalmol*. 2007; 91: 588–591.
18. Roth M, et al. The German keratomycosis registry: Initial results of a multicenter survey. *Ophthalmologe*. 2019
19. Chew R, Woods ML. Epidemiology of fungal keratitis in Queensland, Australia. *Clin Exp Ophthalmol*. 2019; 47(1): 26–32.
20. Bharathi MJ, Ramakrishnan R, Vasu S, Meenakshi R, Palaniappan R. Epidemiological characteristics and laboratory diagnosis of fungal keratitis. A three-year study. *Indian J Ophthalmol*. 2003; 51(4): 315–21.
21. Walther G, et al. Fusarium Keratitis in Germany. *J Clin Microbiol*. 2017; 55(10): 2983–2995.
22. Alio JL, Abbouda A, Valle DD, Del Castillo JM, Fernandez JA. Corneal cross linking and infectious keratitis: a systematic review with a meta-analysis of reported cases. *J Ophthalmol*. 2013; 3(1):47.