

The use of percutaneous abdominal ultrasound examination in diagnosing equine small intestinal disorders

A. Porzuczek¹, Z. Kielbowicz¹, G. Haines²

¹ University of Environmental and Life Sciences, Faculty of Veterinary Medicine, Surgery Clinic, pl. Grunwaldzki 51, 50-366 Wrocław, Poland

² Dubai Equine Hospital, Dubai, United Arab Emirates

Abstract

In equine field practice, the diagnosis of small intestinal disorders is usually based on the presence of distended loops on rectal palpation and large volumes of reflux obtained after the passage of a nasogastric tube.

Percutaneous abdominal ultrasound examination has been widely utilized in both human and small animal internal medicine in most cases of gastrointestinal discomfort. The purpose of this study was to identify which measurable parameters were important in reaching a diagnosis of small intestinal abnormality and determining treatment options. Horses of various age, sex and breed were involved in this research. Identifying the number of areas where distended loops of small intestine (SI) were detected, their diameter in cross section and motility were the most important parameters identified when formulating a prognosis.

Key words: horse, ultrasound examination, intestinal disorders

Introduction

Rectal examination, a basic diagnostic tool in horses with colic, is limited to only 30-40% of the peritoneal cavity due to the large size of the equine abdomen (Mueller et al. 2000). Percutaneous ultrasonography provides valuable additional information about the abdominal organs in a noninvasive manner (Scharner et al. 2002, Reef et al. 2004). To reach a clinical diagnosis in colic cases, physical, rectal, and ultrasound examinations, nasogastric intubation, haematological and biochemical tests and abdominocentesis may be performed. Sonographic examination can easily be performed and may act as an important com-

ponent in evaluation of horses showing signs of colic. Percutaneous ultrasonography provides additional information relating to the presence of intestinal motility or the visualization of parts of the abdomen that are inaccessible by rectal palpation (Scharner et al. 2002). It is also an invaluable diagnostic tool for individuals that can't undergo rectal examination (size of the individual or facility restrictions, history of rectal bleeding or tear, excessive straining, aggressive or unsafe behavior).

Small intestinal disorders in horses may be of a variable origin but they are usually considered as ileus – mechanical (obturation, strangulation) or functional (spasmodic, paralytic). In early stages of the

disease, distended loops may not be palpable on rectal examination. In some forms of strangulation (for example caused by mesodiverticular bands, epiploic foramen entrapment), the degeneration of the intestinal wall may already be manifested without distended loops being identified by rectal palpation. The specific diagnosis of SI strangulation may not be identified in the early stages based solely on rectal examination. Concurrent distention of the cecum and/or large colon may also make it difficult to identify distended loops of small intestine. Changes in small intestinal shape, motility, their location, and abnormal diameter can be detected with sonography in the early stages of disease. Distention is defined when the diameter exceeds 5 cm, wall oedema when the wall thickness is over 3 mm. The most common locations for identifying strangulated small intestine are the lower flank regions and ventral abdomen (Scharner et al. 2002). The purpose of this study was to identify which measurable parameters (SI loops diameter in cross section, SI motility, number of areas where distended loops of SI were visualized, SI wall thickness) are of the greatest value in diagnosing small intestinal disorder in horses.

Materials and Methods

A total of 145 horses from the patient records of the Dubai Equine Hospital (Dubai, United Arab Emirates) with signs of acute abdominal pain were examined and represented 148 clinical cases. 15.54% (22 horses and 23 cases) had small intestinal disorders, 73.65% large intestinal abnormalities. In fourteen cases, a specific diagnosis was not reached. However, these horses did not require long-term treatment.

Initially, each horse was subjected to a routine colic examination which consisted of a physical exam, rectal palpation, nasogastric intubation and percutaneous ultrasound examination. For horses that were too painful to safely perform a complete physical examination, transabdominal ultrasound was usually performed after sedation.

Complete evaluation of the adult equine abdomen requires deep tissue penetration and a low frequency ultrasound transducer. Percutaneous ultrasound examination was performed with a convex probe of frequency 2.5-3.5 MHz, and the depth of penetration varied from 10-25 cm. The hair coat wasn't clipped, only the skin soaked with isopropyl alcohol. Time of examination varied between 5-15 minutes. The procedure was well tolerated. The examination was performed in systematic approach (protocol):

1) 6th-17th intercostal spaces of the right side

(number of the space R)

2) right flank – dorsal (RD)

3) right flank – ventral (RV)

4) ventral abdomen – viewed from the right side of midline

a) cranial to the umbilicus (V1R)

b) caudal to the umbilicus (V2R)

5) 6th-17th intercostal spaces of the left side (number of the space L)

6) left flank – dorsal (LD)

7) left flank – ventral (LV)

8) ventral abdomen – viewed from the left side of midline

a) cranial to the umbilicus (V1L)

b) caudal to the umbilicus (V2L)

The parameters of the ultrasonographic research that have been subjected to evaluation in the present study were:

- shape of SI loops in cross-section,
- diameter of SI loops (when their shape was round in cross-section),
- SI motility,
- number of areas where distended loops of SI were identified,
- small intestinal wall thickness,
- presence/absence of sedimentation of ingesta inside SI lumen.

Results

Normal loops of small intestine on examination of horses with abnormalities in other parts of the gastrointestinal tract were usually visible in areas RV, V1 and V2 (Fig. 1). In cross section, they were mostly triangle-shaped with the lumen visible only in the stage of distention (relaxation). Some diseases of the large intestine (impactions and displacements) resulted in varying degrees of small intestinal distention but peristalsis was always visible. Their shape in cross-section was usually oval with the lumen transparently detectable (Figs. 2, 3, 4). The most common areas of visualization were also RV, V1 and V2. The highest measurements were 6.78 cm x 5.94 cm.

In this study, the diagnosis of SI disorders was confirmed during surgical exploration of the abdomen (18 horses) or the resolution of clinical signs followed by changes in ultrasonographic appearance (5 horses). The shape of small intestinal loops on ultrasonographic examination of all these horses was round in cross-section (Figs. 5, Fig. 6). Therefore, the measurement of their diameter was possible to perform. For patients treated medically it varied from 2.82 cm – 5.41 cm (mean 4.38 cm), for horses that underwent exploratory laparotomy the measurements were

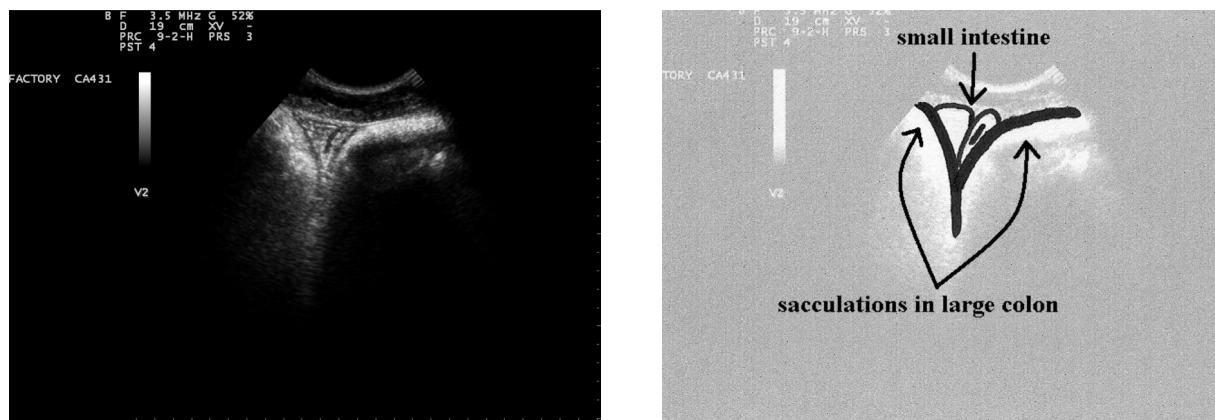


Fig. 1. Normal loops of small intestine visible between the sacculations of the large colon. Image from the caudal part of the ventral abdomen.

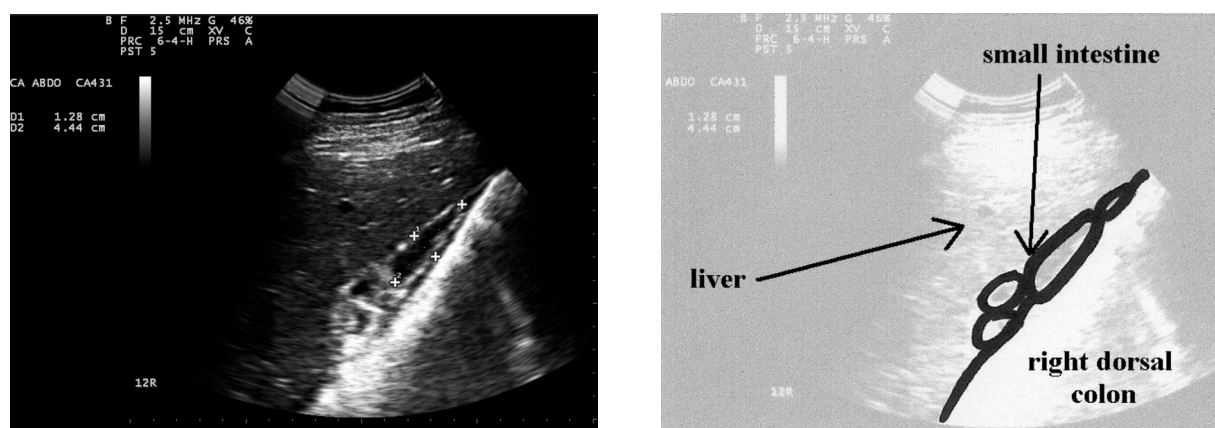

Fig. 2. Slightly distended small intestinal loops in a horse with a large colon impaction. Image obtained in 12th right ICS.

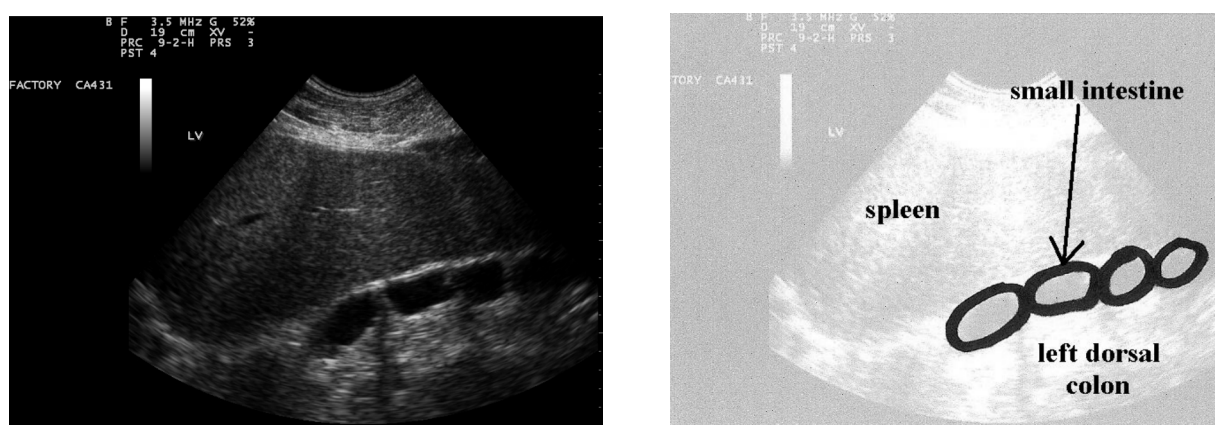


Fig. 3. Medium distention of small intestine in a horse with large colon impaction. Image obtained in lower part of the left flank.

5.0 cm – 6.77 cm (mean 5.5 cm). The second parameter most influenced by small intestinal disorders was motility which was either compromised or absent (Fig. 7). The number of areas where the loops were identified changed significantly for these horses (Fig. 8). The most common areas remained RV, V1,

V2 but others were more frequently involved (RD, LV, LD, left and right intercostal spaces). Pearson's correlation between this two parameters in group of horses with confirmed SI disease confirmed the existence of high dependence.

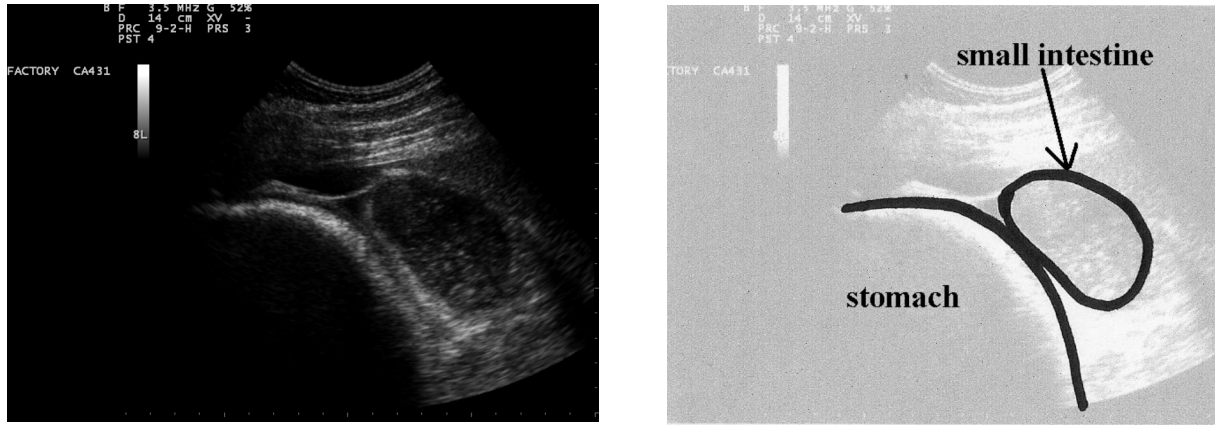


Fig. 4. Grossly distended loop of small intestine in a horse with large colon impaction. Image obtained in the 8th left intercostal space.

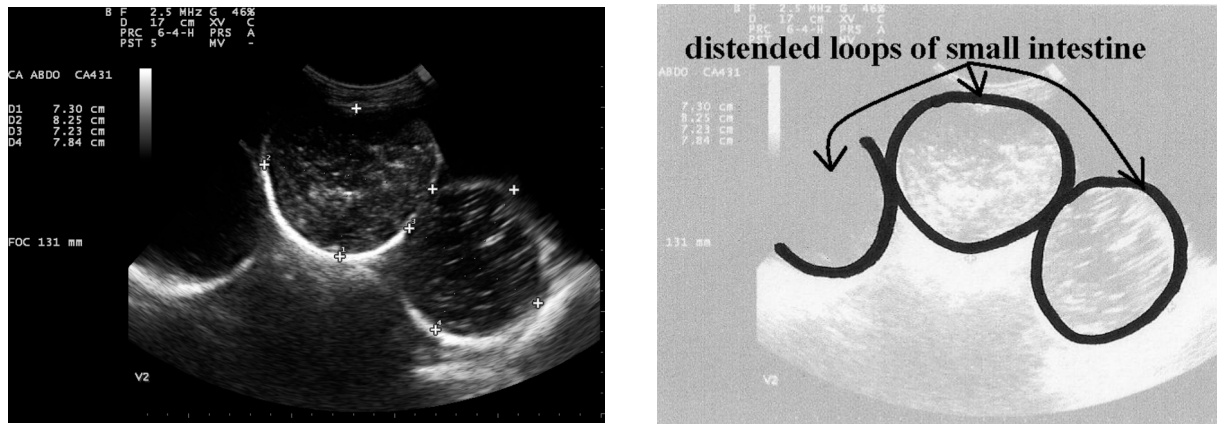


Fig. 5. Amotile, distended prestenotic SI loops. Image obtained in the caudal part of the ventral abdomen.

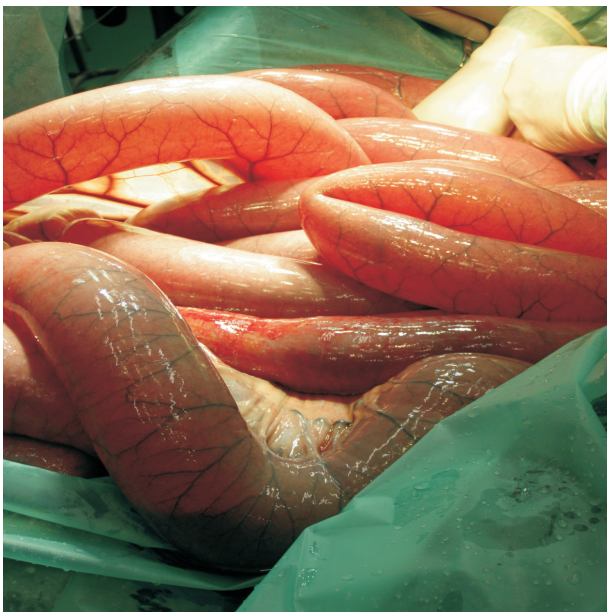


Fig. 6. Intraoperative image of distended, amotile loops of SI.

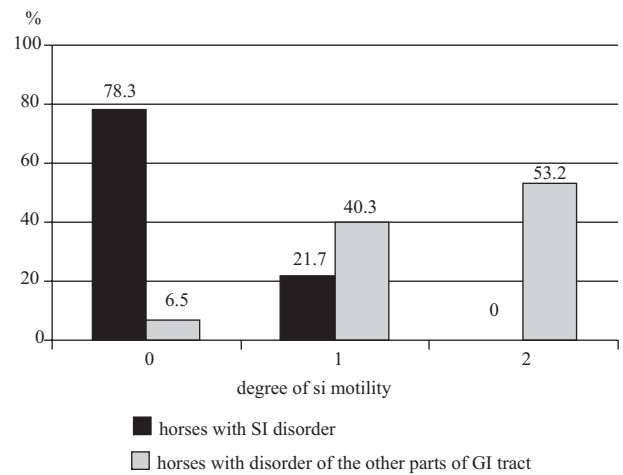


Fig. 7. The motility of small intestine detected by ultrasound. 0 – amotile, 1 – decreased motility, 2 – normal motility.

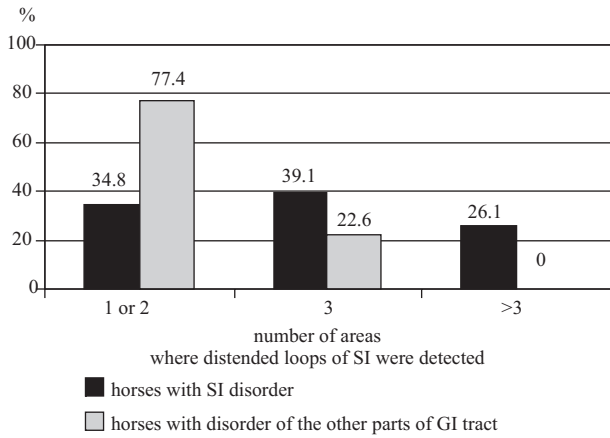


Fig 8. The dependance between number of areas where distended loops of small intestine were identified and part of GI tract which disorder was responsible for signs of acute abdomen.

humanely euthanized. In the later two horses, necrotic loops of small intestine were confirmed during surgery. Sedimentation of ingesta was seen in 1 horse treated medically (post exhaustion ileus) and 3 treated by exploratory laparotomy (Fig. 10). Two of the horses treated surgically required intestinal resection due to bowel necrosis.

It is believed to be an incidental finding when small intestine is visible between the spleen and left kidney. In one case, distended, amotile loops were visible in this area. Exploratory laparotomy confirmed the entrapment of small intestine in the nephrosplenic space and 1.5 meters of compromised bowel had to be resected.

Jejuno-jejunal intussusception was confirmed surgically in one case. The characteristic “bull’s eye” image was obtained on ultrasonographic examination of

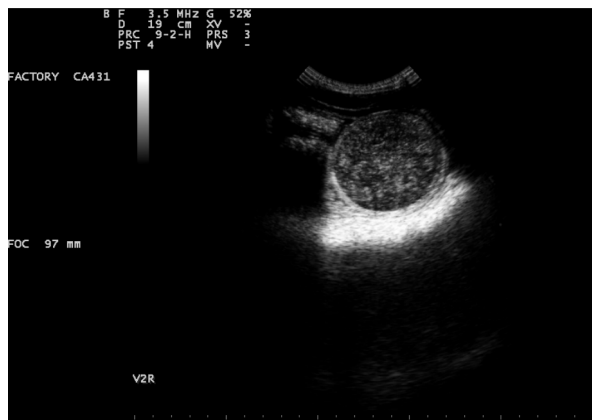

Fig. 9. SI wall oedema.

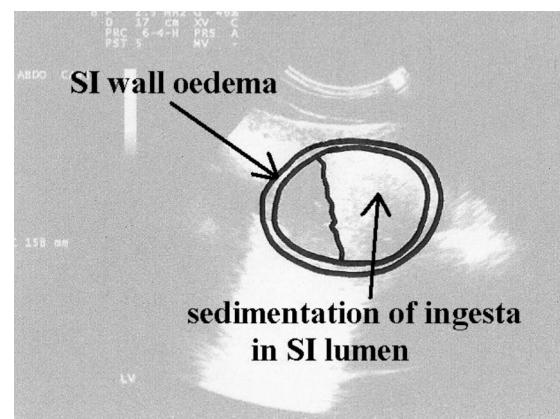
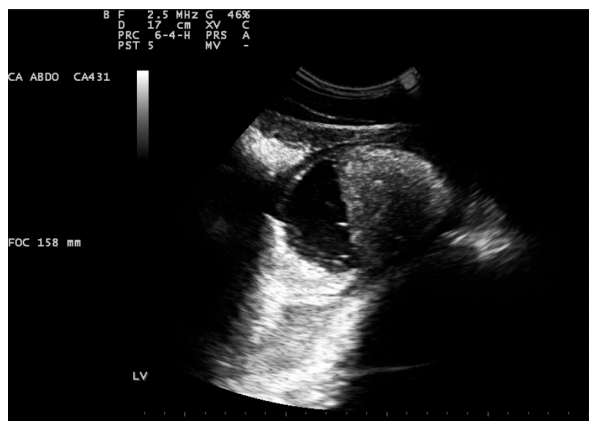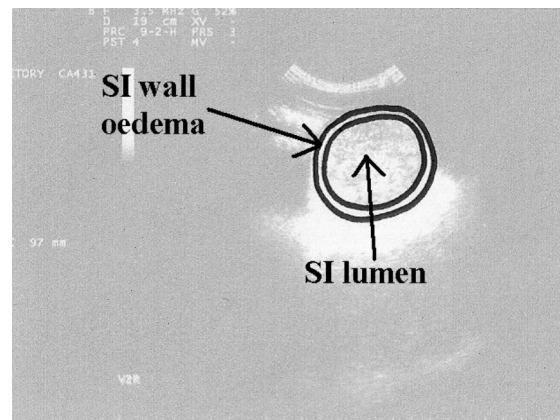


Fig. 10. Sedimentation of ingesta in SI lumen. Dorsal is to the left, ventral to the right.

Wall oedema was observed in 6 horses that had a small intestinal lesion requiring surgical treatment (Fig. 9). The measurements were 4.4 mm – 7.1 mm. Two of these horses didn’t require bowel resection and recovered well from surgery. From the remaining 4, 2 cases required resection and the other 2 were

this horse. This term was first introduced in human medicine and transferred to veterinary diagnostics (Montali G. et al. 1983). It has been noted that ultrasound is the only available preoperative diagnostic tool leading to this specific diagnosis.

Two horses had an epiploic foramen entrapment.

Table 1. Clinical data of horses with confirmed small intestinal disorder.

No.	Clinical number of horse	Age (years)	Sex	Breed	Temperature (in °C)	Heart rate	Respiratory rate	Rectal Examination (palpable SI loops: yes/no/exam not performed)	Nasogastric tube (reflux in liters)	Treatment (m – medical, s – surgical)	Diagnosis
1	119	11	G	O	37.4	48	16	no	8	m	post exhaustion ileus
2	19	11	G	OO	38.2	84	20	yes	12	m	duodenitis-proximal jejunitis
3	76	4	St	OO	37.5	60	30	yes	8	m	post exhaustion ileus
4	113	8	G	X	37.8	52	22	yes	16	m	duodenitis-proximal jejunitis
5	60	3	St	OO	37.7	48	16	no	4	m	SI adhesion
6	2A	2	St	OO	37.3	30	9	yes	0	s	mesodiverticular band
7	2B	2	St	OO	37.7	50	18	yes	6	s	impaction on the anastomosis site
8	145	3 months	M	OO	37.8	64	36	np	6	s	jejuno-jejunal intussusception
9	105	10	M	OO	37.3	40	20	yes	5	s	volvulus nodosus
10	114	13	G	OO	37.4	48	10	yes	3	s	volvulus nodosus
11	116	9	G	OO	37.8	44	14	no	16	s	volvulus nodosus
12	125	10	M	OO	37.8	66	20	no	3	s	volvulus nodosus
13	135	7	St	OO	–	–	–	np	3,5	s	volvulus nodosus
14	129	9	St	WB	37.0	48	20	yes	2	s	inguinal hernia
15	138	7	St	OO	37.3	28	12	yes	0	s	inguinal hernia
16	141	9	St	OO	37.0	36	16	yes	2	s	inguinal hernia
17	79	9	G	OO	38.0	36	12	no	6	s	epiploic foramen entrapment
18	81	4	St	OO	37.2	48	12	no	8	s	epiploic foramen entrapment
19	89	2	St	OO	36.8	36	12	yes	0	s	mesodiverticular band
20	61	7	M	X	38.8	54	36	yes	1,5	s	diaphragmatic hernia
21	63	6	M	WB	37.5	42	16	yes	5	s	herniation through the cecocolic fold
22	69	3	M	XX	37.7	46	12	no	0	s	nephrosplenic entrapment
23	87	18	M	OO	37.2	48	20	yes	24	s	lipoma pendulans

Sex: St – stallion, G – gelding, M – mare. Breed: OO – Arabian, O – Part Arabian, XX – Thoroughbred, X – Part Thoroughbred, WB – Warmblood.

Dilated, atonic loops of small intestine were detected on ultrasound examination in areas V1, V2, RD and RV. Some authors claim that this localization primarily on the right side of the abdomen is typical for this form of entrapment due to the topography of the epiploic bursa (Scharner et al. 2002).

The diagnosis of inguinal herniation was aided by ultrasound examination and confirmed during

exploratory laparotomy in three horses. Distended loops of SI were always visible around the testicular stroma of the affected side.

Discussion

Small intestine was observed in various locations during transabdominal ultrasound examination of

horses with different gastrointestinal disorders. The most common area of visualization of pathologic loops was the most ventral portion's of abdomen. This was similar to what had previously been reported (Klohn et al. 1996). Traditional examination of the horse with an acute, painful abdomen is based on physical and rectal examinations. For small intestinal abnormalities, a diagnosis is made when distended loops are palpable per rectum and/or the attainment of gastric reflux. In this study, a positive rectal examination result was reached in 14 horses with confirmed SI abnormality (60.9%). In 6 other cases (26.1%), the only findings were large colon and/or cecum gas distention or a full urinary bladder. In 3 horses (13%), rectal palpation wasn't performed because of excessive pain, a history of rectal bleeding, or because of the small size of the individual. In 39.1% of cases of SI disorder, the diagnosis couldn't be reached based on rectal findings. Other authors have reported rectal palpation to be an efficient diagnostic tool in 50% (Klohn et al. 1996) to 90% (Scharner et al. 2002) of horses with SI disorders.

In only 11 horses with small intestinal disorders (47.8%) did the passage of a nasogastric tube result in 6 or more liters of gastric reflux. None of these horses had stomach decompression less than 3 hours prior to referral. Medium volume of gastric reflux was higher for horses that didn't require surgical intervention (9.6 liters versus 5.05 liters). However, for horses that underwent exploratory laparotomy, the maximum volumes were higher (24 liters versus 16 liters). This difference correlated well with the varying degrees of gastric distention noted on ultrasound examination. For horses treated medically, the greatest curvature of the stomach was observed between the 13th and 16th left intercostal spaces. In patients with surgical lesions, this curvature was observed from the 10th intercostal space to the left flank. It is possible that medically treated horses were dealing with primary inflammation rather than a physical obstruction. Due to abnormal secretion, the inflamed bowel produced constant amounts of fluid which stayed within the lumen and moved antiperistaltically to the stomach. Surgical strangulation lesions may not provide large volumes of fluid moving toward the stomach if they are examined early or have much higher volumes if examined late in the course of the colic. In our experience, many surgical horses have distal lesions. Thus, fluid accumulation had not physically had enough time to reach the stomach due to the long distances involved. Transabdominal ultrasound examination is of great diagnostic value, especially for cases of relatively short duration. Distended SI loops with compromised or absent motility are usually observed in the early stages of disease in the absence of significant gastric reflux.

In one study (Klohn et al. 1996), the small intestinal ultrasonographic parameters that appeared important in determining the need for surgical intervention included an increased diameter in cross sectional appearance, increased wall thickness, and decreased motility. The analysis of 226 horses hospitalized due to an acute abdomen demonstrated that the visualization of amotile loops of SI with a thickened wall was a significant reason for performing an exploratory laparotomy. In our study, the term of diameter was used only for amotile or hypomotile loops which appeared rounded on cross section. This measurement was higher for horses treated surgically (mean 5.5 cm) than for those treated medically (mean 4.38 cm). A complete lack of visible motility was detected most frequently in horses that underwent an exploratory laparotomy (77.7%) versus those that did not (60%). The need for surgery was also increased by the number of areas where distended loops were identified on abdominal ultrasound examination. This measurement was also significantly higher for horses that required small intestinal resection. Small intestinal wall thickness appeared to be of lower value than for large intestinal disorders. According to some authors (Klohn et al. 1996), this measurement may not be accurate due to its small size (less than 3 mm). Others claim that slight changes in wall thickness measurements are less valuable as the intestinal wall is not a straight line and the examination isn't usually performed with a linear transducer due to the high penetration depth required. Given the small distances involved in a measurement of wall thickness, significant luminal distention may further compromise the ability to get an accurate measurement. Perhaps only a significant increase in wall thickness is of great diagnostic value (Scharner et al. 2002). Ten of 12 horses which required resection (from 0.2 m to 14.0 m) had SI wall thickness below 4 mm. The appearance of wall oedema was a poor prognostic sign but did not always indicate a need for resection. However, it can be a sign that surgical treatment is required. The sedimentation of ingesta within the intestinal lumen was observed in 4 cases, one of which was a post-endurance ileus that was successfully managed medically. The other authors claim that visualisation of distended, amotile SI loops with thickened wall provides sensitivity, specificity and positive and negative values of 100% in cases of SI strangulation (Scharner et al. 2002).

The most accurate diagnostic parameters in determining the need for surgical intervention were the number of areas where distended loops of small intestine were visualized, decreased or absent motility, the degree of distention and shape. Increased wall thickness and sedimentation of ingesta were less important

but should always be considered as a negative prognostic sign. The use of this protocol in diagnosing and determining the therapy for horses with small intestinal disorders likely resulted in higher survival rates than in previous studies. The short-term survival rates following surgical correction of SI disorders was claimed to be 66% (Baxter et al. 1989) to 75.2% (Mair et al. 2005). In our study, 83% horses treated surgically survived at least 10 days and 78% greater than 6 months.

In cases of functional ileus, ultrasound examination enabled continued monitoring during conservative therapy and decreased the need to perform invasive procedures such as passage of a nasogastric tube. This may also be beneficial economically as well as therapeutically. Expensive pharmacologic treatment may be able to be discontinued earlier. Other authors have proven this method to be of great value in monitoring post-operative ileus (Holcombe 2003).

Summary

Only a small portion of the equine abdomen can be palpated per rectum. Ultrasound examination provides important additional information about the abdominal viscera. It is a valuable diagnostic tool for specific cases. Percutaneous abdominal ultrasound examination enables clinicians to gain valuable diagnostic information quickly and noninvasively.

Significantly higher surgical rate was observed when the small intestine was rounded on cross-section. This appearance was associated with a lack of progressive motility and increased distention. Wall oedema and visible sedimentation within the bowel's lumen were also negative prognostic findings. Overall,

the most sensitive surgical indicator was the number of areas where amotile loops were observed. Only 60.9% of horses with small intestinal abnormalities had palpable distended loops on rectal examination.

Acknowledgements

The authors would like to thank doctor Guy Alexander from Canterbury Equine Clinic, Christchurch, New Zealand for his invaluable contribution to this paper.

References

- Baxter GM, Broome TE, Moore JN (1989) Abdominal Adhesions after Small Intestinal Surgery in the Horse. *Vet Surg* 18: 409-414.
- Holcomb SJ (2003) Monitoring gastrointestinal function in the equine ICU. *Clin Tech Equine Pract* 2: 156-164.
- Klohn A, Vachon AM, Fischer AT Jr (1996) Use of diagnostic ultrasonography in horses with signs of acute abdominal pain. *J Am Vet Med Assoc* 209: 1597-1601.
- Mair TS, Smith LJ (2005) Survival and complication rates in 300 horses undergoing surgical treatment of colic. Part 1: Short-term survival following a single laparotomy. *Equine Vet J* 37: 296-302.
- Montali G, Croce F, De Pra L, Solbiati L (1983) Intussusception of the bowel: a new sonographic pattern. *Br J Radiol* 56: 621-623.
- Mueller E, Moore JN (2000) Rectal examination of horses with acute abdominal pain. *Comp Cont Educ Pract Vet* 22: 606-615.
- Reef VB, Whittier M, Allam LG (2004) Sonographic Evaluation of the Adult Abdomen. *Clin Tech Equine Pract* 3: 294-307.
- Scharner D, Rotting A, Gerlach K, Rasch K, Freeman DE (2002) Ultrasonography of the Abdomen in the Horse with Colic. *Clin Tech Equine Pract* 1: 118-124.