

# Calf strain resulting in deep venous thrombosis – a case study

Marta Tomczyńska-Mleko<sup>1</sup>, Wioletta Żukiewicz-Sobczak<sup>2</sup>, Stanisław Mleko<sup>3</sup>, Agnieszka Dylewska<sup>3</sup>

<sup>1</sup> Institute of Plant Genetics, Breeding and Biotechnology, University of Life Sciences in Lublin, Poland

<sup>2</sup> Department of Allergology and Environmental Hazards, Institute of Rural Health in Lublin, Poland

<sup>3</sup> Department of Biotechnology, Human Nutrition and Food Commodity Science, University of Life Sciences in Lublin, Poland

Tomczyńska-Mleko M, Żukiewicz-Sobczak W, Mleko S, Dylewska A. Calf strain resulting in deep venous thrombosis – a case study. *J Pre-Clin Clin Res.* 2013; 7(2): 129–132.

## Abstract

**Introduction.** Deep venous thrombosis (DVT) of the leg is a frequent clinical problem that afflicts thousands of people each year. However, little is known about DVT formation after muscle injury. The purpose of this study was to investigate an unusual case of DVT in Polish male patient and assess the risks factors for DVT.

**Methods.** Deep vein thrombosis was diagnosed in a patient by compressions ultrasound with Doppler; atrial fibrillation was verified with electrocardiography. All standard risk factors were also assessed in examination of the medical and social history of patient.

**Results.** The study showed that a recent major trauma, atrial fibrillation, air travel ('economy class syndrome'), vigorous exercise, and warm water bathing were the probable factors for developing thrombosis in the patient. There was no recanalization of the affected venous segments after 24 days follow-up period.

**Conclusions.** This case study supports the opinion that careful verifying, medical and social history and clinical reasoning in all patients with limb pain are very important in good assessment of thrombosis, as in even young, apparently healthy patients, thromboembolism can occur. Failure of the physician to recognize a vascular injury can elicit many complications and even cause sudden death. It is especially important in rural areas because farm work increases risks of legs injuries.

## Key words

thrombosis, leg injury, atrial fibrillation, calf strain, exercise

## INTRODUCTION

Thrombosis is a major cause of morbidity and mortality in Western countries [1]. Many chronic diseases, such as cardiovascular or diabetes, increase thrombotic risk in individuals [1, 2]. Morbidity of patients with deep venous thrombosis (DVT) is frequent even years after the initial event [3]. The occurrence and associated complications of thrombosis are likely to highly increase in the future in the face of aging populations [2]. Unfortunately, up to 40% [4] or even 50% [5] of patients with DVT develop the post-thrombotic syndrome (PTS). PTS is often defined as signs of chronic venous insufficiency (CVI) secondary to DVT of the lower limbs [3]. PTS consist leg pain, oedema, venous ectasia, skin induration, and ulceration, and PTS is usually established within the first two years after the acute thrombotic incident [5]. Regression of an acute DVT lasts at least 9 months, so this is very slow process [6].

The risk factors for DVT are often mentioned in medical reviews. There are three classical risk factors, known as Virchows triad – vessel wall injury, venous stasis and clotting abnormalities [7, 8]. Usually, two of these factors are sufficient for thrombus formation [8]. However, to assess the probability of DVT, the physician should ask the patient if other causative factors appeared. The following increase the risk of having a DVT:

- immobility due to recent surgical operation;
- illnesses or injuries that required bed-resting;

- long journeys by plane in a cramped position;
- inherent risk factors (e.g. factor V leiden);
- previous vascular problems;
- major trauma;
- obesity; pregnancy;
- older age;
- contraceptive pill therapy;
- malignancy;
- smoking;
- severe dehydration, etc. [7, 8, 9].

Unfortunately, little is known about DVT formation after muscle injury. Moreover, as DVT affects adults at every age, it should be taken into much higher consideration. Adequate medical assessment of a DVT incident and estimation of risk factors are also the key in such cases. 60–70% of thrombosis proceed without any symptoms, and only in 25% of patients with subjective symptoms DVT is stated [8].

The objectives of this study were to present the case of Polish male patient with diagnosed DVT and assess his risk factors for DVT incidence. Physician can benefit greatly from the presented case report in this rarely researched subject.

## MATERIAL AND METHODS

The report was elaborated from the medical history and records of a Polish patient thanks to his prior consent. The subject of the study was a trained 42-year-old male. He trained regularly five days a week. His daily training programme was as follows:

Address for correspondence: Marta Tomczyńska-Mleko, Institute of Plant Genetics, Breeding and Biotechnology, University of Life Sciences in Lublin, Poland  
e-mail: martamleko@tlen.pl

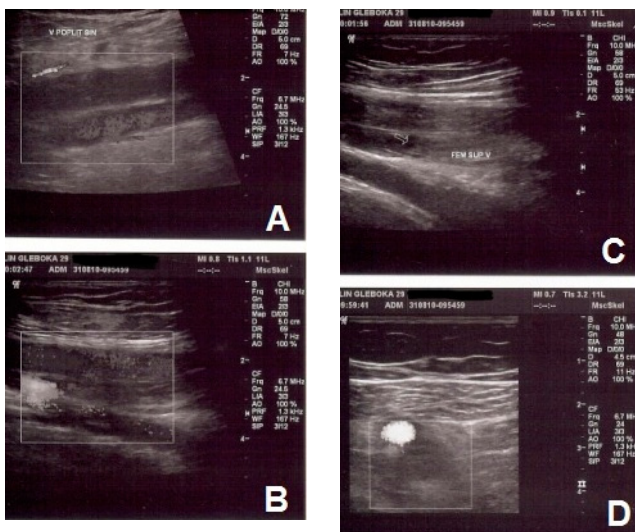
Received: 28 October 2013; accepted: 04 February 2014

- 30 minutes of resistance training: 2 muscle groups for 3 exercises for 3 sets with 8–10 movements;
- 30 minutes on a stationary bicycle with fat combustion pulse;
- 30 minutes spent in a jacuzzi.

On one occasion after such an exercise session, while running in a hurry, he sustained a major injury of a calf. He suffered from the sudden onset of acute left-sided calf pain. He also noted swelling and the affected leg was unable to bear weight. Unfortunately, on that day he was en route from Canada to Poland. He travelled without the possibility to elevate the leg, nor apply ice compress during the flight. No compressive bandage was supplied.

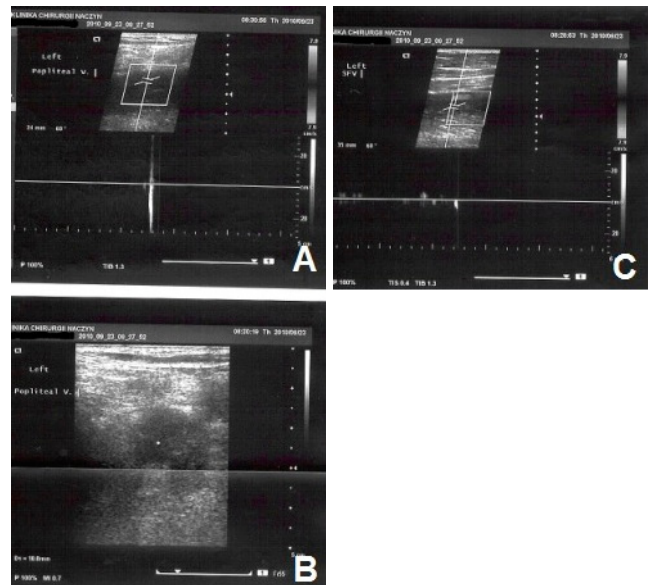
During the subsequent days, he noted further swelling of the left calf, and haematoma above the Achilles tendon. Suffering from permanent pain, he tried to walk accordingly, and became increasingly concerned that the swelling of the lower limb was not reducing in size. During the night of the 12<sup>th</sup> day after sustaining the injury, an increase in the limb oedema was observed, together with an intensification of pain.

Eventually, he was transported to hospital where he was clinically diagnosed with a possible traumatic deep vein thrombosis (DVT), and sent for confirmatory tests. A compressions ultrasound with Doppler was positive for DVT in the left lower limb. The scan revealed the presence of significant thrombus formation in the femoral, peroneal and popliteal regions, together with small clots in the veins of the calf (Fig. 1). Haematoma was observed at the site of the rupture of the gastrocnemius muscle.



**Figure 1.** Ultrasound scan after 12 days from injury. Blood clots (lighter spots) are observed inside of the veins of the popliteal (A), peroneal (B) and femoral (C) regions. Hematoma (white round spot) is observed in the place of the rupture of the gastrocnemius muscle (D)

The patient was admitted for anticoagulation (heparin, acenocumarole to retain INR in the range of 2–3). Upon discharge from hospital the patient continued anticoagulation. 24 days later, the physician did not note any recanalization (Fig. 2). Patient had developed post-thrombotic syndrome and complained of continuous muscle cramps.

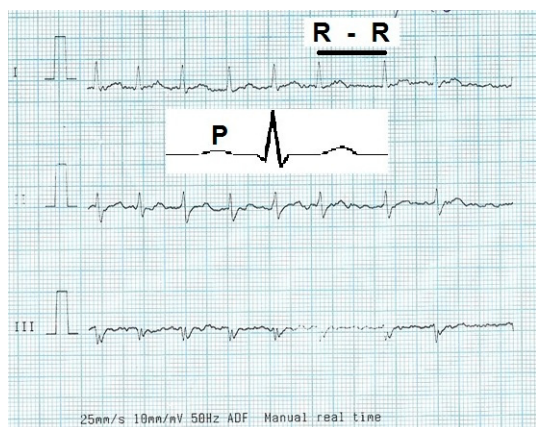


**Figure 2.** Ultrasound scan after 24 days follow-up period. Blood clots (lighter spots) are observed inside of the veins of the popliteal (A), femoral (B) and peroneal (C) regions

## RESULTS AND DISCUSSION

Trauma is one of the most common causes of lower limb DVT [9], and in the presented study was the main factor for thrombus formation in the patient. After a calf contusion, with an acute pain, the patient tried to remain in a stable position. The situation became worse when he took a seat in the plane and travelled in a cramped position without leg elevation. As noted before, long distance travel by plane is one of the common risk factors for DVT. All these circumstances triggered conditions for venous stasis. After major trauma, the body stimulates the healing and inflammatory process; clotting factors are mobilized to stop bleeding and to release of fibrin in order to form a wound or a scar. These factors are therefore evoked after trauma as a part of the healing process [7]. In the current case study, the patient observed swelling that increased gradually, which was the effect of clotting dysfunction. It is not known whether vessel wall injury appeared after the muscle injury. Damaged muscle tissue, or even the compressive effects of oedema, may be enough to damage the vessel wall [7]. When comparing the symptoms that occurred in the presented study with risk factors of the Virchow's triad, at least two causative agents of DVT appeared. Furthermore, reference must be made to other significant factors not previously mentioned: the patient suffered from atrial fibrillation (AF) which also could have indirectly triggered thrombus formation. Figure 3 shows electrocardiography of the patient. The absence of P waves and irregular R-R intervals of the heart with atrial fibrillation are seen. Irregular R-R intervals were caused by irregular conduction of impulses to the ventricles.

Noel et al. examined AF as a risk factor for DVT in stroke patients. They observed the frequent coexistence of deep venous thrombosis or pulmonary embolism and stable atrial fibrillation. When they compared patients with and without AF, DVT was significantly more frequent in the former. Eventually, they determined that in stroke patients with AF, preventive anticoagulation therapy may be considered [10]. However, despite the fact of atrial fibrillation, the patient in



**Figure 3.** Electrocardiography of the patient  
Inside a sinus (regular) rhythm is shown. The absence of P waves (instead several small peaks are seen in this place), and irregular R-R intervals show atrial fibrillation

the presented case study did not take any antithrombotic medicines which are used both: with AF to prevent from stroke and with DVT of limb. Interestingly, the patient was a fit, active person.

There are some reports that treat the subject of athletic people on thrombus formation [11, 12]. The authors of one report tested the hypothesis that during heavy endurance sports, coagulation and platelets are activated depending on the type of endurance sport. They observed significant platelet activation only during marathon running, and to a lesser extent, during triathlon. They speculated that prolonged running may increase the risk of thrombotic incidents in running athletes [11], and in the literature there are also some cases of pulmonary embolism occurring after a prolonged effort of running in trained marathon athletes [12]. There is inconsistent data concerning the effects of regular exercise on thrombosis development [2]. In reports, thrombotic risk initially increases and sometimes decreases among different subject cohorts [1, 2]. Defining the precise effects of exercise in DVT prevention is difficult and depends on the individuals. Variables such as gender, age, body composition intensity, duration of the exercise, the methods used for haemostatic evaluation, etc., influence the ultimate evaluation [1, 2, 13]. There is a suggestion that low-intensity resistance exercise with blood flow restriction does not activate the coagulation system in healthy subjects [14]. In one report, the findings indicate that a stent thrombosis can be evoked by vigorous exercise, mainly in untrained patients. One patient suffered a stent thrombosis while performing vigorous exercise on a bicycle ergometer in a fitness centre [15]. When comparing DVT occurrence in a group of young women, according to Nagelkirk et al., overweight women may be at higher risk of an adverse thrombosis-related event, both at rest and during exercise, in comparison with leaner women [16]. Nevertheless, vigorous exercise could be a risk factor for DVT occurrence in the presented study. Warm water bathing is commonly used as recreational activity, and in most cases it is well tolerated. However, in this case study, staying in a jacuzzi on the same day when the calf strain occurred, probably also contributed to clot formation, as found in another report, 'warm water bathing leads to haemoconcentration and minimal activation of coagulation'. The authors do not maintain that there is a marked risk for thrombotic complications during warm water bathing in healthy males [17]; however, in the presented

study it could have been an indirect risk factor for DVT, as the patient repeated staying in a jacuzzi every day, and also just before the injury. The patient in this case study was diagnosed with a large thrombus formation in the femoral and popliteal regions, and what is important, after one month follow-up period, no recanalization was observed. During the time after injury, the patient did not practice any exercises. In the literature, there are some observations of physically active patients with deep venous thrombosis [5, 18]. A repeated-measures cohort study, conducted on 41 subjects indicated that exercise did not acutely exacerbate post-thrombotic symptoms and, in subjects with PTS, effected in improved flexibility in the affected leg [5]. Other authors have observed that early exercise in connection with bed rest led to more rapid resolution of limb pain in patients with acute DVT [4]. Scientists conclude that training may help prevent or improve the post-thrombotic syndrome, as early walking exercise was safe in patients with acute DVT and helped lower acute symptoms [4]. Regular sport practice also reduced the risk of DVT recurrence in patients [18].

Shrier et al. [19] presented a very interesting study about the effect of early physical activity on long-term outcome after DVT. They found that in the first month post-DVT, physical activity in patients was not associated with an increased risk of PTS in the first two years after DVT. Post-thrombotic syndrome was connected with decreased levels of physical activity two years after DVT. This could be the reason why the patient in the presented study suffered from PTS and did not have any improvement after 24 days follow-up period. These findings indicate that the patient could probably have improved his conditions by exercises. Mobilization and even active exercises should be included in a patient's everyday life. Isma et al. also state that early exercise combined with anticoagulation and compression stockings is safe for the majority of patients with DVT, and can be started almost immediately after a DVT [6].

This case study illustrates that considering DVT in the diagnosis of major limb injury is very important. Even young, trained people are susceptible to a variety of vascular injuries. Failure to recognize DVT can result in serious complications, including the sudden death of a patient. In the presented study, many risk factors for DVT development were found in the subject. The presence of Virchow's triad was established, but simultaneously other determinants were found: major trauma, vigorous exercise, immobility due to recent long journey by plane in a cramped position, and previous problems with atrial fibrillation. Unfortunately, the patient did not take any antithrombotic medicines to avoid stroke. The regular attendance in a jacuzzi could also have contributed indirectly to clot formation. The effects after thermoneutral and hyperthermic water immersion merit further study.

Improving the patient's health and beginning of the recanalization process might be achieved through mobilization and active exercises by the patient. It is important to remember that the risk of thrombosis is higher in rural areas because farm work increases risks of injuries to the lower extremities.

## REFERENCES

1. Adams M, Williams A, Fell J. Exercise in the Fight Against Thrombosis: Friend or Foe? *Semin Thromb Hemost.* 2009; 35: 261–268.
2. Adams M, Fell J, Williams A. Exercise causing thrombosis. *Phys Sportsmed.* 2009; 37: 124–30.
3. Ziegler S, Schillinger M, Maca TH, Minar E. Post-thrombotic Syndrome After Primary Event of Deep Venous Thrombosis 10 to 20 Years Ago. *Thromb Res.* 2001; 101: 23–33.
4. Kahn SR, Shrier I, Kearon C. Physical activity in patients with deep venous thrombosis: A systematic review. *Thromb Res.* 2008; 122: 763–773.
5. Kahn SR, Azoulay L, Hirsch A, Haber M, Strulovitch C, Shrier I. Acute Effects of Exercise in Patients With Previous Deep Venous Thrombosis: Impact of the Postthrombotic Syndrome. *Chest.* 2003; 123: 399–405.
6. Isma N, Johansson E, Björk A, Björgell O, Robertson F, Mattiasson I, Gottsäter A, Lindblad B. Does supervised exercise after deep venous thrombosis improve
7. recanalization of occluded vein segments? A randomized study. *J Thromb Thrombolysis.* 2007; 23: 25–30.
8. Taylor AJ. Deep vein thrombosis following calf strain: a case study. *Phys Ther Sport.* 2002; 3: 110–113.
9. Żylna choroba zakrzepowo-zatorowa w praktyce lekarza rodzinnego. *Forum Med Rodz.* 2007; 1: 115–123 (in Polish).
10. Echlin PS, Upshur REG, McKeag DB, Jayatilake HP. Traumatic deep vein thrombosis in a soccer player: A case study. *Thromb J.* 2004; 2: 8.
11. Noel P, Gregoire F, Capon A, Lehert P. Atrial fibrillation as a risk factor for deep venous thrombosis and pulmonary emboli in stroke patients. *Stroke.* 1991; 22: 760–762.
12. Hanke AA, Staib A, Goerlinger K, Perrey M, Dirkmann D, Kienbaum P. Whole blood coagulation and platelet activation in the athlete: a comparison of marathon, triathlon and long distance cycling. *Eur J Med Res.* 2010; 15: 59–65.
13. Fremont B, Pacouret G, de Labriolle A, Magdelaine B, Puglisi R, Charbonnier B. Exercise deep venous thrombosis: myth or reality? About three cases of pulmonary embolism in long-distance runners. *Arch Mal Coeur Vaiss.* 2007; 100: 519–523.
14. Lippi G, Maffulli N. Biological influence of physical exercise on hemostasis. *Semin Thromb Hemost.* 2009; 35: 257–259.
15. Madarame H, Kurano M, Takano H, Iida H, Sato Y, Ohshima H, Abe T, Ishii N, Morita T, Nakajima T. Effects of low-intensity resistance exercise with blood flow restriction on coagulation system in healthy subjects. *Clin Physiol Funct Imaging.* 2010; 30: 210–213.
16. Zwart B, Van Kerkvoorde TC, Van Werkum JW, Breet NJ, Ten Berg JM, Van 'T Hof AWJ. Vigorous exercise as a triggering mechanism for late stent thrombosis: A description of three cases. *Platelets.* 2010; 21: 72–76.
17. Nagelkirk PR, Scalzo R, Harber M, Kaminsky LA. The Influence of Acute Resistance Training and Body Composition on Coagulation and Fibrinolytic Activity in Low-Risk Women. *Int J Sports Med.* 2010; 31: 458–462.
18. Boldt LH, Fraszl W, Roker L, Schefold JC, Steinach M, Noack T, Gunga HC. Changes in the haemostatic system after thermoneutral and hyperthermic water immersion. *Eur J Appl Physiol.* 2008; 102: 547–554.
19. van Stralen KJ, Le Cessie S, Rosendaal FR, Doggen CJM. Regular sports activities decrease the risk of venous thrombosis. *J Throm Haem.* 2007; 5: 2186–2192.
20. Shrier I, Kahn SR, Steele RJ. Effect of Early Physical Activity on Long-Term Outcome After Venous Thrombosis. *Clin J Sport Med.* 2009; 19: 487–493.