

DOI 10.1515/pjvs-2015-0049

*Original article*

# Caudal mesenteric ganglion in the sheep – macroanatomical and immunohistochemical study

W. Sienkiewicz<sup>1</sup>, A. Chrószcz<sup>2</sup>, A. Dudek<sup>1</sup>, M. Janeczek<sup>2</sup>, J. Kaleczyc<sup>1</sup>

<sup>1</sup> Department of Animal Anatomy, Faculty of Veterinary Medicine,  
University of Warmia and Mazury in Olsztyn Oczapowskiego 13, 10-719 Olsztyn, Poland

<sup>2</sup> Department of Biostructure and Animal Physiology, Faculty of Veterinary Medicine,  
Wrocław University of Environmental and Life Sciences, Koźuchowska 1/3, 51-631 Wrocław, Poland

## Abstract

The caudal mesenteric ganglion (CaMG) is a prevertebral ganglion which provides innervation to a number of organs in the abdominal and pelvic cavity. The morphology of CaMG and the chemical coding of neurones in this ganglion have been described in humans and many animal species, but data on this topic in the sheep are entirely lacking. This prompted us to undertake a study to determine the localization and morphology of sheep CaMG as well as immunohistochemical properties of its neurones. The study was carried out on 8 adult sheep, weighing from 40 to 60 kg each. The sheep were deeply anaesthetised and transcatheterially perfused with 4% paraformaldehyde. CaMG-s were exposed and their location was determined. Macroanatomical observations have revealed that the ovine CaMG is located at the level of last two lumbar (L5 or L6) and the first sacral (S1) vertebrae. The ganglion represents an unpaired structure composed of several, sequentially arranged aggregates of neurones. Immunohistochemical investigations revealed that nearly all (99.5%) the neurones were D $\beta$ H-IR and were richly supplied by VACHT-IR nerve terminals forming „basket-like” structures around the perikarya. VACHT-IR neurones were not determined. Many neurones (55%) contained immunoreactivity to NPY, some of them (10%) stained for Met-ENK and solitary nerve cells were GAL-positive. CGRP-IR nerve fibres were numerous and a large number of them simultaneously expressed immunoreactivity to SP. Single, weakly stained neurones were SP-IR and only very few nerve cells weakly stained for VIP.

**Key words:** sheep, caudal mesenteric ganglion, morphometry, immunohistochemistry

## Introduction

The caudal mesenteric ganglion (CaMG) belongs to prevertebral ganglia, considering autonomic ganglia in the modern anatomical nomenclature (Nickel et al. 2004, NAV 2005, Koenig and Liebich 2007). It consists of neurons located within the caudal mesenteric plexus, which is a posterior prolongation of the abdominal aortic plexus (Nickel et al. 2004, Koenig and Liebich 2007). In humans, the abdominal part of the sympathetic nervous system forms *inter alia* the intermesenteric plexus (abdominal aortic plexus) and the secondary plexus, the inferior mesenteric plexus, found in the neighbourhood of the caudal mesenteric artery (Bochenek and Reicher 2002). The inferior mesenteric plexus contains some clusters of neurons, irregular in shape and location, without forming a distinct ganglion, which is regularly observed in domestic mammals and called the CaMG (Bochenek and Reicher 2002, Nickel et al. 2004, Koenig and Liebich 2007).

The physiology and pathophysiology of the CaMG and corresponding plexus is widely discussed in the literature (Melman and Kapskya 1960, Nozdrachev 1968, Kostina 1971, Komissarov and Krivobok 1975, Archakova 1979, Kaleczyc et al. 1995, Sann et al. 1995, Berthoud and Powley 1996, Elfvin et al. 1997, Ribeiro et al. 2000a, Ribeiro et al. 2000b, Pasichnichenko and Skok 2002, Gagliardo et al. 2003, Koval et al. 2004, Gagliardo et al. 2005, Pidsudko et al. 2011). Unfortunately, the lack of detailed descriptions of these structures in domestic mammals, besides some general comments provided by anatomical textbooks (Dyce et al. 2002, Nickel et al. 2004, Koenig and Liebich 2007), have partly prompted us to undertake anatomical studies regarding the ovine CaMG. In laboratory animals, the anatomy of the cranial cervical ganglion, coeliac ganglion and pelvic ganglia have been widely described (Gabella et al. 1988, Gabella et al. 1992, Gabella and Uvelius 1993, Gabella 1995, Miolan and Niel 1996, Gabella and Davis 1998, Gabella and Uvelius 1998). Anatomical investigations performed in domestic mammals have dealt with the cranial cervical ganglion and the cervicothoracic ganglion in the sheep (Pospieszny 1979, Gabella et al. 1988), the coeliac ganglion in the goat (Bhamburkar et al. 1993), buffalo (Ribeiro et al. 2000b), cat (Feher and Burnstock 1991, Ribeiro et al. 2000a) and birds (Kuder et al. 2003) and the aorticorenal ganglion in the sheep (Pospieszny 1977), cat (Pospieszny and Kleckowska-Nawrot 2002) and dog (Pospieszny et al. 2003). Immunohistochemical studies on CaMG were mainly performed in laboratory animals such as the rat (Herbrecht et al. 1995, Sann et al. 1995), guinea pig (McLachlan and Llewellyn-Smith 1986, Sann et al.

1995, Parr and Sharkey 1996) and cat (Cupo et al. 1988, Bagnol et al. 1993). Considering large animals, immunohistochemical properties of CaMG structures were investigated mainly in the pig, but except few papers (Lakomy et al. 1994, Lakomy et al. 1996, Kaleczyc et al. 2003) dealing with the general anatomy of this ganglion, most of the studies investigated specific subpopulations of CaMG neurones supplying different organs (Kaleczyc et al. 1994, Kaleczyc et al. 1995, Kaleczyc 1998, Pidsudko et al. 2001, Klimczuk and Kaleczyc 2010, Sienkiewicz 2010a,b). However, the literature in the field contains no information on immunohistochemical features of the ovine CaMG. As clearly seen from the above literature overview there is a lack of comprehensive studies dealing with immunohistochemical properties of neurones in CaMG in large domestic animals. Complementing the missing data will allow a more precise determination of the chemical coding of neuronal subpopulations, defined for example, during research based on neuronal tracing, and thus to determine precisely their target organ specificity. Therefore, the anatomical and immunohistochemical investigations of CaMG in the sheep can be a valuable contribution to the modern knowledge on the anatomy and physiology of autonomic nervous system.

## Materials and Methods

The study was carried out on 8 adult sheep of Polish merino breed, weighing from 40 to 60 kg each. The animals were housed and treated in accordance with the rules approved by the local Ethics Commission (confirming the principles of Laboratory Animal Care, NIH publication No. 86-23, revised in 1985). Thirty minutes before the main anaesthetic, tiopental (Tiopental; 25 mg/kg of b.w.) was given intravenously, the sheep were pre-treated with xylazine (Vetaxyl; 0.5 mg/kg of b.w. i.m.) and 20 min later with ketamine (Vetaketam; 10mg/kg/b.w./i.v.). Then, they were transcardially perfused with 1 l of preperfusion solution containing 0.9% sodium chloride (Chemia, Gliwice, Poland), 2.5% polyvinylpyrrolidone (Sigma, Deisenhofen, Germany), 0.5% procaine hydrochloride (Polfa, Warsaw, Poland) and 20 000 IU of heparin (Heparinum; Polfa; added *ex tempore*), followed by 8-10 l of 4% ice-cold buffered paraformaldehyde (pH 7.4) and the abdominal cavity was cut open. Caudal mesenteric ganglia were exposed and their topographical location was determined considering the skeletotopy, syntopy and holotopy. All macroanatomical measurements were carried out three times with an electronic caliper and the mean values were estimated. The findings were documented with photos

Table 1. Antisera used in the study.

Antigen	Host	Type	Dilution	Cat. No.	Supplier
Primary antisera					
D $\beta$ H	mouse	monoclonal	1:500	MAB308	Milipore
NPY	rabbit	polyclonal	1:400	NA1233	Biomol
GAL	rabbit	polyclonal	1:2000	RIN 7153	Peninsula Lab.
SP	rat	monoclonal	1:150	8450-0505	ABD Serotec, UK
CGRP	rabbit	polyclonal	1:2000	11535	Cappel
VACHT	rabbit	polyclonal	1:5000	V5387	Sigma
VIP	mouse	monoclonal	1:500	MaVIP	East Acres Biologicals
Met-ENK	rabbit	polyclonal	1:500	RPN 1562	Amersham
Secondary antisera					
Host	Fluorochrom	Dilution	Code	Supplier	
Goat-anti-rabbit IgG (H+L)	Alexa Flour 488	1:500	A11008	Invitrogen	
Goat-anti-mouse IgG (H+L)	Alexa Flour 488	1:500	A11001	Invitrogen	
Goat-anti-rabbit IgG (H+L)	Alexa Flour 568	1:500	A11011	Invitrogen	
Goat-anti-mouse IgG (H+L)	Alexa Flour 568	1:500	A11004	Invitrogen	
Goat-anti-rat IgG (H+L)	Alexa Flour 488	1:500	A11006	Invitrogen	

and schemes. Afterwards, the ganglia were collected. The tissues collected were postfixed by immersion in the same fixative for 2 hours, rinsed with phosphate buffer (pH 7.4) and transferred to and stored in 30% buffered sucrose solution (pH 7.4) until further processing. The ganglia were cut into 12  $\mu$ m-thick cryostat sections, which were processed for double-immunofluorescence method on slide mounted sections. The sections were washed 3x10 min. in PB, incubated 45 min. in 10% normal horse serum (NHS, Cappel, Warsaw, Poland) in PBS containing 0.25% Triton X-100 (Sigma, USA) and then incubated overnight in room temperature (RT) with antibodies (Table 1) diluted in PB containing 1% of normal swine serum (NSS) and 0.25% Triton X-100. After incubation with primary antiserum, the sections were washed 3x10 min. in PB and further incubated with secondary antisera 1h in RT. After incubation, the sections were washed 3x10 min. in PB, coverslipped with buffered glycerol and examined under a confocal microscope (Zeiss LSM 700). Control of specificity of staining was performed by preabsorption of a diluted antiserum with 20  $\mu$ g/ml of an appropriate antigen (except D $\beta$ H and VACHT), which abolished the specific immunoreaction completely. In addition, experiments were carried out in which the primary antiserum was replaced by non-immune serum, or by PBS, in order to verify the specificity of particular immunoreactions.

Counting of neurons: to determinate percentages (presented as mean values from all the animals studied, rounded up to the value without the decimal)

of particular neuronal populations, at least 200 of neuronal profiles from every animal investigated for each combination of antisera were counted. The sections were collected from different, representative regions of the ganglia (from their upper, middle and lower one-third). To avoid double-counting of the same neurons, appropriate distance (minimum five sections = 60  $\mu$ m) between the sections was maintained. The number of immunolabelled profiles was calculated as a percentage of immunoreactive neurons in regard to all perikarya counted.

## Results

Macroanatomical investigations proved unite and impaired structure of CaMG in sheep (Fig. 1). The ganglion consisted of 3-6 chain-like clusters of neurons with multiple connecting branches located within the distal mesocolon. Considering the morphology of this structure we suggested to call it the caudal mesenteric plexus/ganglion complex (CaMPG). The length of the CaMPG complex was ca. 56.1 mm (Table 2). Initial segment of the caudal mesenteric artery with its branches were clearly visible between the layers of the mesocolon. The left colic artery was arch shaped and ran parallel to the CaMPG. The skeletal localization of the structures investigated was between L5-S1 (Table 3), nearby the cranial pelvic aperture organs, dorsally to the colon descendens and caudally to the caudal mesenteric artery origin. The

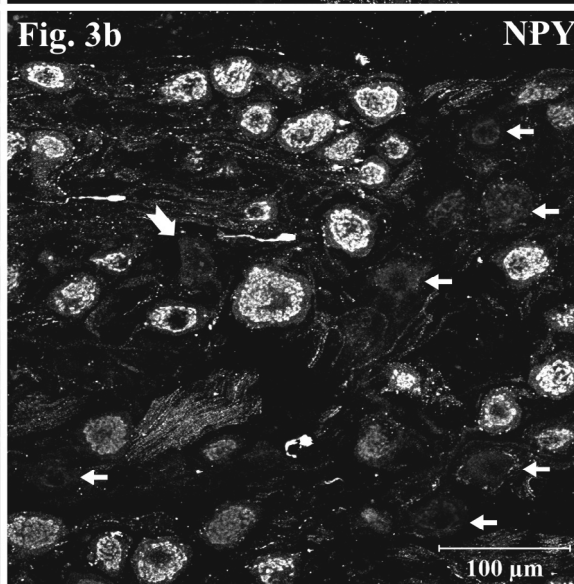
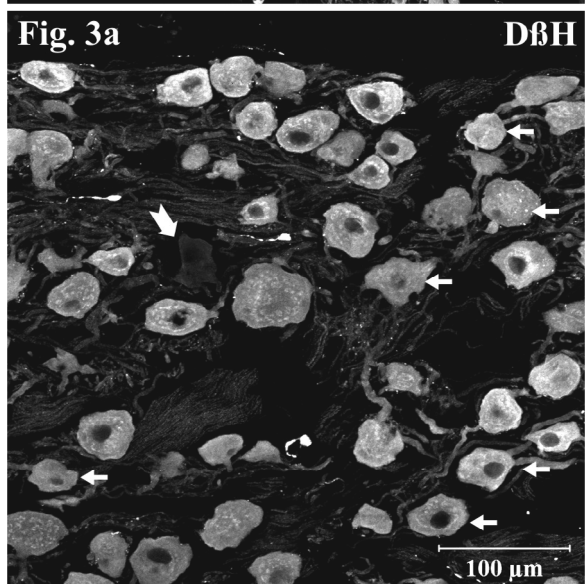
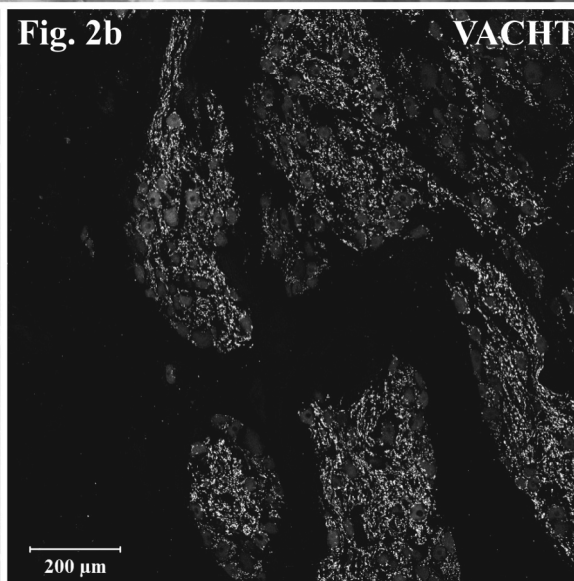
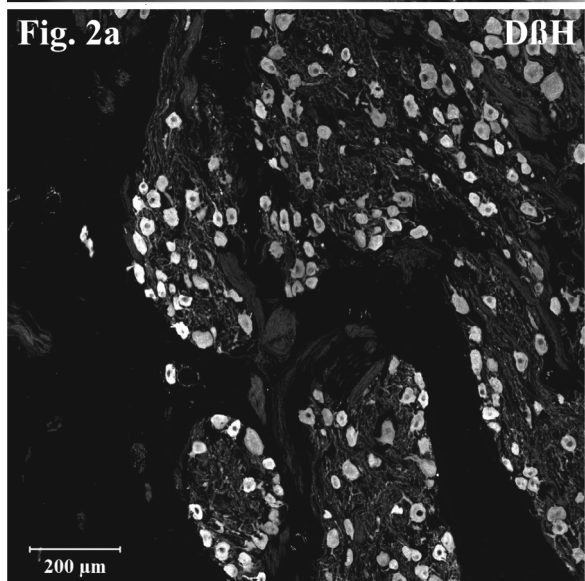
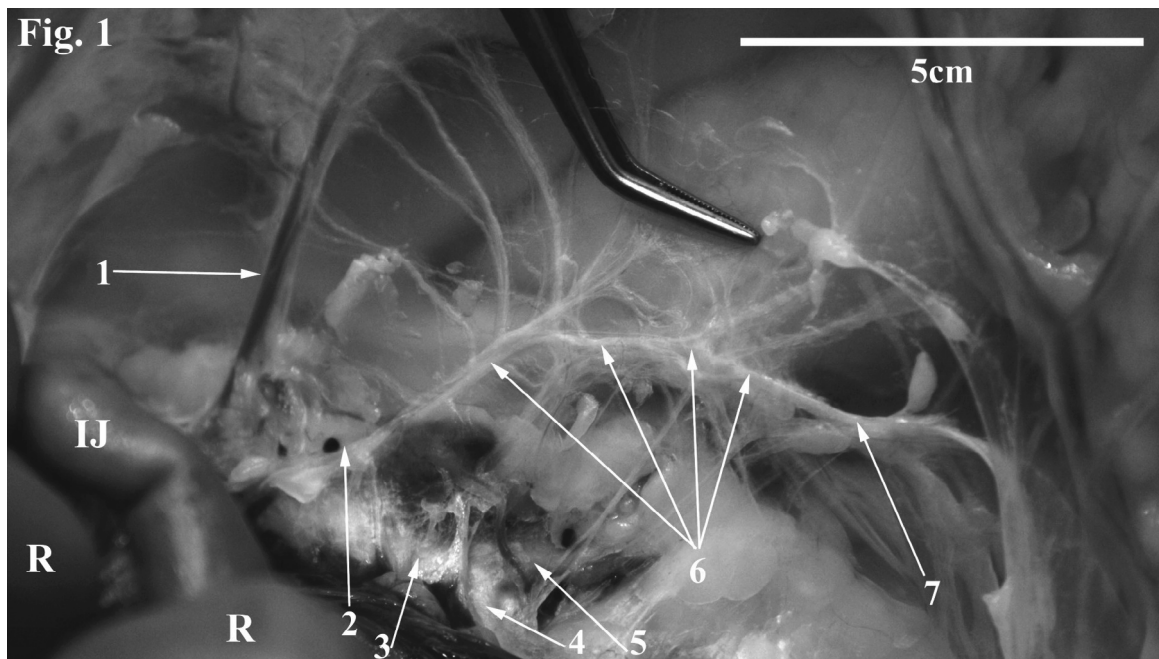




Table 2. Total length of the ovine caudal mesenteric plexus/ganglion complex.

No.	1	2	3	4	5	6	7	8	mean
[mm]	55.2	64.2	42.2	54.3	74.7	53.8	51.3	52.8	56.1

Table 3. Skeletotopy of the ovine caudal mesenteric plexus/ganglion complex.

No.	1	2	3	4	5	6	7	8	range
Skeletotopy	L6-S1	L5-S1	L6-S1	L6-S1	L5-S1	L6-S1	L6-S1	L6-S1	L5-S1

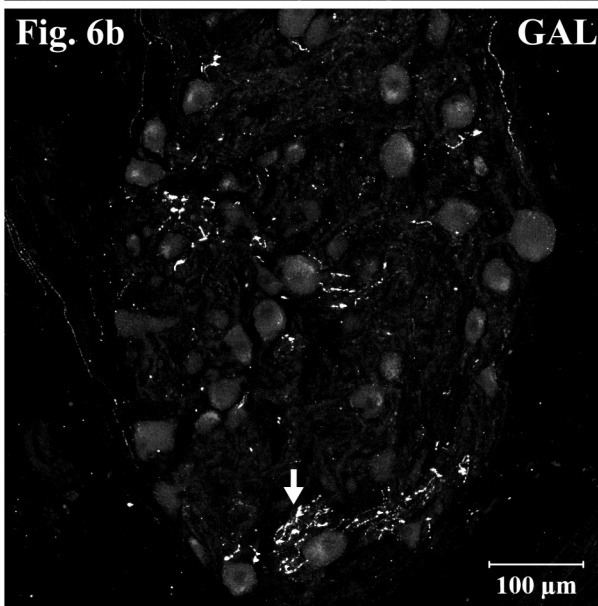
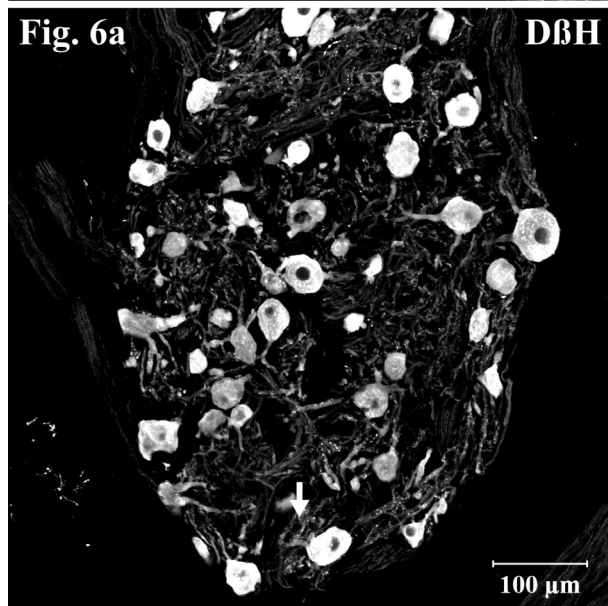
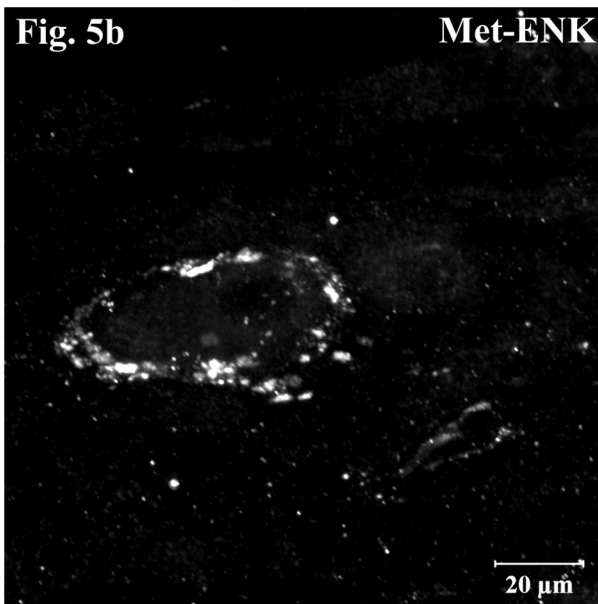
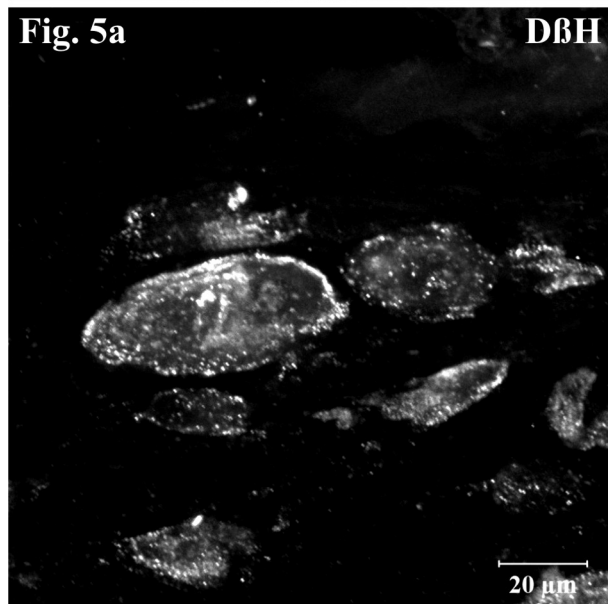
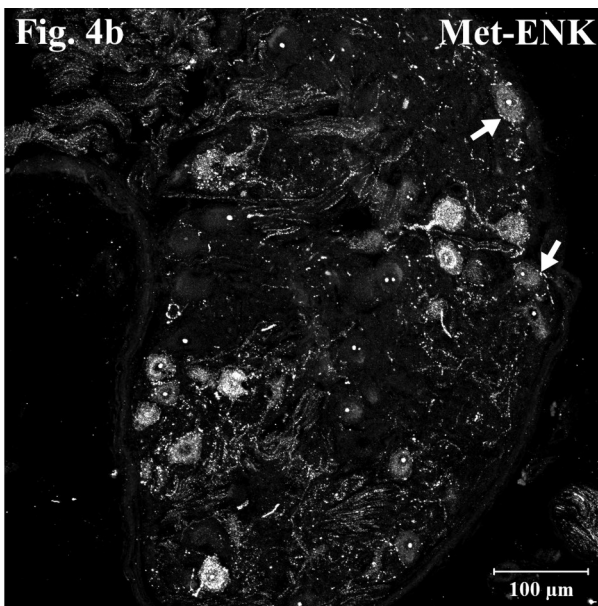
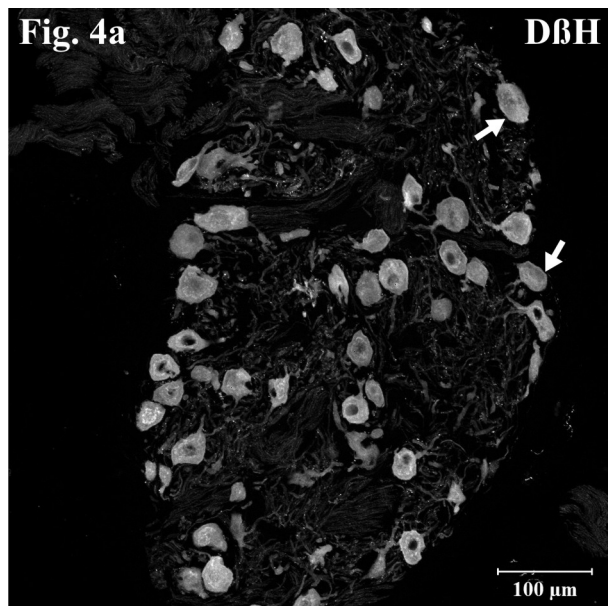
CaMPG receive nervous branches from the intermesenteric plexus, whereas the connection between the CaMPG and pelvic plexus was accomplished by the hypogastric nerve. The neurons of the CaMPG gave off branches to the caudal mesenteric artery, which accompanied its wall to reach the descending colon and cranial part of the rectum.

Microscopical analysis revealed that ganglia forming the sheep CaMPG consisted of several groups of neurons including small ganglia comprising tens of perikarya (up to 10 groups) and large ganglia (up to 6 groups) comprising up to few thousands of neuronal cell bodies. Double immunohistochemical stainings revealed that nearly all neurons (99.5%) of the CaMPG expressed immunoreactivity to D $\beta$ H (Fig. 2a), but were immunonegative for VACHT (Fig. 2b). However, they were richly supplied by VACHT-immunoreactive nerve terminals forming „basket-like” structures around the perikarya (Fig. 2b). Only single neurons were D $\beta$ H-negative (Fig. 3a). Approximately 55% of the neurons contained immunoreactivity to NPY (Fig. 3b). Neurons immunonegative for D $\beta$ H also did not stain for NPY (Figs. 3a,b). Among the D $\beta$ H-immunoreactive neurons (Fig. 4a) about 10% contained immunoreactivity to Met-ENK (Fig. 4b). Numerous intraganglionic Met-ENK-immunoreactive nerve fibres were observed, and sometimes they were

found to run in a close vicinity to the neuronal somata (Fig. 4a,b). Some Met-ENK-immunoreactive nerve terminals were found to surround D $\beta$ H-immunoreactive perikarya forming „basket-like” structures (Fig. 5a,b). Double staining against D $\beta$ H and GAL revealed the presence of a moderate number of intraganglionic GAL-immunoreactive nerve fibres (Fig. 6a,b). Only single nerve terminals contained simultaneously D $\beta$ H-immunoreactivity. GAL-positive axons formed also networks, usually located at the periphery of the ganglia (Fig. 6b). Solitary neurones expressed GAL-immunoreactivity and they were always D $\beta$ H-positive (Fig. 7a,b). Numerous intraganglionic nerve fibres stained for SP (Fig. 8a). Most of them were simultaneously CGRP-positive (Fig. 8b). Single, weakly stained neurones exhibited SP-immunoreactivity (Fig. 8a), but they were CGRP-negative. CGRP-positive nerve fibres were even more numerous than those containing immunoreactivity to SP, and a great proportion of them simultaneously stained for SP (Fig. 8a,b). Double labelling against VIP and VACHT revealed only very few weakly stained VIP-positive neurones (Fig. 9a). They were VACHT-negative, but were surrounded by numerous VACHT-positive nerve terminals forming „basket-like” structures (Fig. 9a,b).

←

Fig. 1. Morphology of the caudal mesenteric ganglion in the sheep. The ganglion was located between the laminas of the peritoneum forming the mesentery of the descending colon, and represented an unpaired structure resembling longitudinally oriented chain of ganglia. Legend: 1 – arteria mesenterica caudalis, 2 – rami cum plexo intermesenterico, 3 – arteria iliaca communis, 4 – arteria iliaca interna, 5 – arteria iliaca externa, 6 – ganglia mesenterica caudalia et plexus mesentericus caudalis, 7 – nervus hypogastricus, R-rumen, IJ-intestinum jejunale; Fig. 2. Section through the ovine caudal mesenteric ganglion stained with antibodies against D $\beta$ H and VACHT. Nearly all of the neurons exhibited immunoreactivity to D $\beta$ H (Fig. 2a). Very numerous VACHT-immunoreactive nerve fibers formed „basket-like structures” surrounding D $\beta$ H-IR perikarya (Fig. 2b); Fig. 3. Caudal mesenteric ganglion stained with antibodies against D $\beta$ H (Fig. 3a) and NPY (Fig. 3b). Half of the neurons contained simultaneously D $\beta$ H- and NPY-immunoreactivity. D $\beta$ H-negative neurons did not stain for NPY (large arrow). The remaining neurons were always D $\beta$ H-immunopositive (examples indicated by arrows).



## Discussion

The morphology of the CaMG has been a rarely considered issue in the field of veterinary anatomy. Textbooks of veterinary anatomy contain only general descriptions of the abdominal part of the sympathetic nervous system, especially its caudal portion (Klimov and Akajewski 1953, Nickel et al. 2004, Koenig and Liebich 2007). Except some contributions (Gagliardo et al. 2003, Berghes 2007), the literature lacks of wider information on the caudal mesenteric ganglion gross anatomy.

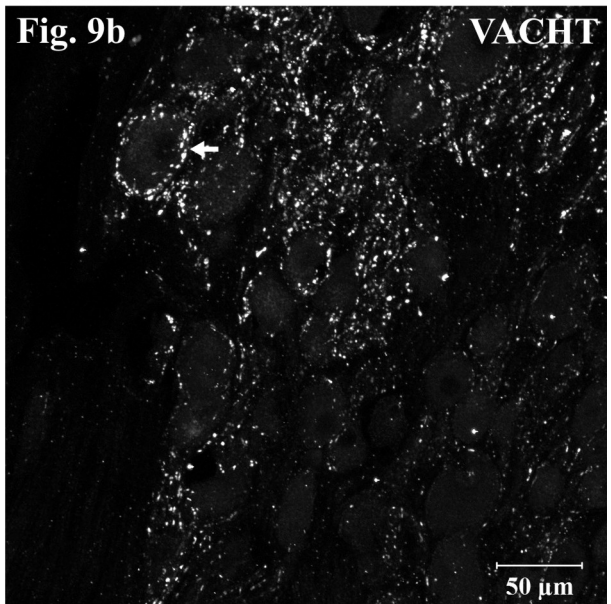
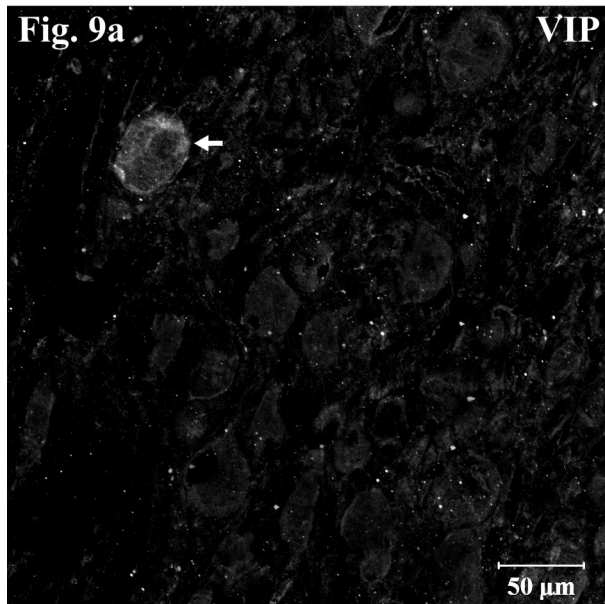
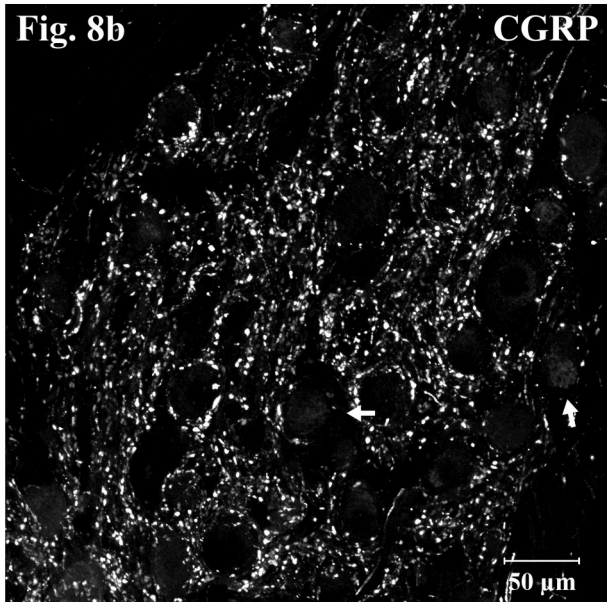
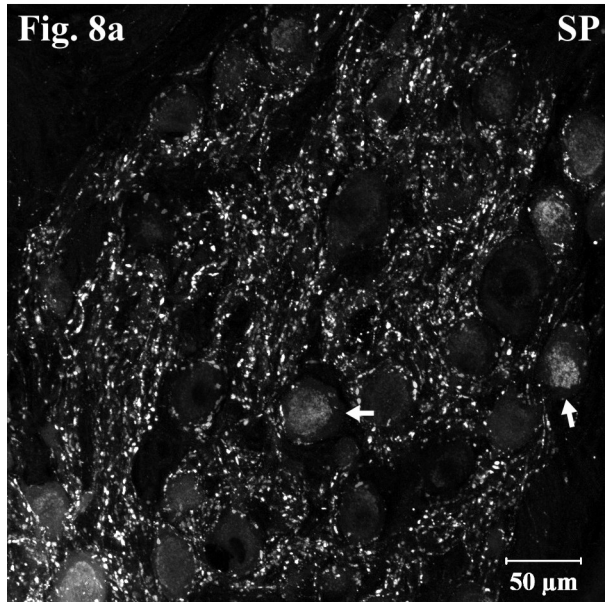
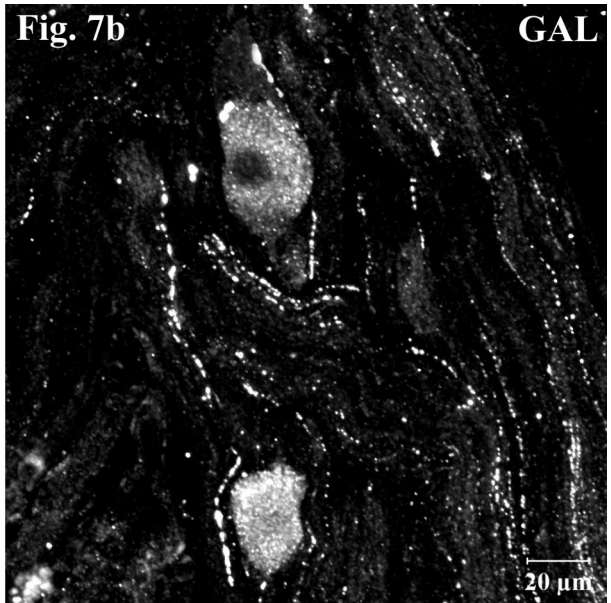
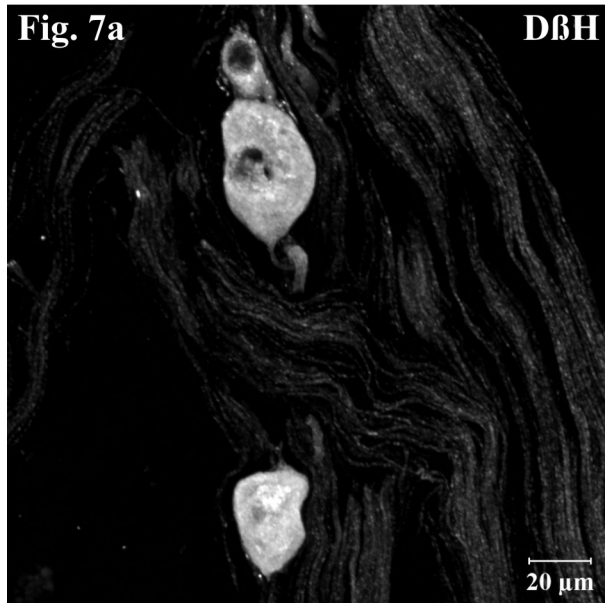
Even the organisation of the abdominal autonomic plexus ganglia has not been clearly recognised. The CaMG is usually described as a paired structure only in cattle (Nickel et al. 2004). Bilateral ganglia show tendency to fuse, forming the impaired structure in the pig and horse or 1-4 groups of neurons in the cat (Nickel et al. 2004). The data regarding the pig are in contrast to our previous studies involving tracer investigations of genital organs and dealing with immunohistochemical properties of neurones innervating these organs (Kaleczyc et al. 1994, Kaleczyc et al. 1995, Kaleczyc 1998, Klimczuk and Kaleczyc 2010, Sienkiewicz 2010b). In these studies we always found the CaMG as the paired structure. Gagliardo et al. (2003) have proved the canine CaMG to be the impaired structure. This well documented study performed on 40 individuals are in disagreement with a report (Zacharko et al. 2004) describing the localisation of neurones supplying the prostate gland and claiming that the retrogradely traced neurones were found within bilateral CaMG-s. In humans, the CaMG is usually defined as a part of the secondary plexus emerging from the intermesenteric plexus (Bochenek and Reicher 2002). Our investigations have revealed disseminated and impaired structure of the ovine caudal mesenteric plexus/ganglion complex, not similar to that observed in other large ruminants (Nickel et al. 2004). In contrast to this textbook knowledge, Berghes (2007) has reported in calves CaMG possessing impaired, single structure or represents impaired multiple ganglia with chain-like morphology located between the layers of the mesentery. The latter morphological variation seems to be similar to that observed in the sheep.

In the sheep the nervous connections, the number and direction of the branches of CaMG, are similar to observed in calves (Berghes 2007). The nervous connections of the caudal mesenteric ganglion in the cat involve: the hypogastric nerve, intermesenteric nerves, colic branches and lumbar spinal nerves (L3 and L4) (Jule et al. 1983). Despite the sacral spinal nerves, the arrangement of the ovine CaMG resembles that observed in the cat.

The present immunohistochemical investigations have revealed that almost all neurones within the ovine CaMG express immunoreactivity to catecholamine synthesising enzyme, DBH. Only very few neurones (less than 0.5%) were DBH negative. This observation does not fully correspond with previous reports claiming the presence of much more numerous non-catecholaminergic neurones within the porcine (Kaleczyc et al. 1995, Majewski et al. 2002, Kaleczyc et al. 2003, Klimczuk and Kaleczyc 2010) and guinea-pig (Parr and Sharkey 1996, Elfvin et al. 1997) ganglia. Also the middle cervical ganglion in the sheep has been found to contain a lower number of catecholaminergic neurones (slightly over 95%) (Arciszewski and Wasowicz 2006). Surprisingly in the ganglia studied no VACHT-IR neurones were determined, whereas cholinergic nerve fibres formed very dense intraganglionic network. In the porcine CaMG, cholinergic neurones are more abundant and form a population comprising a few percent neurons (Kaleczyc et al. 2003). A small population of choline acetyltransferase immunoreactive neurons has been identified also in the CaMG of the guinea pig (4.6% of all the neurons), ferret (6.4%) and rat (0.4%) (Sann et al. 1995). In the porcine CaMG, nearly all adrenergic and cholinergic neurons are supplied with VACHT-positive (putative preganglionic) nerve fibres and many of them also stain for VIP (Kaleczyc et al. 2003). Similarly, in the ovine CaMG a very dense network of the cholinergic nerve terminals was found, but among them only single fibres were VIP-positive. A large number of ovine CaMG neurons contained immunoreactivity to NPY (55%), whereas in the guinea-pig less than 20% of nerve cell bodies in CaMG stained for this peptide (McLachlan and Llewellyn-Smith 1986). In the middle cervical ganglion of the sheep a large population of noradrenergic

←

Fig. 4. DβH- (fig 4a) and Met-ENK-positive (Fig. 4b) nerve structures in the caudal mesenteric ganglion. About 10% of the neurons contained Met-ENK-immunoreactivity and they were simultaneously DβH-positive. Met-ENK-IR intraganglionic nerve fibers were moderate in number: some of them formed „basket-like” structures supplying neurons (arrows); Fig. 5. Large magnification of DβH- and Met-ENK-positive neurones (Fig. 5a) in the caudal mesenteric ganglion supplied by numerous Met-ENK-immunoreactive nerve endings (Fig. 5b); Fig. 6. DβH- (Fig. 6a) or GAL-positive (Fig. 6b) nerve structures in the caudal mesenteric ganglion. GAL-immunoreactivity was observed in nerve fibers running through the ganglion and in fibers forming a network around the DβH-positive neurons, particularly in peripheral regions of the ganglion (arrow).



neurons exhibited immunoreactivity to NPY (over 60%), but single (2%) NPY-positive perikarya lacking noradrenergic markers were also observed (Arciszewski and Wasowicz 2006). In our study it was found that all the NPY-positive neurons were catecholaminergic.

Enkephalinergic neurons and nerve fibers were found in the CaMG of many mammalian species including the guinea-pig (Dalsgaard et al. 1983b, Chiba and Masuko 1989, Herbrecht et al. 1995), cat (Cupo et al. 1988, Bagnol et al. 1993), rat (Herbrecht et al. 1995) and pig (Lakomy et al. 1994, Kaleczyc et al. 1995, Kaleczyc et al. 2003). Unfortunately the above mentioned papers contain no information on the frequency of neurons exhibiting immunoreactivity to enkephalins, so it is difficult to compare previous results with the present findings. The ovine CaMG contained moderate in number GAL-IR nerve fibers which is consistent with previous observations obtained in the guinea pig (Elfvin et al. 1994). In the above mentioned paper the authors (Elfvin et al. 1994) described GAL-IR SIF-cells. Even application of colchicine or vinblastine onto the IMG did not result in the appearance of immunoreactivity to GAL in the principal ganglion cells (Elfvin et al. 1994). Contrary to that we found single, principal, GAL-positive neurons in the ovine CaMG.

The present study have revealed that immunoreactivity to SP and CGRP has been found mainly in nerve fibres richly supplying nerve cell bodies of the ganglion studied. The morphology and immunohistochemical properties of these nerve terminals were very similar to those observed in the pig (Kaleczyc et al. 2003). SP and/or CGRP-IR nerve fibres are likely to be collaterals of peripheral processes of primary sensory neurones and such possibility was already mentioned by other authors (Dalsgaard et al. 1983a, Matthews and Cuello 1984, Kaleczyc et al. 2003). Despite the fact that the ovine CaMG contains only single neurones positive for SP, it should be noted that in the ganglion of other species such as the pig (Lakomy et al. 1996, Kaleczyc et al. 2003) and guinea-pig (Dalsgaard et al. 1983a,c, Parr and Sharkey 1996) there are no nerve cells containing immunoreactivity to this peptide.

A small population of VIP-positive neurones (1-2%) were found in the CaMG of the pig (Lakomy

et al. 1996) and guinea-pig (Parr and Sharkey 1996). In the cat CaMG, VIP-positive neurons are extremely rare (Heym et al. 1984). This observation is consistent with that regarding immunohistochemical characteristics of the CaMG neurones in the sheep.

This article provides thorough information on the immunohistochemical characteristics of CaMG in the sheep. Comparison of our findings with the results obtained by other researchers has revealed the existence of significant differences between the animal species studied. The most important difference is the lack of cholinergic neurons in the CaMG of the sheep, whereas such nerve cells are present in lesser or greater numbers in the ganglion of other animal species. Providing accurate data on immunohistochemical characteristics of neurons in ovine CaMG would help to determine neurochemical properties of ganglionic neuronal subpopulations supplying various organs and thus to establish the chemical coding of their supplying nerve fibres.

### Acknowledgements

The authors would like to thank Ms M. Marczak for her excellent technical assistance

Supported by grant No. N N 308 593240

### References

- Archakova LI (1979) Submicroscopic localization acetylcholinesterase in synapses of the caudal mesenteric ganglion in cats. *Neurofiziologija* 11: 74-79.
- Arciszewski MB, Wasowicz K (2006) Neurochemical properties of the middle cervical ganglion in the sheep. *Ann Anat* 188: 75-83.
- Bagnol D, Jule Y, Kirchner G, Cupo A, Roman C (1993) Enkephalin-containing neurons in the inferior mesenteric ganglion projecting to the distal colon of cat: evidence from combined retrograde tracing by fluorescent microspheres and immunohistochemistry. *J Auton Nerv Syst* 42: 143-151.
- Berghes DAC (2007) Caudal mesenteric plexus calves – anatomical studies. *Bulletin USAMV-CN* 64: 125-128.
- Berthoud HR, Powley TL (1996) Interaction between parasympathetic and sympathetic nerves in prevertebral ganglia: Morphological evidence for vagal efferent innervation of ganglion cells in the rat. *Microscopy Research and Technique* 35: 80-86.



Fig. 7. Large magnification of DBH- and GAL-positive neurones (Fig. 7a) in caudal mesenteric ganglion, supplied by numerous GAL-immunoreactive nerve endings (Fig. 7b); Fig. 8. Dense SP- (Fig. 8a) and CGRP- (Fig. 8b) immunoreactive nerve fibers (presumably collaterals of peripheral processes of sensory neurones located in the spinal ganglia) in the caudal mesenteric ganglion. Note the presence of single SP-positive but CGRP-negative nerve cells (arrows); Fig. 9. VIP- and VACHT-positive structures in the caudal mesenteric ganglion. Immunoreactivity to VIP was present in very few neurones (Fig. 9a), but they were richly supplied by VACHT-positive nerve endings (Fig. 9b).

- Bhamburkar VR, Prakash P, Prakash P (1993) Quantitative histomorphological studies on the sympathetic ganglia of goat (*Capra hircus*). *Indian Vet J* 70: 337-340.
- Bochenek A, Reicher M (2002) *Anatomia człowieka*. Tom V. Wyd. Lek. PZWL Warszawa.
- Chiba T, Masuko S (1989) Coexistence of multiple peptides in small intensely fluorescent (SIF) cells of inferior mesenteric ganglion of the guinea pig. *Cell Tissue Res* 255: 523-527.
- Cupo A, Niel JP, Miolan JP, Jule Y, Jarry T (1988) Enkephalins in the inferior mesenteric ganglion of the cat and in the area of the lower digestive tract innervated by this ganglion: quantification by radio-immunoassay and characterization by high pressure liquid chromatography. *Neuropeptides* 12: 257-263.
- Dalsgaard CJ, Hokfelt T, Schultzberg M, Lundberg JM, Terenius L, Dockray GJ, Goldstein M (1983a) Origin of peptide-containing fibers in the inferior mesenteric ganglion of the guinea-pig: immunohistochemical studies with antisera to substance P, enkephalin, vasoactive intestinal polypeptide, cholecystokinin and bombesin. *Neuroscience* 9: 191-211.
- Dalsgaard CJ, Vincent SR, Hokfelt VT, Christensson I, Terenius L (1983b) Separate origins for the dynorphin and enkephalin immunoreactive fibers in the inferior mesenteric ganglion of the guinea pig. *J Comp Neurol* 221: 482-489.
- Dalsgaard CJ, Vincent SR, Schultzberg M, Hokfelt T, Elfvin LG, Terenius L, Dockray GJ (1983c) Capsaicin-induced depletion of substance P-like immunoreactivity in guinea pig sympathetic ganglia. *J Auton Nerv Syst* 9: 595-606.
- Dyce KM, Sack WO, Wensing CJG (2002) *Textbook of veterinary anatomy*. Saunders, Philadelphia
- Elfvin LG, Hokfelt T, Bartfai T, Bedecs K (1994) Immunohistochemical demonstration of galanin-, and galanin message-associated peptide-like immunoreactivities in sympathetic ganglia and adrenal gland of the guinea pig. *Microsc Res Tech* 29: 131-142.
- Elfvin LG, Holmberg K, Emson P, Schemann M, Hokfelt T (1997) Nitric oxide synthase, choline acetyltransferase, catecholamine enzymes and neuropeptides and their colocalization in the anterior pelvic ganglion, the inferior mesenteric ganglion and the hypogastric nerve of the male guinea pig. *J Chem Neuroanat* 14: 33-49.
- Feher E, Burnstock G (1991) Ultrastructure and distribution of somatostatin-like immunoreactive neurons and nerve fibres in the coeliac ganglion of cats. *Cell Tissue Res* 263: 567-572.
- Gabella G (1995) *Autonomic Nervous System (The Rat Nervous System)*. Academic Press 2nd edn, London
- Gabella G, Berggren T, Uvelius B (1992) Hypertrophy and reversal of hypertrophy in rat pelvic ganglion neurons. *J Neurocytol* 21: 649-662.
- Gabella G, Davis C (1998) Distribution of afferent axons in the bladder of rats. *J Neurocytol* 27: 141-155.
- Gabella G, Trigg P, McPhail H (1988) Quantitative cytology of ganglion neurons and satellite glial cells in the superior cervical ganglion of the sheep. Relationship with ganglion neuron size. *J Neurocytol* 17: 753-769.
- Gabella G, Uvelius B (1993) Effect of decentralization or contralateral ganglionectomy on obstruction-induced hypertrophy of rat urinary bladder muscle and pelvic ganglion. *J Neurocytol* 22: 827-834.
- Gabella G, Uvelius B (1998) Homotransplant of pelvic ganglion into bladder wall in adult rats. *Neuroscience* 83: 645-653.
- Gagliardo KM, De Carvalho Balieiro JC, De Souza RR, Ribeiro AA (2005) Postnatal-related changes in the size and total number of neurons in the caudal mesenteric ganglion of dogs: total number of neurons can be predicted from body weight and ganglion volume. *Anat Rec A Discov Mol Cell Evol Biol* 286: 917-929.
- Gagliardo KM, Guidi WL, Da Silva RA, Ribeiro AA (2003) Macro and microstructural organization of the dog's caudal mesenteric ganglion complex (*Canis familiaris*-Linnaeus, 1758). *Anat Histol Embryol* 32: 236-243.
- Herbrecht F, Bagnol D, Cucumel K, Jule Y, Cupo A (1995) Distribution of enkephalin immunoreactivity in sympathetic prevertebral ganglia and digestive tract of guinea-pigs and rats. *Regul Pept* 57: 85-95.
- Heym C, Reinecke M, Weihe E, Forssmann WG (1984) Dopamine-beta-hydroxylase-, neurotensin-, substance P-, vasoactive intestinal polypeptide- and enkephalin-immunohistochemistry of paravertebral and prevertebral ganglia in the cat. *Cell Tissue Res* 235: 411-418.
- Jule Y, Krier J, Szurszewski JH (1983) Patterns of innervation of neurones in the inferior mesenteric ganglion of the cat. *J Physiol* 344: 293-304.
- Kalczyk J (1998) Origin and neurochemical characteristics of nerve fibres supplying the mammalian vas deferens. *Microsc Res Tech* 42: 409-422.
- Kalczyk J, Sienkiewicz W, Klimczuk M, Czaja K, Lakomy M (2003) Differences in the chemical coding of nerve fibres supplying major populations of neurons between the caudal mesenteric ganglion and anterior pelvic ganglion in the male pig. *Folia Histochem Cytobiol* 41: 201-211.
- Kalczyk J, Timmermans JP, Majewski M, Lakomy M, Mayer B, Scheuermann DW (1994) NO-synthase-containing neurons of the pig inferior mesenteric ganglion, part of them innervating the ductus deferens. *Acta Anat (Basel)* 151: 62-67.
- Kalczyk J, Timmermans JP, Majewski M, Lakomy M, Scheuermann DW (1995) Distribution and immunohistochemical characteristics of neurons in the porcine caudal mesenteric ganglion projecting to the vas deferens and seminal vesicle. *Cell Tissue Res* 282: 59-68.
- Klimczuk M, Kalczyk J (2010) Distribution and nerve pathways of neurons supplying the bulbourethral gland in the pig. *Cells Tissues Organs* 191: 500-509.
- Klimov A, Akajewski A (1953) *Anatomia zwierząt domowych*, tom II. PWRiL, Warszawa
- Koenig HE, Liebich HG (2007) *Veterinary anatomy of domestic mammals – Textbook and colour atlas*. 3<sup>rd</sup> edition. Schattauer Stuttgart, New York
- Komissarov IV, Krivobok GK (1975) [Adrenoreception characteristics of the neurons of the superior cervical and caudal mesenteric sympathetic ganglia of the cat]. *Biull Eksp Biol Med* 80: 6-9.
- Kostina TF (1971) [Activity of the caudal mesenteric ganglion in relation to afferent impulses (age aspect)]. *Neirofiziologija* 3: 533-542.
- Koval OM, Voitenko LP, Skok MV, Lykhmus EY, Tsetlin VI, Zhmak MN, Skok VI (2004) The beta-subunit composition of nicotinic acetylcholine receptors in the neurons of the guinea pig inferior mesenteric ganglion. *Neurosci Lett* 365: 143-146.



- Kuder T, Nowak E, Szczurkowski A, Kuchinka J (2003) The comparative analysis of the myenteric plexus in pigeon and hen. *Anat Histol Embryol* 32: 1-5.
- Lakomy M, Happola O, Majewski M, Wasowicz K (1996) Distribution of some neuropeptides in the porcine inferior mesenteric ganglion. *Folia Histochem Cytobiol* 34: 85-90.
- Lakomy M, Happola O, Wasowicz K (1994) Immunohistochemical colocalization of Met5-enkephalin-Arg6-Gly7-Leu8 with tyrosine hydroxylase in neurons of the porcine inferior mesenteric and coeliac-superior mesenteric ganglia. *Folia Histochem Cytobiol* 32: 225-230.
- Majewski M, Kaleczyc J, Wasowicz K, Bossowska A, Gonkowski S, Klimaschewski L (2002) Characterization of afferent and efferent galanin-containing nerve fibres in the porcine ovary. *Folia Histochem Cytobiol* 40: 261-268.
- Matthews MR, Cuello AC (1984) The origin and possible significance of substance P immunoreactive networks in the prevertebral ganglia and related structures in the guinea-pig. *Philos Trans R Soc Lond B Biol Sci* 306: 247-276.
- McLachlan EM, Llewellyn-Smith IJ (1986) The immunohistochemical distribution of neuropeptide Y in lumbar pre- and paravertebral sympathetic ganglia of the guinea pig. *J Auton Nerv Syst* 17: 313-324.
- Melman EP, Kapskya EI (1960) Extraspinal pathways in the reflex interaction of large and small intestine. *Bull Exp Biol Med* 50: 28-32.
- Miolan JP, Niel JP (1996) The mammalian sympathetic prevertebral ganglia: integrative properties and role in the nervous control of digestive tract motility. *J Auton Nerv Syst* 58: 125-138.
- NAV (2005) *Nomina Anatomica Veterinaria*, 5<sup>th</sup> Edition. ICVGAN NAVA, Knoxville Nickel R, Schummer A, Seiferle E (2004) *Lehrbuch der Anatomie der Haustiere*, Bd IV, Nervensystem, Sinnesorgane, Endokrine Drüsen. Paul Parey Verlag.
- Nozdrachev AD (1968) [The electrical activity of the caudal mesenteric sympathetic ganglion following adrenalectomy and corticosteroid administration]. *Biull Eksp Biol Med* 65: 35-39.
- Parr EJ, Sharkey KA (1996) Immunohistochemically-defined subtypes of neurons in the inferior mesenteric ganglion of the guinea-pig. *J Auton Nerv Syst* 59: 140-150.
- Pasichnichenko OM, Skok VI (2002) Colonic mechanoreceptor input to neurons in guinea pig caudal mesenteric ganglion. *Neurophysiology* 34: 201-203.
- Pidsudko Z, Kaleczyc J, Majewski M, Lakomy M, Scheuermann DW, Timmermans JP (2001) Differences in the distribution and chemical coding between neurons in the inferior mesenteric ganglion supplying the colon and rectum in the pig. *Cell Tissue Res* 303: 147-158.
- Pidsudko Z, Wasowicz K, Kaleczyc J, Klimczuk M, Bossowska A, Majewski M, Adriaensen D, Timmermans JP (2011) The influence of ileitis on the neurochemistry of the caudal mesenteric ganglion in the pig. *Neurogastroenterol Motil* 23: 213-222.
- Pospieszny N (1977) The aorticordeal ganglion of sheep in the prenatal period. *Folia Morphol (Warsz)* 36: 307-316.
- Pospieszny N (1979) Morphologie und Topographie des brustteiles des Nervus vagus beim Schaf in der pränatalen Periode. *Zoologica Poloniae* 27: 195-225.
- Pospieszny N, Kleckowska-Nawrot J (2002) Analiza morfologiczna zwoju aortowo-nerkowego (ganglion aorticorenale) u kotów rasy pers w okresie okopoporodowym. *Acta Scien Pol* 1: 31-38.
- Pospieszny N, Kleckowska J, Chroszcz A, Juszczyk M (2003) The morphology and development of aorticorenal ganglion (ganglion aorticorenale) in American Staffordshire Terrier in perinatal period. *EJPAU* (online) 6.
- Ribeiro AA, De Souza RR, Barbosa J, Fernandez Filho A (2000a) Anatomic study of the celiac, celiac mesenteric and cranial mesenteric ganglia and its connections in the domestic cat (*Felis domestica*, Linnaeus, 1758). *Braz J Vet Res Anim Sci* 37: 267-272.
- Ribeiro AA, Miglino MA, De Souza RR (2000b) Anatomic study of the celiac, celiac mesenteric and cranial mesenteric ganglia and its connections in cross-bred buffalo fetuses (*Bubalus bubalis* – Linnaeus, 1758). *Braz J Vet Res Anim Sci* 37: 109-114.
- Sann H, McCarthy PW, Schemann M, Jurzak M, Poethke R, Pierau FK (1995) Choline acetyltransferase-immunoreactive neurones in a prevertebral sympathetic ganglion, the inferior mesenteric ganglion. *J Auton Nerv Syst* 54: 195-205.
- Sienkiewicz W (2010a) Immunohistochemical properties of caudal mesenteric ganglion (CaMG) and anterior pelvic ganglion (APG) neurons projecting to the porcine testis in animals subjected to hemicastration, castration and testosterone supplementation. *Bulletin of the Veterinary Institute in Pulawy* 54: 357-367.
- Sienkiewicz W (2010b) Sources of the porcine testis innervation. *Andrologia* 42:395-403.
- Zacharko A, Arciszewski MB, Wasowicz K (2004) Origin of the primary efferent neurons projecting to the prostate of the dog. *Ann Anat* 186: 349-356.