

## Short note

# Detection of active an *Schistosoma haematobium* invasion in a patient, based on the microscopic examination of urine

Hanna ŻARNOWSKA-PRYMEK<sup>1</sup>, Anna RAWSKA<sup>1</sup>, Jakub NIESTĘPSKI<sup>2</sup>,  
Magdalena PLUTA<sup>2,3</sup>, Rusłan SAŁAMATIN<sup>4,5</sup>

<sup>1</sup>Laboratory of Parasitology, Hospital for Infectious Diseases in Warsaw, Warsaw, Poland

<sup>2</sup>Department of Paediatric Infectious Diseases, Hospital for Infectious Diseases in Warsaw, Warsaw, Poland

<sup>3</sup>Department of Children's Infectious Diseases, Medical University of Warsaw, Warsaw, Poland

<sup>4</sup>Department of General Biology and Parasitology, Medical University of Warsaw, Warsaw, Poland

<sup>5</sup>Department of Microbiology and Parasitology, Cardinal Stefan Wyszyński University in Warsaw, Warsaw, Poland

Corresponding Author: Hanna Żarnowska; e-mail: hzarnowska@zakazny.pl

**ABSTRACT.** A parasitological examination of urine from a patient from Cameroon was performed. The eggs of *Schistosoma haematobium* were observed. Most of the eggs were viable and contained miracidia; these were subjected to observation. These observations may be useful in the diagnosis of schistosomiasis.

Supplementary material (video) accompanies this paper, and is available at <https://doi.org/10.17420/ap7003.535.S1>.

**Keywords:** *Schistosoma haematobium*, egg, miracidium, human host, Cameroon, Poland

## Introduction

*Schistosoma haematobium* (Bilharz, 1852) is a parasitic worm (fluke) recorded in almost all African and Middle Eastern countries as well as several locations throughout the Indian subcontinent [1]. The mature forms are found in the venous plexuses of the bladder and pelvis, where the fertilised female lays its eggs inside the capillaries. The larval form (miracidia) then develops within the eggs. Most of the eggs die, but some, due to the presence of a terminal spine, the proteolytic enzymes secreted by the larvae, and the muscle movements of the bladder wall, escape into the bladder and from there, along with the urine, are expelled into the external environment. After a few hours of being in water, the miracidia hatch from the eggs and become free-floating. If the larvae do not encounter a snail of the genus *Bulinus* (intermediate host) within 12 hours, they will begin to die, although some can last up to 48 hours after hatching.

## Materials and Methods

Urine from a 9-year-old boy from Cameroon (who had a referral for a parasitological examination due to recurrent haematuria) was submitted to the laboratory. The boy had been in Poland for 4 months, but prior to this he had spent two years living in the Cameroon countryside where he had regularly bathed in a river. A 50 ml sample of urine was collected at 4 pm (on the day the patient was admitted to hospital), which was then immediately transferred to the laboratory. The material was decanted into six test tubes and centrifuged at 400× g for 3 min. The resulting precipitate was examined microscopically.

## Results and Discussion

On macroscopic evaluation, the urine was clear with a pale yellow colour. *Schistosoma haematobium* eggs were found in the sediment (1–2 in each specimen). Erythrocytes (about 40 within

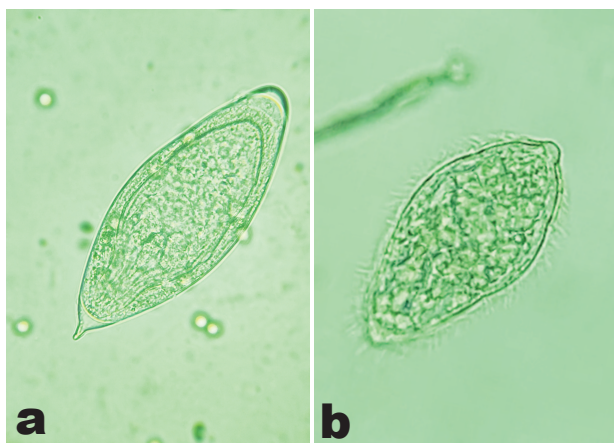


Figure 1. Egg (a) and miracidium (b) of *Schistosoma haematobium*

the field of view), leukocytes (1–6 within the field of view), and a single squamous epithelia, were also identified.

A total of eight eggs (6 live and 2 dead) were observed in the whole sample (Figure 1). The eggs' dimensions were 0.138–0.145 mm × 0.060–0.063 mm. In the live eggs containing miracidia, our attention was drawn to the miracidia's exceptional activity, which we had not previously observed in samples from other patients which we had examined (Supplementary information. Video S1). However, despite the addition of water to the preparation, it was not possible to provoke the rapid hatching of the larvae. In other sediment preparations from the patient's urine left in a humid chamber at room temperature without light, the miracidia hatched after approximately 4 hours.

A second urine sample was collected in the morning of the following day and the whole sample was left to sediment at room temperature without light. The test material was taken directly from the obtained sediment without adding water to provoke the larvae. The test result was similar to the first sample.

Urine is the primary test material for the detection of *Schistosoma haematobium* eggs [2]. The eggs appear in the urine three months after infection (i.e., after the parasites have reached maturity) [3]; however, their appearance in the samples is irregular and in our experience there is a greater chance of detecting them after longer durations, at least several years after invasion (causing more severe lesions in the bladder wall), as more eggs will be available in the urine. Microscopic examination will determine whether the detected eggs of the parasite in question are alive or dead. If live eggs are found, this indirectly

suggests the presence of viable adult forms in the patient's body, which is of clinical significance. In the case presented here, the period of infection could not have been longer than 2 years and 4 months. The patient's ultrasound and CT scan did not show any changes in the bladder wall, nor were there any changes in the urine, except for the presence of erythrocytes and few leukocytes which were found during macroscopic and microscopic evaluation. Given the larvae's exceptional activity, it can be assumed that the eggs had not been in the bladder tissue for very long.

In the available literature, it is recommended that urine for schistosomiasis detection be collected between 12 pm and 3 pm [4], or that the sediment from a full 24-hour collection of urine be examined [5]. In our case, the hour of collection was dependant on the time that the patient reported to the hospital; and, for the following day, on the time treatment was started (the urine was collected before treatment). In situations where there are only a small number of excreted eggs—as in our case and cases where people have spent only a limited time in those countries where schistosomiasis occurs—the method of examining samples collected over a full 24 hours may fail to detect live eggs. Miracidia which have hatched from their eggs may be discarded along with the supernatant after the sedimentation of a sample of such large volumes. It seems safer to take two samples: one in the morning (after overnight stay) and the other between the hours of 12 pm and 3 pm.

### Acknowledgements

We would also like to extend our gratitude to Laurence Taylor of Warsaw for his translation into English.

### Supplementary information

Supplementary information accompanies this paper; see <https://doi.org/10.17420/ap7003.535.S1>.

Additional file 1; Video S1. *Schistosoma haematobium* detected in the patient's urine: eggs and miracidia.

### References

- [1] Hotez P.J., Fenwick A., Kjetland E.F. 2009. Africa's 32 cents solution for HIV/AIDS. *PLoS Neglected Tropical Diseases* 3(5): 1–5. <https://doi.org/10.1371/journal.pntd.0000430>

- [2] U. S. Centers for Disease Control and Prevention. 2024. Clinical Testing and Diagnosis for Schistosomiasis. Schistosomiasis. [cited 2024 Oct 27]. Available from: <https://www.cdc.gov/schistosomiasis/hcp/diagnosis-testing/index.html>
- [3] Garcia L.S. 2016. Diagnostic medical parasitology. (6th ed.). Washington, DC: ASM Press, xxii+1388 p.
- [4] Sastry A.S., Bhat K.S. 2019. Essentials of medical parasitology. (2nd ed.). New Delhi: Jaypee Brothers Medical Publishers, 341 p.
- [5] Doehring E., Feldmeier H., Daffalla A.A. 1983. Day-to-day variation and circadian rhythm of egg excretion in urinary schistosomiasis in the Sudan. *Annals of Tropical Medicine and Parasitology* 77(6): 587–594.  
<https://doi.org/10.137110.1080/00034983.1983.11811757>

*Received 29 August 2024*

*Accepted 25 November 2024*