

Iris Melanoma in a Labrador Retriever

Nobuyuki Kanemaki, DVM, MS, Ph.D.

Diplomate, AiCVO,

Diplomate, JCVO,

Veterinary Teaching Hospital, Azabu University,

Japan

Melanocytoza tęczówki u psa rasy labrador retriever

STRESZCZENIE

U psów stosunkowo często spotykamy w gałce ocznej czerniaki. W przeciwieństwie do czerniaków występujących u kotów, u psów rzadko dają one przerzuty. Wczesne wykrycie tego typu zmian w oku zapobiega dalszym komplikacjom. Praca ta przedstawia przypadek czerniaka tęczówki u psa rasy labrador retriever. Początkowo zmianę tęczówki leczono steroidami i antybiotykami. Lecz leczenie to nie przyniosło oczekiwanych rezultatów. Dalsze diagnozowanie (ultrasonografia, gonioskopia) wykazało, że jest to czerniak. Wykonano resekcję części tęczówki. Siedem tygodni po resekcji zmiany, powrócił odruch źreniczny i widzenie. Badanie histopatologiczne wykazało, że usunięta zmiana to melanocytoza.

KEYWORDS: dog, ocular melanoma, tumor, iris.

Ocular melanoma is the most common tumor that occurs in dogs.¹⁻⁶⁾ Ocular melanomas are known to be malignant in cats, but melanomas are mostly benign in dogs and have a low incidence of metastasis. In dogs melanomas are locally invasive, and the prognosis is poor when they spread to destroy the eyeball.^{5,7)} Therefore, early diagnosis is important for achieving a good prognosis for dogs with ocular melanoma. This study reports a case where a canine ocular melanoma that was localized in the iris was surgically resected to preserve vision.

The patient was a male Labrador Retriever that was 1 year and 4 months old and weighed 28 kg. The dog had undergone physical examination 2 weeks before presentation, during which a mass was found in the iris of the right eye. Steroids and antibiotics were instilled into the eye. But the mass did not regress.

The initial clinical findings on the presentation showed that the dark brown mass, which had a smooth surface, extended from the medial site to the ventromedial site of the iris in the right eye (**Figure 1**). The conjunctiva and cornea were normal. Aqueous flare was not observed, and the pupil was normal in size. The result of the menace, dazzle, and pupillary

light reflex tests indicated normal vision. The mass was restricted by ultrasonography, and the gonioscopy performed subsequently showed that the iridocorneal angle was normal, except in the portion of the tumor (Figure 2). The IOP was 15 mmHg and the STT value was 19 mm/min. The dog was diagnosed with an iris melanoma in the right eye.

The iris melanoma was resected under general anesthesia, by using a disposable cautery (Figure 3). Subsequently, the dog was hospitalized for a week, during which he received intravenous drip infusions of 20% D-mannitol (2 ml/kg, BID), prednisolone sodium succinate (1 mg/kg, BID), and ampicillin (20 mg/kg, TID). Steroid and antibiotic instillation was performed thrice a day, and 3% acetylcystein eye drops were administered 6 days after surgery when a corneal superficial ulcer occurred because of corneal burn after using the disposable cautery (Figure 4). The dog was orally administered bromelain (3500 units/kg, BID) and lysozyme hydrochloride (30mg/head, SID).

Seven weeks after surgery, the vision and pupillary light reflex were normal although a defect was observed in part of the iris (Figure 5).

The pathological findings indicated that the mass contained cells with abundant melanin-containing cytoplasm; the nuclei of the cells were circular or polygonal, as seen in benign melanomas. Only a low level of cell division was observed. The cell division index was 0 or 1 as seen in the melanocytoma.

Ocular melanomas are divided into 2 types; malignant melanoma and melanocytoma (benign melanoma).^{1,2,5} Small local tumors should be excised because the local recurrence rate after resection is 30-40%.² The animal should be regularly followed up after such procedures.

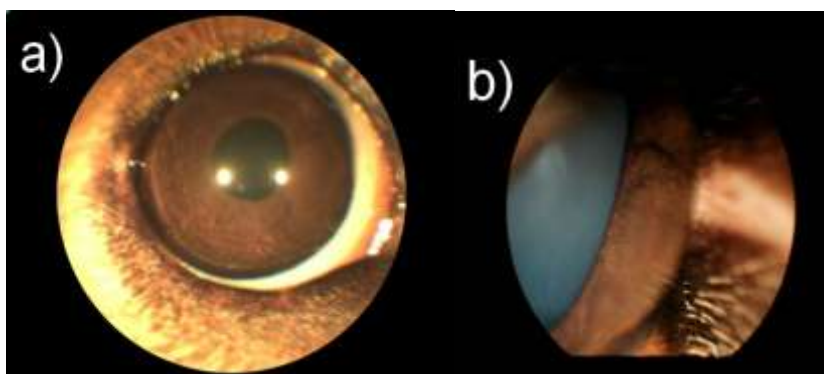


Figure 1. External image of the right eye (a) and the mass in the iris, near the nose (b).

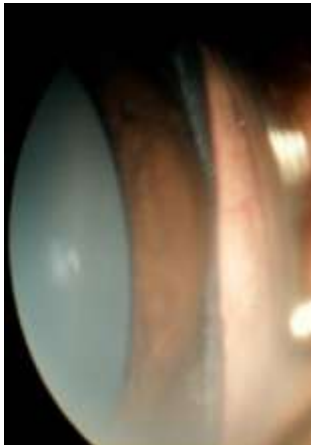

Figure 2. Image of the iridocorneal angle.

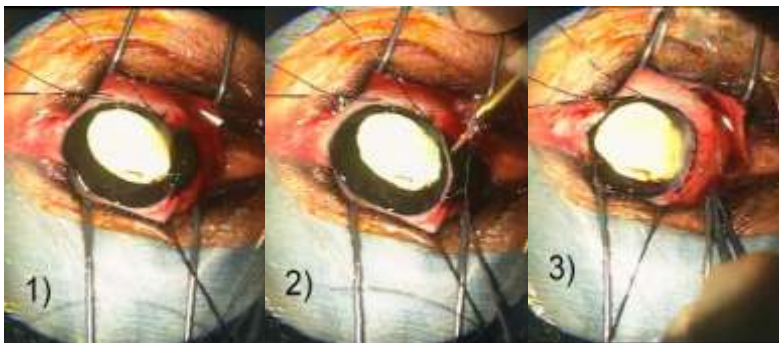


Figure 3. Mass observed on performing a scleral incision (a), tumor resection by using a cautery (b), and closure of the incision (c).

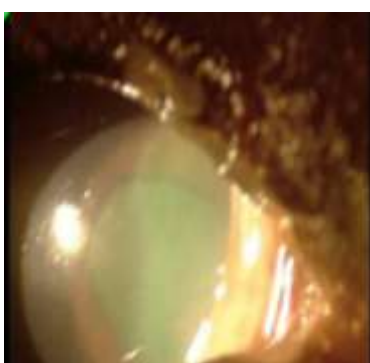


Figure 4. Superficial corneal ulceration 6 days after surgery.

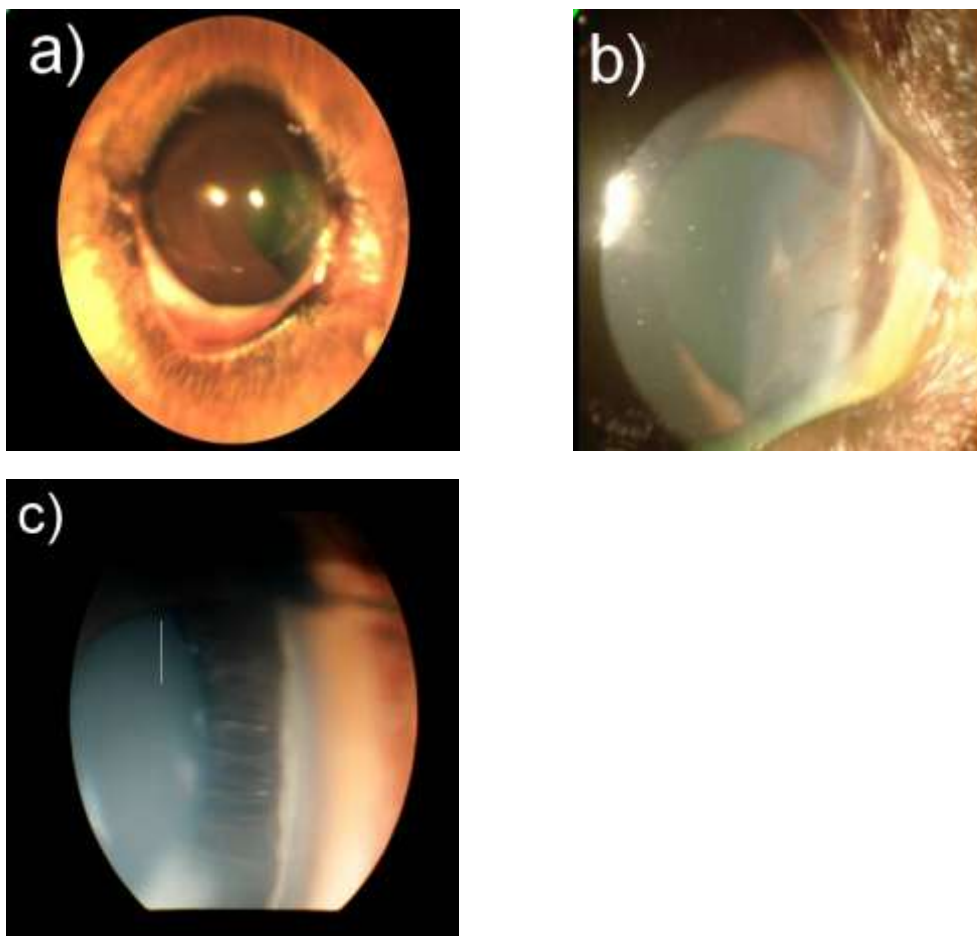


Figure 5. External image of the right eye (a) 6 weeks after surgery, cloudy cornea near the incision (b), and the portion of the iris defect at the iridocorneal angle (c).

References

- 1) Gelatt K.N.: Veterinary Ophthalmology, Diseases and surgery of canine anterior uvea, 2007.
- 2) Wilcock B.P., Peiffer R.L.Jr.: Morphology and behavior of primary ocular melanomas in 91 dogs. Vet Pathol, 23:418-424, 1986.
- 3) Minami T., Patnaik A.K.: Malignant anterior uveal melanoma with diffuse metastasis in a dog. J Am Med Assoc, 201:1894-1896, 1992.
- 4) Diters R.W., Dubelzig R.R., Aguirre G.D., Acland G.M.: Primary ocular melanomas in dogs. Vet Pathol, 20:379-395, 1983.
- 5) Bussanich N.M., Dolman P.J., Rootman J., Dolman C.L.: Canine uveal melanomas: Series and literature review. JAAHA, 23:415-422, 1987.
- 6) Giuliano E.A., Chappell R., Fischer B., Dubielzig R.R.: A matched observational study of canine survival with primary intraocular melanocytic neoplasia. Vet Ophthalmol, 2:

185-190, 1999.

- 7) Ryan A.M., Difers R.W.: Clinical and pathologic features of canine ocular melanomas. J Am Vet Med Assoc, 184: 60-67, 1984.