

Treatment of tibial shaft fractures in sheep using interlocking nails, Schanz screws and type I external fixators

A. Piórek, Z. Adamiak, Y. Zhalniarovich, M. Jaskólska

Department of Surgery and Radiology, Faculty of Veterinary Medicine, University of Warmia and Mazury, Oczapowskiego 14, 10-718 Olsztyn, Poland

Abstract

This paper presents the results of a study of the treatment of transverse tibial shaft fractures in six sheep with the use of interlocking nails and type I external fixators. During surgery, tibial osteotomy was performed to induce an experimental fracture which was stabilized using a type I external fixator. Osteosynthesis was monitored for nine weeks by performing clinical tests, observing the degree of lameness and subjecting the patients to weekly radiological examinations. After nine weeks, the animals were euthanized, and samples of bone callus were sampled for histopathological analyses. Weight bearing on the fractured limb began on day 2 to 4 after treatment. Limb function was fully restored around five weeks after surgery. Radiograms taken during the observation period revealed gradual hyperplasia and progressing mineralization of bone callus at different stages of healing. The histopathological picture of the bone callus was characteristic of the phase of bone turnover and remodeling.

Key words: interlocking nail, bone, fracture, sheep

Introduction

Interlocking nail osteosynthesis is the leading method in the treatment of tibial fractures in humans (Krettek 1997, Folwarczny 2001). This technique is increasingly used in veterinary medicine, but new solutions are required to account for the differences in handling animal subjects. New generations of veterinary interlocking nails are developed to support such applications (Patii 2008, Piórek 2012). One of the latest solutions features a hybrid fixator which combines an interlocking nail with an external fixator system. This construct has been subjected to a series of in vitro biomechanical tests (Bemarde 2001, Radke 2006, Goett 2007), but in vivo studies are scarce

(Moses 2002). The aim of this study was to evaluate the effectiveness of transverse tibial shaft fracture treatment in sheep with the use of interlocking nails and Schanz screws incorporated into a type I external fixator.

Materials and Methods

Experimental animals

The experiment was performed on six female hybrid Merino sheep, aged around 1.5 years, with body weight of 40 kg (+/- 5 kg). The animals were classified for the study based on radiograms of the left tibial

bone in medial and lateral projection. The length of the tibial bone and the width of the medullary cavity at the narrowest section were determined. The animals were kept under identical conditions in specially designed stalls. They were handled in accordance with the provisions of the Animal Protection Act. The study was approved by the Local Ethics Committee at the Faculty of Veterinary Medicine, University of Warmia and Mazury in Olsztyn, under resolution No. 26/2008/N of 29 May 2008.

Fixator

Nails and other elements of the external fixator were manufactured according to the author's design by the Mikromed steelmill in Dąbrowa Górnicza. The nails were made of surgical Steel alloy (316 L) in three sizes (160 mm length with 6 mm and 8 mm diameter, 170 mm length with 8 mm diameter). Interlocking nails were solid rods with a circular cross-section and blunt ends. Each rod featured four transverse openings with a diameter of 4 mm for inserting interlocking screws, with two openings in the proximal section and two in the distal section of the nail. The openings were separated by intervals of 20 mm, inclusive of both ends of the nail. The proximal end was provided with a groove and an internal, longitudinal thread for attaching a guide. A guide was attached to the nail to ensure that pins were correctly aligned with the nail's transverse openings. The interlocking process involved Schanz screws (180 mm length with 2.7 mm diameter) which served as half-pins of the external fixator. A titanium rod with a length of 170 mm and an internal diameter of 6 mm was the frame for the external fixator.

Preoperative preparation, anesthesia and postoperative care

Approximately one hour prior to surgery, the animals were premedicated with the antibiotic amoxicillin trihydrate (Betamox, Scanvet) at 20 mg/kg BW IM and metamizole (Biovetalgin, Biowet) at 50 mg/kg BW IM for pain relief. Directly before surgery, the patients were premedicated with xylazine (Vetaxyl; Vet-Agro) at 0.01 mg/kg BW IM. General anesthesia was induced by an infusion of 10% ketamine (Vetaketam; Vet-Agro) at 22 mg/kg BW IV, and its doses were fractionated subject to the observed effect.

Patients were postoperatively administered the analgesic drug metamizol (Biovetalgin, Biowet), at 50 mg/kg BW IM for 6 days, and the antibiotic amoxicillin (Betamox, Scanvet), at 20 mg/kg BW SC every 48

hours for one week. The site of the implant was dressed, wound dressings were changed weekly and rinsed with 1% aqueous solution of chlorhexidine gluconate.

Surgical procedure

A skin incision with a length of 2-3 cm was made on the medial side of the mid-tibial shaft to produce an experimental fracture in the tibia. The bone was dissected with an oscillating saw.

The tibial bone stabilization procedure was initiated by making a skin incision with a length of ~ 0.5 cm on the medial side of the patellar ligament above the tibial tuberosity. The access on the tibial plane was used to insert a retractor and open the tibial medullary canal. A trocar was used to restore patency of the medullary canal and remove bone marrow. An intramedullary nail was inserted into the proximal fragment of the fractured bone. The above procedure facilitated maximum bending of the knee joint. The nail was inserted from the proximal section towards the distal end of the bone. The previously attached guide was rotated in a semi-circular fashion to facilitate the insertion of the nail. The nail was introduced into the proximal section of the bone to reduce the fracture, and it was further inserted towards the distal end of the bone. At the next stage of the procedure, the nail was fitted into the medullary canal, and was locked relative to the main fragments of the tibia using Schanz screws. The screws were placed in a cannulated guide to ensure that they were correctly aligned with transverse openings without radiological control. Skin incisions were made at the place of contact with the cannulas, and implants were inserted with the use of an orthopedic drill. Interlocking nails were inserted, and the guide was removed. At the last stage of the procedure, skin wounds were sutured using non-absorbable monofilament material (Monosof 2-0). Implants protruding above the skin were connected with the frame of the external fixator. The fixator was assembled, and screws were cut to length.

Monitoring osteosynthesis

Osteosynthesis was monitored by radiological examinations performed weekly, beginning on the day of surgery and ending after nine weeks. Radiograms were obtained using an SP-HF-4 device with the following settings: intensity of 4 mAs, tube voltage – 75 kV, distance from X-ray cassette – 100 cm, in two projections: side (medial – lateral) and sagittal (anterior – posterior). Bone union was evaluated on a four-point grading scale (Edwards 2004).

Table 1. Surgery time, clinical observations and evaluation of bone union.

Sheep	Surgery time in minutes	Clinical observations	Bone union after 9 weeks of treatment
1.	42	discharge in the area of implant in the distal fragment of the bone, loosening of implants in the distal fragment of the bone	++++
2.	38	loosening of the second implant	++++
3.	32	satisfactory implant anchoring	++++
4.	39	discharge in the area of implant in the distal fragment of the bone, loosening of implants	++++
5.	30	satisfactory implant anchoring	++++
6.	36	loosening of implant in the distal fragment of the bone	++++

Evaluation of bone union (Edwards 2004):

+ – weak

++ – fair

+++ – satisfactory

++++ – excellent

Table 2. Lamenes assessment.

Lamenes	1 st degree	2 nd degree	3 rd degree
Sheep I	2 days	3 weeks	5 weeks
Sheep II	2 days	3 weeks	5 weeks
Sheep III	4 days	4 weeks	5 weeks
Sheep IV	4 days	3 weeks	5.5 weeks
Sheep V	3 days	3 weeks	5 weeks
Sheep VI	2 days	3 weeks	5 weeks

Patients were subjected to clinical examinations to determine the degree of lameness and full restoration of limb function. Lameness was evaluated based on the scale proposed by Braden and Brinker (Braden and Brinker 1973). The mobility of the stifle joint and the tarsal joint in the treated limb was monitored by comparison with the opposite leg (Durall 2004).

When bone union was achieved, the animals were euthanized using an overdose of intravenous pentobarbital. The fixator was disassembled, and the treated tibia was removed from the limb. The fracture site was subjected to a mechanical evaluation by attempting to manually bend and break the bone. Sections of the bone callus were stored in 10% neutralized formalin solution for further analysis.

Bone callus samples were decalcified in 100 g sodium citrate solution ($C_6H_5O_7Na_3 \times 2H_2O$), 250 g formic acid solution (CH_2O_2) and 250 g distilled water over a period of one month. Sections of calcified bone samples were obtained with a circular saw, and were decalcified for a further two weeks. The decalcifying agent was replaced three times during this period. Decalcified sections were embedded in paraffin in an

autotechnicon (Microm STP 120 tissue processor, International GmbH) for 24 hours. The resulting paraffin blocks were cut in a sliding microtome (LEICA 2000R) into sections with a thickness of 3-5 μm . The sections were stained with hematoxylin and eosin, and subjected to histopathological analyses.

Results

The average time of surgical treatment was 36 minutes (30-42 min), counting from the moment of tibial osteotomy to incorporating screws into the external fixator (Table 1). Weight bearing on the fractured limb began on day 2 to 4 after treatment. Second degree lameness persisted for three weeks on average. Limb function was fully restored around five weeks after surgery (Table 2).

The results of clinical tests were within the norm. The mobility of stifle and tarsal joints in the treated limb did not deteriorate in comparison with the range of motion observed in the opposite leg. The presence of external elements of the fixator on the medial side

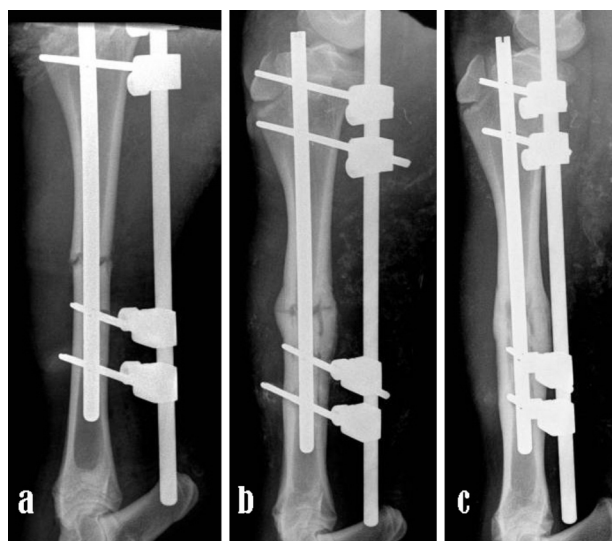


Fig. 1. Radiological examinations of fracture stabilisation in the same sheep in weeks 1(a), 4 (b) and 9(c) of treatment.

Table 3. Histological evaluation of bone callus.

Sheep	Fibroplasia	Chondroplasia	Osteoplasia	Remodeling	Compact bone tissue
1.	+		++	++	++
2.	++		+	++	++
3.	++	+	++	++	++
4.	+		++	+	+
5.	++	+	+	+	++
6.	+		++	++	++

+ – insignificant change

++ – significant change

of the leg was well tolerated by the patients, and did not contribute to movement difficulties. Serous discharge was observed at the site of the implant in several patients (Table 1).

Radiograms taken during the observation period of nine weeks revealed gradual hyperplasia and progressive mineralization of bone callus at different stages of healing (Fig. 1). The images obtained one week after surgery showed a clear contour of the fracture groove. Two weeks after treatment, a light shadow indicative of small amounts of periosteal callus was observed in the fracture site in several patients. As a result of bone turnover and remodeling, the fracture groove began to disappear gradually after three weeks. Radiograms revealed clear periosteal shadows which bridged bone fragments and formed a cuff of callus around the fracture. In week 4, the fracture groove was visibly reduced, and the callus

cuff was represented by a saturated shadow. Clear bridging between the fractured fragments was noted in several animals. The presence of bone union was observed starting in the fifth week after surgery. In weeks 6 and 7, the shadow cast by the bone callus was intensified, and was indicative of progressive bone mineralization. The fracture groove gradually faded away, and it disappeared completely towards the end of the observation period.

A mechanical evaluation which involved attempts to manually bend and break the bone revealed satisfactory strength of the bone callus. No signs of movement or springing of bone fragments were noted.

A histopathological examination of bone callus sections (Table 3) revealed compact bone tissue with normal trabeculae and intertrabecular substance. Spongy bone tissue had a regular structure, and comprised relatively thick trabecula and well-preserved bone marrow. In other layers of the tissue, trabecula

were variously shaped and surrounded by numerous osteoblasts and bone marrow cells. The trabecula showed characteristic signs of bone turnover (Fig. 2). Fibroplastic foci were observed, and some of them contained numerous giant cells. Very large quantities of loose connective tissue and thick collagen fibers with multi-directional arrangement were found in the area of the bone fractures. Intense osteoplasia and numerous osteoblasts were noted in the region of preserved, compact bone tissue. Bone resorption, remodeling and osteoblast proliferation were observed (Fig. 3).

Discussion

In this experiment, the average time of surgical fixation was 36 minutes. In a study carried out by Lu, the procedure of stabilizing a tibial fracture lasted

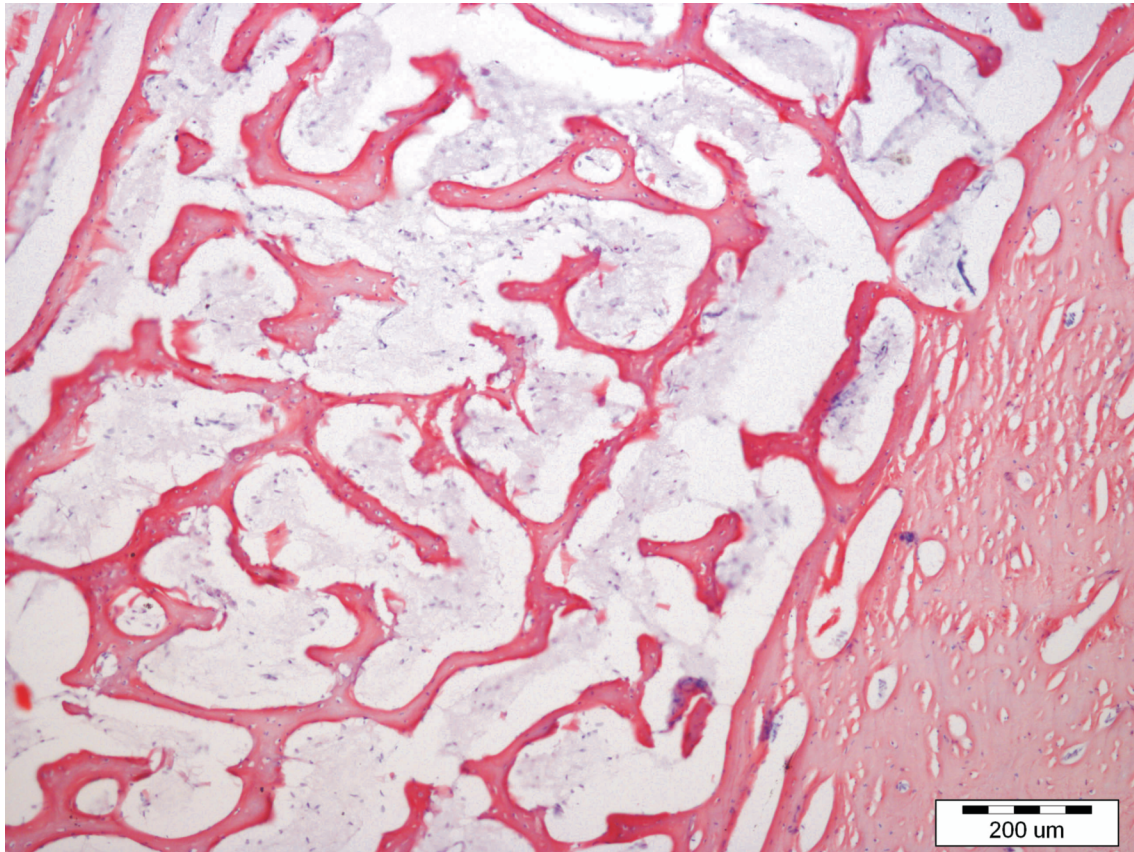


Fig. 2. Histological view of bone scar – lamellar bone.

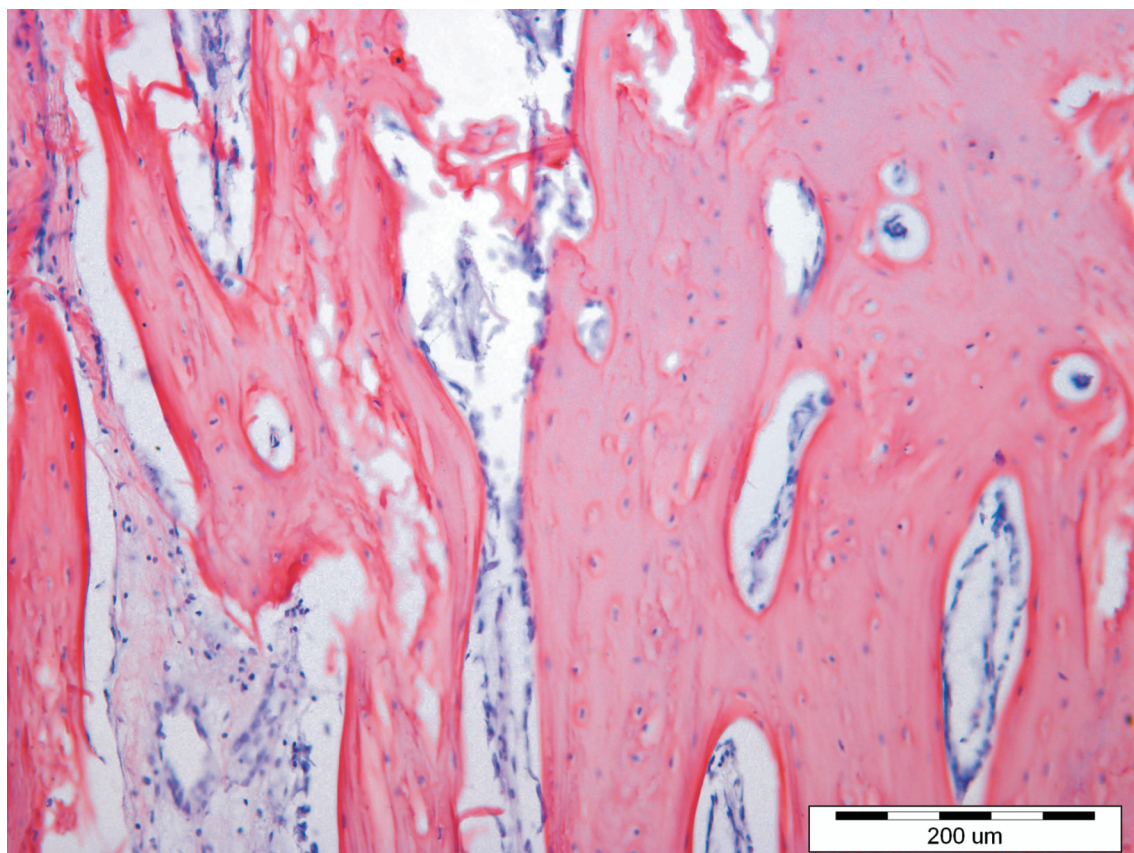


Fig. 3. Histological view of bone scar – bone remodeling.

around 90 minutes with the use of interlocking nails, and around 45 minutes when steel rods were embedded in osseous cement (Braid system) (Lu 2009). By comparison, only 15 minutes were needed to assemble the Maczek external fixator (Jałyński 1999).

The time of surgical fixation is significantly correlated with the risk of infection. According to Cruse and Foord, when other risk factors are excluded, the risk of infection doubles with every additional hour of surgery (Cruse 1980). In a study by Brown, the percentage of postoperative infections in a group of animals subjected to surgical treatment lasting 90 minutes was twice as high in comparison with patients where the procedure was completed in 60 minutes (Brown 1997). Prolonged surgery time increases the probability of infection, and the drying of exposed tissue during the procedure impairs its resistance (Vasseur 1988).

Weight bearing on the treated limb began sooner than in a study carried out with the involvement of the Maczek external fixator, where it started four to eight days after surgery (Jałyński 1999), but later than in an experiment with the Braid fixation which supported functional weight bearing directly after surgical treatment (Lu 2009). In a study where tibial fractures in sheep were treated with the use of a type I external fixation, Klein observed that non-weight bearing lasted for two weeks after surgery, after which weight was gradually applied on the treated limb (Klein 2003).

In dogs which underwent femoral osteotomy and fracture fixation with the use of interlocking nails incorporated in an external fixator, functional weight bearing on the affected limb was not noted in the first week after surgery (Durall 2004). An experiment investigating the osteosynthesis of the canine humerus with the use of interlocking nails provided similar results to those noted in our study. In the cited experiment, limb function was restored within four days after treatment, and it was described as satisfactory or excellent by the authors (Moses 2002).

The use of a type I external fixator in the treatment of limb fractures in sheep resulted in full recovery of limb function after six weeks (Klein 2003). In a study where standard interlocking nails were applied to fix tibial fractures in sheep, full recovery did not take place within nine weeks after the surgery (Klein 2004, Kaspar 2005). In a study by Auger, full restoration of limb function was noted after 7.5 weeks in dogs that had undergone tibial osteotomy and fracture fixation with the use of a type II external fixator (Auger 2002). In sheep fractures fixed with the Braid system or interlocking nails, recovery times ranged from eight to 12 weeks, but animals treated with the application of the Braid system were more likely to apply weight

on the affected limb than the patients in which osteosynthesis was achieved with interlocking nails (Lu 2009).

According to Lu, early weight bearing after surgery involving the Braid fixation system reduces micro-motions at the fracture site (Lu et al. 2009). Micro-motions are caused by instability which is difficult to eliminate in fixation systems that rely on standard interlocking nails (von Pfeil et al. 2005, De Jardin et al. 2006). The work of Kaspar seems to corroborate the above findings (Kaspar et al. 2005).

In our study, functional weight bearing on the treated limb on the second day after surgery can be attributed to greater stability at the fracture site which was achieved by incorporating an interlocking nail with an external fixator. Our findings and the results reported by Klein seem to suggest that the use of a type I external fixator without interlocking nails is unlikely to eliminate micro-motions.

Early restoration of limb function has a positive effect on the further course of treatment. Functional weight bearing on the affected limb speeds up osteosynthesis and increases the strength of the bone callus (Sarmiento 1977, O'Sullivan 1994). According to Klein, the absence of functional weight bearing on the treated limb could produce long-term adverse consequences by delaying bone union (Klein 2004). Full weight bearing with insufficient fracture stabilization could, however, delay osteosynthesis (Augat 1997).

In the present experiment, bone union was observed in X-ray images obtained already in the fifth week of treatment. Radiograms taken in week 9 showed clear bridging between the fractured bone fragments in all sheep. In a study by Kaspar, osteosynthesis was noted after nine weeks of treatment involving interlocking nails and a modified system of screws. X-ray images obtained in the medial and lateral projection revealed the bridging of bone fragments at least in the cortical tissue in all patients. In the same experiment, in fractures treated with interlocking nails and standard screws which allowed for greater mobility of bone fragments, bridging was noted only in selected patients (Kaspar 2005). In the work of Lu, radiological examinations of fractures fixed with interlocking nails as well as the Braid system revealed bone union only in the 12th week of treatment (Lu 2009).

Examinations of bone fragment mobility supply valuable information about the quality of the callus formed. An absence of mobility testifies to the mechanical strength of the bone callus. Springiness of the fracture resulting from the flexibility of undeveloped callus is characteristic of early osteosynthesis, and indicates that bone turnover has not been completed

(Białoszewski 2000). A mechanical evaluation which involved bending of the bone at the fracture site indicated satisfactory strength of the callus.

Histopathological evaluations of bone callus sections provide a detailed insight into osteosynthesis (Brighton 1991). The results of these analyses revealed correct bone union. The features of bone callus formed over the experimental period of nine weeks were characteristic of the stages of bone turnover and remodeling.

In this phase, the newly formed dense fibrous tissue is remodeled, and the remaining fragments of dead bone tissue are removed. This stage is characterized by intensified activity of osteoclasts which, together with osteoblasts, are responsible for bone turnover. The fracture site also features lamellar layers of compact bone tissue which reinforces the entire structure. Osteoclast activity is determined by the number of, and the distance from, osteoblasts. The highest levels of activity are noted in the region of the medullary cavity. Osteoclasts create resorption bays which are directly filled by bone marrow cells. This stage may continue for months or even years, and it ends with the achievement of complete bone union. Compact bone is transformed into lamellar bone, the medullary cavity and osteonic canals are restored together with normal length and shape of the bone (Niedźwiedzki 2007).

In a study of tibial fractures in sheep stabilized with a type I external fixator, histopathological analyses of the callus revealed complete bone union after nine weeks of treatment (Klein 2003, Klein 2004). The fracture groove was completely filled with mineralized bone tissue which bridged the fractured fragments (Klein 2004). In an experiment where tibial fractures in sheep were stabilized with interlocking nails, osteosynthesis was not achieved after nine weeks of therapy. The fracture site comprised mostly fibrous connective tissue, and the fractured fragments were completely bridged only on the lateral side of the bone. As demonstrated by biomechanical tests, stabilization techniques involving interlocking nails were less likely to counteract torsional forces than osteosynthesis methods involving external fixators (Klein 2004). Similar findings were reported by Kaspar who compared the treatment of bone fractures with the use of interlocking nails and standard screws vs. a modified system of screws that ensured a greater degree of rigidity between bone fragments (Kaspar 2005). In the above study, the callus formed after nine weeks of stabilization with a standard interlocking nail, was characterized by a larger cuff of connective tissue in comparison with fractures stabilized by a new interlocking system where the cuff was smaller and the callus comprised mostly mineralized compact bone tissue to in-

dicating complete bone union. In a study comparing callus formations after six weeks of treatment with the involvement of various osteosynthesis techniques, Claes (1999) observed that the formation of internal callus is less intense in methods involving interlocking nails than techniques which rely on external fixators or bridging plates. Similarly to our study, the insertion of interlocking nails did not require openings in the medullary cavity; nevertheless, their presence disrupted blood supply to the inner bone. All osteosynthesis methods, excluding compression techniques, create flexible connections. In this type of stabilization, micro-motion is allowed between bone fragments, and this can both stimulate and inhibit bone union (Niedźwiedzki 2007). Fractured bone fragments become dislocated when transverse force is applied to the fracture line (Sumner-Smith 2002). When the force ceases to act, bone fragments return to their original position owing to the flexible structure of the applied fixator. The same spring-back effect can be generated by interlocking nails (Dueland 1996). In this process, the formation of external callus (Sumner-Smith 2002) is accompanied by the resorption of terminal bone fragments. The groove formed in the bone undergoing resorption is filled with new bone tissue. The formation of external callus begins along the outer edges of the bone, and chondroblasts appear between the fractured fragments. When a flexible connection is formed between those fragments, the callus is transformed into mineralized bone tissue. This process involves endomembranous ossification between the periosteum and the endosteum and endochondral ossification between bone fragments; it initiates the remodeling phase in which woven bone is replaced by lamellar bone.

This study set out to evaluate the effectiveness of nail locking with the use of Schanz screws incorporated into an external fixator. The investigated construct proved to be an effective locking method which is useful in the treatment of fractures with the use of an external fixator. In some animals, small quantities of serous discharge were noted at the site of implant anchoring. Serous discharge is frequently noted when external fixators are used for osteosynthesis, and it results from interactions between the bone and the implant (Hyldahl 1991, Adamiak 2010).

According to other authors, the main weaknesses of the investigated construct include poor anchoring in the cortical bone (Anderson 1993) due to negative threading of the nail, potentially higher risk of implant damage at the point when the threaded section of the nail passes into the unthreaded section, the risk of excessive implant depth which could irritate soft tissues and puncture the skin on the opposite side of the limb, and the need to cut the nails to length after fixator assembly.

Conclusion

The osteosynthesis technique which relies on an interlocking nail integrated with a type I external fixator is highly effective in the treatment of tibial shaft fractures in sheep, and supports quick restoration of limb function in the postoperative period. The use of a type I external stabilizer does not cause movement difficulty. The analyzed fixator is characterized by structural simplicity and ease of assembly. Schanz screws effectively block intramedullary nails and facilitate their incorporation with an external fixator.

References

- Adamiak Z (2010) Use of semicircular external fixators to treat tibial, radial and ulnar fractures in sheep. *Vet Rec* 166: 335-337.
- Anderson MA, Mann FA, Wagner-Mann C, Hahn AW, Jiang BL, Tomlinson JL (1993) A comparison of nonthreaded, enhanced threaded, and Ellis fixation pins used in type I external skeletal fixators in dogs. *Vet Surg* 22: 482-489.
- Auger J, Dupuis J, Boudreault F, Pare P, Beauregard G, Breton L (2002) Comparison of multistage versus one-stage destabilization of a type II external fixator used to stabilize an oblique tibial osteotomy in dogs. *Vet Surg* 31: 10-22.
- Bernarde A, Diop A, Maurel N, Viguier E (2001) An in vitro biomechanical study of bone plate and interlocking nail in a canine diaphyseal femoral fracture model. *Vet Surg* 30: 597-408.
- Białoszewski D (2000) Przegląd konwencjonalnych sposobów oceny gojenia się kości i ich przydatność kliniczna. *Ortopedia Traumatologia Rehabilitacja* 2: 33-36.
- Braden TD, Brinker WO (1973) Effect of certain internal fixation devices on functional limb usage in dogs. *J Am Vet Med Assoc* 162: 642-646.
- Brighton CT, Hunt RM (1991) Early histological and ultrastructural changes in medullary fracture callus. *J Bone Joint Surg Am* 73: 832-847.
- Brown DC, Conzemius MG, Shofer F, Swann H (1997) Epidemiologic evaluation of postoperative wound infections in dogs and cats. *J Am Vet Med Assoc* 210: 1302-1306.
- Claes L, Heitemeyer U, Krischak G, Braun H, Hierholzer G (1999) Fixation technique influences osteogenesis of comminuted fractures. *Clin Orthop Relat Res* 365: 221-229.
- Cruse PJ, Foord R (1980) The epidemiology of wound infection: a 10-year prospective study of 62,939 wounds. *Surg Clin North Am* 60: 27-40.
- Dejardin LM, Lansdowne JL, Sinnott MT, Sidebotham CG, Haut RC (2006) In vitro mechanical evaluation of torsional loading in simulated canine tibiae for a novel hour-glass-shaped interlocking nail with a self-tapping tapered locking design. *Am J Vet Res* 67: 678-685.
- Dueland RT, Berglund L, Vanderby R Jr, Chao EY (1996) Structural properties of interlocking nails, canine femora, and femur – interlocking nail constructs. *Vet Surg* 25: 386-396.
- Durall I, Falcón C, Diaz-Bertrana MC, Franch J (2004) Effects of static fixation and dynamization after interlocking femoral nailing locked with an external fixator: an experimental study in dogs. *Vet Surg* 33: 323-332.
- Edwards RB 3rd, Seeherman HJ, Bogdanske JJ, Devitt J, Vanderby R Jr, Markel MD (2004) Percutaneous injection of recombinant human bone morphogenetic protein-2 in a calcium phosphate paste accelerates healing of a canine tibial osteotomy. *J Bone Joint Surg Am* 86-A: 1425-1438.
- Folwaczny EF, Stiirmer KM (2000) Unusual complications during removal of intramedullary nails after lower leg fractures, tibial shaft fissure and inability to remove the nail. *Eur J Trauma* 27: 184-190.
- Goett SD, Sinnott MT, Ting D, Basinger RR, Haut RC, Dejardin LM (2007) Mechanical comparison of an interlocking nail locked with conventional bolts to extended bolts connected with a type-Ia external skeletal fixator in a tibial fracture model. *Vet Surg* 36: 279-286.
- Hyl Dahl C, Pearson S, Tepic S, Perren SM (1991) Induction and prevention of pin loosening in external fixation: an in vivo study on sheep tibiae. *J Orthop Trauma* 5: 485-492.
- Jalylński M (1998) Leczenie złamań kości długich u owiec przy zastosowaniu stabilizatora zewnętrznego „Maczek” – Doctoral Thesis. University of Warmia and Mazury, Poland.
- Kaspar K, Schell H, Seebeck P, Tompson MS, Schiitz M, Haas NP, Duda GN (2005) Angle stable locking reduces interfragmentary movements and promotes healing after unreamed nailing. Study of a displaced osteotomy model in sheep tibiae. *J Bone Joint Surg Am* 87: 2028-2037.
- Klein P, Opitz M, Schell H, Taylor WR, Heller MO, Kassi JP, Kandziora F, Duda GN (2004) Comparison of unreamed nailing and external fixation of tibial diastases – mechanical conditions during healing and biological outcome. *J Orthop Res* 22: 1072-1078.
- Klein P, Schell H, Streitparth F, Heller M, Kassi JP, Kandziora F, Bragulla H, Haas NP, Duda GN (2003) The initial phase of fracture healing is specifically sensitive to mechanical conditions. *J Orthop Res* 21: 662-669.
- Krettek C, Konemann B, Miclau T, Schandelmaier P, Blauth M, Tschene H (1997) A new technique for the distal locking of solid AO unreamed tibial nails. *J Orthop Trauma* 11: 446-451.
- Lu Y, Nemke B, Lorang DM, Trip R, Kobayashi H, Markel MD (2009) Comparison of a new braid fixation system to an interlocking intramedullary nail for tibial osteotomy repair in an ovine model. *Vet Surg* 38: 467-476.
- Moses PA, Lewis DD, Lanz OI, Stubbs WP, Cross AR, Smith KR (2002) Intramedullary interlocking nail stabilisation of 21 humeral fractures in 19 dogs and one cat. *Aust Vet J* 80: 336-343.
- Niedźwiedzki T, Kuryszko JJ (2007) *Biologia kości*, 1st ed. Wydawnictwo Naukowe PWN, Warszawa.
- O'Sullivan ME, Bronk JT, Chao EY, Kelly PJ (1994) Experimental study of the effect of weight bearing on fracture healing in the canine tibia. *Clin Orthop Relat Res* 302: 73-283.
- Patii DB, Adamiak Z, Piórek A (2008) Veterinary interlocking nailing and its augmentation for fracture repair. *Pol J Vet Sci* 11: 187-191.
- Piórek A, Adamiak Z, Matyjasik H, Zhalniarovich Y (2012) Stabilisation of fractures with the use of veterinary interlocking nails. *Pak Vet J* 32: 10-14.
- Radke H, Aron DN, Applewhite A, Zhang G (2006) Biomechanical Analysis of Unilateral External Skeletal

- Fixators Combined with IM – Pin and Without IM – Pin Using Finite-Element Method. *Vet Surg* 35: 15-23.
- Sarmiento A, Schaeffer JF, Beckerman L, Latta LL, Enis JE (1977) Fracture healing in rat femora as affected by functional weight bearing. *J Bone Joint Surg Am* 59: 369-375.
- Sumner-Smith G (2002) *Bone in Clinical Orthopedics*. 2nd ed., Thieme, Stuttgart – New York.
- Vasseur PB, Levy J, Dowd E, Eliot J (1988) Surgical wound infection rates in dogs and cats. Data from a teaching hospital. *Vet Surg* 17: 60-64.
- von Pfeil DJ, Dejardin LM, DeCamp CE, Meyer EG, Lansdowne JL, Weerts RJ, Haut RC (2005) In vitro biomechanical comparison of a plate – rod combination – construct and an interlocking nail – construct for experimentally induced gap fractures in canine tibiae. *Am J Vet Res* 66: 1536-1543.