

Case reports

An uncommon manifestation of a common disease

Giselle Dsilva, Vrinda Kulkarni, Sangeeta Aher

Department of Medicine, Topiwala National Medical College and B.Y.L. Nair Ch. Hospital, Mumbai-400 008, India

Corresponding Author: Giselle Dsilva; e-mail: dsilvagiselle@gmail.com

ABSTRACT. Neurocysticercosis is the common parasitic disease of the central nervous system. One of the uncommon manifestations and a rare complication is its disseminated form. Human cysticercosis is caused by the spreading of the embryo of *Taenia solium* in the intestine via the hepatoportal system to different tissues and internal organs of the body. The organs most commonly affected are the subcutaneous tissue, skeletal muscles, lungs, brain, eyes, liver, and occasionally the heart, thyroid, and pancreas. We report a case of a 62 year old male, who has been presented, with seizures and subcutaneous nodules on both extremities. After investigation he was diagnosed as a case of disseminated cysticercosis involving brain, subcutaneous tissue, liver, muscles and pericardial fat.

Key words: disseminated cysticercosis, seizure, *Taenia solium*, Albendazole

Introduction

Cysticercus cellulosae is the larval forms of the tapeworm *Taenia solium*. The adult tapeworms are found in the small intestine of humans, the definitive host, and the larval forms are found in the skeletal muscle of the intermediate host, a pig. To develop cysticercosis, a human has to replace the pig in the *Taenia solium* life cycle and the eggs must mature within the human small intestine as they would do in the pig intestine. Entry of the eggs into the human small intestine may occur through autoinfection or by ingestion of egg-contaminated food or water. Finally these cysticerci spread through the intestinal wall and are carried by the blood stream to muscles, brain and subcutaneous tissue, leading to clinical manifestations [1]. Disseminated cysticercosis is an uncommon manifestation of a common disease. With advances in radioimaging techniques more cases of disseminated cysticercosis are being identified in humans. However, fewer than 50 cases have been published worldwide, the majority being from India. In a study of 450 cases of cysticercosis only one case of disseminated disease was seen [2].

Case presentation

We present a case of a 62 year old immunocompetent Hindu male, a native of rural India, farmer by occupation who had migrated to Mumbai 10 years ago. He took a mixed diet. There was no obvious previous history of intestinal worm infection either in the patient or his close contacts. He presented to the emergency department with 2 episodes of generalized tonic clonic seizures. He complained of a generalized headache since 5–6 months. There was no history of limb weakness, diplopia, sensory deficits, bowel or bladder disturbances. There was no history of fever or trauma.

On general examination his vitals were stable. There were multiple subcutaneous nodules over both calves, arms and nape of the neck. The central nervous system and fundus examination were normal. Routine investigations like complete blood count, renal and liver function tests were within normal limits. Stool examination revealed no evidence of ova, cysts or other developmental forms of intestinal parasites. A chest Radiograph revealed multiple calcified nodules over the left middle and lower zones. A computed tomography (CT) scan of the Brain revealed multiple hypodense cystic

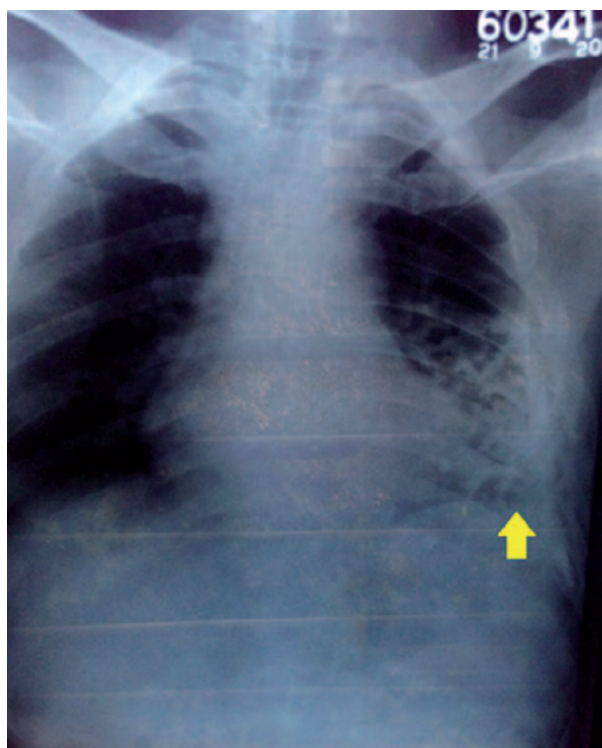


Fig. 1. Chest radiograph showing multiple calcifications in the left lower zone with some overlapping the pericardium (yellow arrow)

lesions in bilateral cerebral hemispheres with eccentric hyperdense foci within and multiple tiny calcified lesions in bilateral cerebral and right cerebellar hemispheres. B scan of both eye sockets was normal. Ultrasonography (USG) of abdomen revealed multiple cystic lesions in the caudate lobe of the liver. A 2D ECHO cardiography showed normal ventricular contractility. In view of the multiple lesions on chest X-ray and the presence of subcutaneous nodules a full body magnetic resonance imaging (MRI) was planned due to a high suspicion of disseminated cysticercosis. On T2 weighted screening MRI showed multiple well defined round to oval cystic lesions many of which

showed eccentric hypodense nodules within in the muscles of bilateral upper and lower limbs, bilateral paraspinal muscles, tongue musculature, left temporalis muscle and thoraco-abdominal wall musculature. Similar lesions are also seen in ventricular myocardium, caudate lobe of liver and right pericardial fat pad.

Patient was started on Tb Albendazole 15 mg/kg/day in two divided doses and Tb Prednisolone 1 mg/kg in tapering doses along with phenytoin for 28 days. He was asked to follow up on OPD basis. Patient completed the course of the treatment. However he developed another two episodes of GTCS after three months even on antiepileptics. A repeat CT Brain on the next admission revealed a decrease in the number of lesions. However there was still persistence of active lesions in the brain. In view of persistent active lesions patient was put on a course of Tb praziquantel 50–100 mg/kg/day in three divided doses with Tb prednisolone 1 mg/kg in tapering doses for 30 days. Tb levetiracetam was started in addition to phenytoin. A review MRI Brain with whole body screening was done after the completion of this regimen which showed a further reduction in the number of active lesions. The patient remains seizure free to this day and has no other complaints.

Discussion

In cysticercosis, the clinical manifestations are variable. Cysticerci can be found anywhere in the body but are most commonly detected in the subcutaneous tissue, skeletal muscles, the lungs, the brain, eyes, the liver and occasionally the heart. Widespread dissemination of the cysticerci can result in the involvement of almost any organ of the body [3]. The main features of disseminated

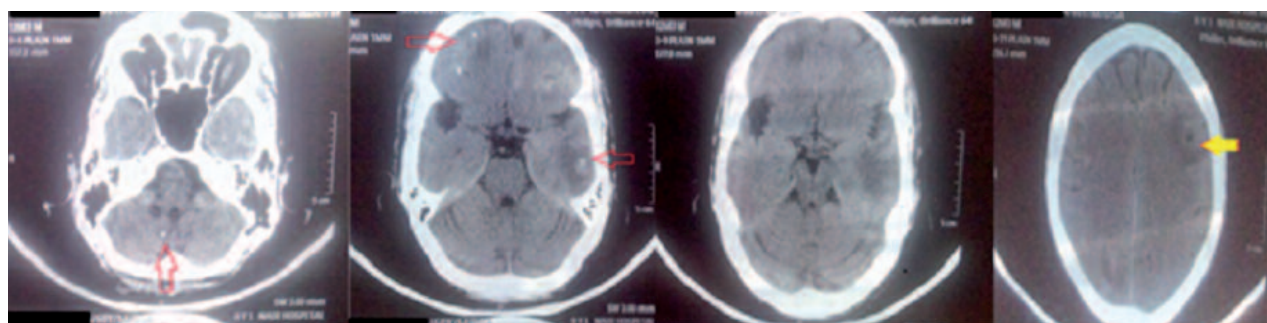


Fig. 2. Plain Computed tomography of brain axial section showing multiple calcified lesions (red arrows) in the right frontoparietal, left temporal and right cerebellar hemispheres. A hypodense lesion (yellow arrow) with eccentric hyperdensity and perilesional edema is seen in the left frontal lobe.

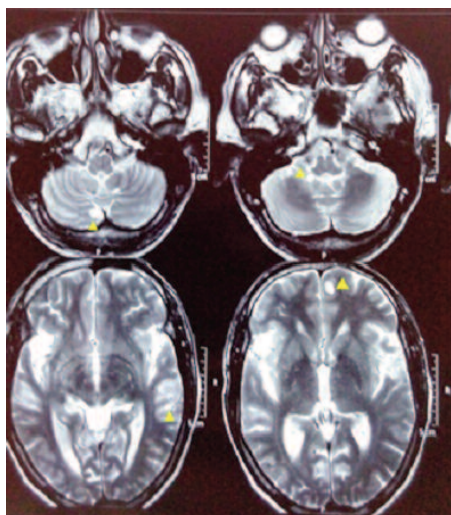


Fig. 3. Magnetic resonance imaging Brain T2 weighted screening axial section showing multiple hyperintense lesions in left frontal and parietal and right cerebellar hemispheres (yellow arrowheads)

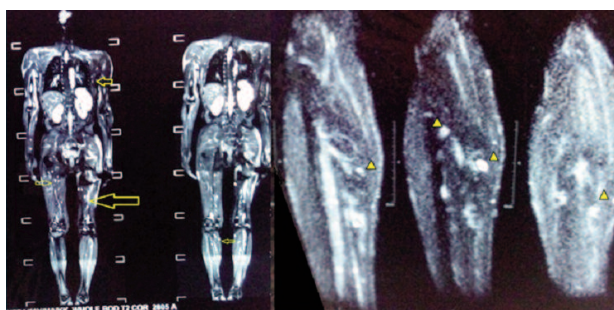


Fig. 5. Magnetic resonance imaging whole body T2 weighted screening and MRI of bilateral lower limbs showing hyperdense lesions (yellow arrows and arrowheads)

cysticercosis include intractable epilepsy, dementia, enlargement of muscles, subcutaneous and lingual nodules and a relative absence of focal neurological signs or obviously raised intracranial pressure, at least until late in the disease [4]. The symptoms are not due to the mere presence of the parasite in the brain, but due to inflammation around the degenerating cysticerci causing focal encephalitis, vasculitis and edema [5]. Computed tomography (CT) scans and MRI are useful in anatomical localization of the cysts and in documentation of the natural history. MRI is more sensitive than CT as it identifies scolex and live cysts in cisternal spaces and ventricles and identifies the response to treatment [6].

Management of disseminated cysticercosis is symptomatic (antiepileptics and steroids), surgical (excision of cysts and ventriculo-peritoneal shunts) and cysticidal. The cysticidal drugs albendazole (15 mg/kg/day for 30 days) and praziquantel (10–15

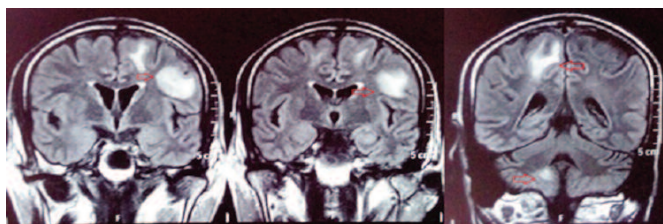


Fig. 4. Magnetic resonance imaging Brain T2 weighted FLAIR (Fluid attenuated inversion recovery) sequence coronal sections showing hyperdense lesions (red arrows) in bilateral fronto-parietal and right cerebellar lesions with perilesional edema

mg/kg/day for 21 days) hasten the death of the cysts which may occur even in the absence of such treatment [7]. There is controversy as to the superiority of one drug over the other and whether both the drugs used simultaneously would be more effective. In a study conducted by Wadia et al. [8] praziquantel was hazardous and associated with severe reactions in which all 3 patients died.

In our patient we used both the drugs serially and praziquantel was effective in further reducing the cyst burden that was persistent after the course of albendazole. Del Brutto et al. [9] had proven in his study that 83% of the patients who had received cysticidal treatment became seizure free when compared to only 26% who did not receive the cysticidal drugs. There is no role for cysticidal drugs in inactive neurocysticercosis where the cysts are calcified [10].

Conclusions

A high suspicion of disseminated cysticercosis should be kept in mind in endemic areas where neurocysticercosis is a common presentation. Appropriate preventive and educative measures like avoiding consumption of unwashed vegetables and maintenance of proper hand hygiene can help in decreasing the prevalence of intestinal taeniosis, autoinfection and thereby cysticercosis in a community. It is also important to identify potential carriers with intestinal *Taenia solium* infection like cooks, street vendors, waiters who are likely to spread eggs among people through their dirty hands and treat them early. Lastly proper diagnostic methods including whole body MRI should be used to detect disease burden and plan the appropriate therapy.

References

- [1] Baily G.G. 2003. Cysticercosis. In: *Manson's Tropical Disease* (Eds. G.C. Cook, A. Zumla). 21st edition. London, Saunders: 1584-1595.
- [2] Dixon H.B.F., Lipscomb F.M. 1961. Cysticercosis: an analysis and follow up of 450 cases. *Medical Research Council "Special Report Series"* 299: 1-58.
- [3] Bhalla A., Sood A., Sachdev A., Varma V. 2008. Disseminated cysticercosis: A case report and review of literature. *Journal of Medical Case Reports* 2: 137. <https://dx.doi.org/10.1186/1752-1947-2-137>
- [4] Krishnaswami C.S. 1912. Case of Cysticercus cellulose. *Indian Medical Gazette* 27: 43-44.
- [5] Carpio A. 2002. Neurocysticercosis: an update. *Lancet Infectious Diseases* 2: 751-762.
- [6] Kumar A., Bhagwani D.K., Sharma R.K., Kavita, Sharma S., Datar S., Das J.R. 1996. Disseminated cysticercosis. *Indian Pediatrics* 33: 337-339.
- [7] Wilson M., Bryan R.T., Fried J.A., Ware D.A., Schantz P.M., Pilcher J.B., Tsang V.C. 1991. Clinical evaluation of cysticercosis enzyme-linked immunoelectro-transfer blot in patients with neurocysticercosis. *Journal of Infectious Diseases* 164: 1007-1009.
- [8] Wadia N., Desai S., Bhatt M. 1988. Disseminated cysticercosis. New observations, including CT scan findings and experience with treatment by praziquantel. *Brain* 111: 597-614.
- [9] Del Brutto O.H., Santibanez R., Noboa C.A., Aguirre R., Diaz E., Alarcon T.A. 1992. Epilepsy due to neurocysticercosis: analysis of 203 patients. *Neurology* 42: 389-392.
- [10] Banu A., Veena N. 2011. A rare case of disseminated cysticercosis: case report and literature review. *Indian Journal of Medical Microbiology* 29: 180-183. doi:10.4103/0255-0857.81787

Received 16 August 2017

Accepted 25 October 2017