

PART I. DISEASES AND PROBLEMS DISTINGUISHED BY WHO AND FAO
DZIAŁ I. CHOROBY I PROBLEMY WYRÓŻNIONE PRZEZ WHO I FAO

**HISTOPATHOLOGICAL RESULTS ANALYSIS IN WOMEN UNDERGOING
HYSTEROSCOPIC PROCEDURES DUE TO ENDOMETRIAL POLYPS**

**ANALIZA WYNIKÓW HISTOPATOLOGICZNYCH U KOBIET PODDAWANYCH
ZABIEGOM HISTEROSKOPOWYM Z POWODU POLIPA ENDOMETRIALNEGO**

Łukasz Szeszko^{1(A,B,D,E,F,G)}, **Przemysław Oszukowski**^{2,3(C,D)}, **Andrzej Kisiel**^{1(C,D)},
Artur Szeszko^{4(E,F)}, **Małgorzata Bieńkiewicz**^{5(C,D)}

¹Obstetrics and Gynecology Ward, the Provincial Specialist Hospital in Biała Podlaska, Poland

²Clinic of Obstetrics and Perinatology, Medical University of Lodz, Poland

³Obstetrics and Gynecology Ward, the Provincial Specialist Hospital in Zgierz, Poland

⁴Medical Student at Jan Kochanowski University in Kielce, English Division, Poland

⁵Department of Quality Control and Radiological Health, Medical University of Lodz, Poland

Authors' contribution

Wkład autorów:

A. Study design/planning

zaplanowanie badań

B. Data collection/entry

zebranie danych

C. Data analysis/statistics

dane – analiza i statystyki

D. Data interpretation

interpretacja danych

E. Preparation of manuscript

przygotowanie artykułu

F. Literature analysis/search

wyszukiwanie i analiza literatury

G. Funds collection

zebranie funduszy

Tables: 2

Figures: 2

References: 13

Submitted: 2018 Dec 13

Accepted: 2019 Jan 3

Summary

Background. Endometrial polyps are the most common pathology of the mucous layer of the uterine cavity. In most cases, they do not cause symptoms and are detected accidentally during ultrasound.

Material and methods. Medical records of 79 patients hospitalized in the Obstetrics and Gynecology Ward of the Provincial Specialist Hospital in Biała Podlaska, who underwent hysteroscopy due to suspicion of endometrial polyps, were analyzed.

Results. In the final histopathological evaluation after the hysteroscopy procedure, presence of endometrial polypoid cells was found in 14 out of 79 women (17.7%).

Conclusions. The final diagnosis of pathological changes in the uterine cavity should be based on hysteroscopic examinations – they enable accurate assessment of the uterine cavity and allow for targeted biopsy collection.

Keywords: endometrial polyp, diagnostic ultrasound, hysteroscopy

Streszczenie

Wprowadzenie. Najczęstszą patologią błony śluzowej jamy macicy są polipy endometrialne. W większości przypadków nie powodują one objawów i są wykrywane przypadkowo, podczas badania USG.

Materiał i metody. Analizie poddano dokumentację medyczną 79 pacjentek hospitalizowanych na Oddziale Ginekologiczno-Położniczym Wojewódzkiego Szpitala Specjalistycznego w Białej Podlaskiej, u których wykonano zabieg histeroskopii z powodu podejrzenia obecności polipa endometrialnego.

Wyniki. W końcowej ocenie histopatologicznej po zabiegu histeroskopii, obecność komórek polipa endometrialnego stwierdzono u 14 spośród 79 kobiet (17,7%).

Wnioski. Ostateczna diagnostyka zmian patologicznych w obrębie jamy macicy powinna opierać się na badaniach histeroskopowych – umożliwiając one dokładną ocenę jamy macicy i dając możliwość pobrania biopsji celowanej.

Słowa kluczowe: polip endometrialny, diagnostyka ultrasonograficzna, histeroskopia

Introduction

The concept of building an ultrasound scanner dates back to the beginning of the 20th century, when German and Russian scientists discovered the possibility of using ultrasound for tracking submarines. The first devices using this phenomenon attracted the interest of medical researchers, who quickly in the 1940s, began to carry out experiments with the use of ultrasound on living organisms. The first devices were used particularly for

Szeszko Ł, Oszukowski P, Kisiel A, Szeszko A, Bieńkiewicz M. Histopathological results analysis in women undergoing hysteroscopic procedures due to endometrial polyps. Health Prob Civil. 2019; 13(2): 99-103. <https://doi.org/10.5114/hpc.2019.81340>

Address for correspondence / Adres korespondencyjny: Łukasz Szeszko, Obstetrics and Gynecology Ward, the Provincial Specialist Hospital in Biała Podlaska, Terebelska 57-65, 21-500 Biała Podlaska, Poland, e-mail: lukasz.szeszko@op.pl, phone: + 48 510 545 863

Copyright: © Pope John Paul II State School of Higher Education in Biała Podlaska, Łukasz Szeszko, Przemysław Oszukowski, Andrzej Kisiel, Artur Szeszko, Małgorzata Bieńkiewicz. This is an Open Access journal, all articles are distributed under the terms of the Creative Commons Attribution-NonCommercial-ShareAlike 4.0 International (CC BY-NC-SA 4.0) License (<http://creativecommons.org/licenses/by-nc-sa/4.0/>), allowing third parties to copy and redistribute the material in any medium or format and to remix, transform, and build upon the material, provided the original work is properly cited and states its license.

diagnostic evaluation of organs such as kidneys, gallbladder and brain, although one of the most spectacular was the diagnosis of fetuses and organs of the genitourinary system.

Nowadays, ultrasound techniques, clearly improved in comparison to the original ones and are the most frequently used methods of imaging. They are still based on the same phenomena as several decades ago. Thanks to ultrasound diagnostics, we can visualize a number of changes and defects of the uterus and ovaries. Gynecological diagnostics of patients of reproductive and postmenopausal age is usually based on vaginal examination. The image of the ultrasonographically examined endometrium is characteristic for a given moment of the menstrual cycle. In the menstrual phase the endometrium is 2-4 mm thick, in the follicular phase it reaches up to 8 mm, in the ovulation phase between 8 and 11 mm and in the luteal phase as much as 14 mm. Measurement disorders can occur with the coexistence of endometrial cancer, endometrial hyperplasia, uterine fibroids, endometrial polyps and mucositis, which is characteristic of miscarriage, postpartum period or an ascending infection. Uterine defects are found in a small percentage of fertile women, and even in 26% of infertile women. For women in which pre-term birth occurred, the percentage is up to 30%. In most cases, changes in the reproductive organs, especially in the initial stage, do not give clinical signs and are therefore not diagnosed. Manifestations in the form of menstrual disorders, pain, abnormal and pathological vaginal bleeding promote a visit to a gynecologist and the detection of functional or anatomical abnormalities of the reproductive organs.

Endometrial polyps are the most common pathology of the uterine mucosa. It is a local hyperplasia of the basal layer of the mucosa of the uterine cavity. Endometrial polyps are a mild change, with a diameter not exceeding 3 cm, most likely caused by unbalanced estrogen stimulation. Most often they grow towards the uterine cavity and are pedunculated. They can be found as single and multiple changes in the uterine cavity. Polyps of the body of the uterus can be found in any period of a woman's life. The frequency of their occurrence is about 10% in women of reproductive age and up to 15% in women in the perimenopausal age. In the vast majority of cases, endometrial polyps do not cause clinical signs and are found during routine gynecological examination and ultrasound imaging. If symptoms manifest themselves, women most often complain of heavy menstrual bleeding, breakthrough bleeding/spotting. These changes in women trying to get pregnant may be the cause of infertility acting in a similar way to an intrauterine device. In ultrasound examination endometrial polyps are shown as limited, hyperechoic (significantly higher echogenicity than the uterus muscle) areas of thickening of the uterine mucosa. The image of an endometrial polyp during hysteroscopy procedure is shown in Figure 1 and Figure 2 [1, 2, 3, 4, 5, 6, 7, 8, 9, 10].

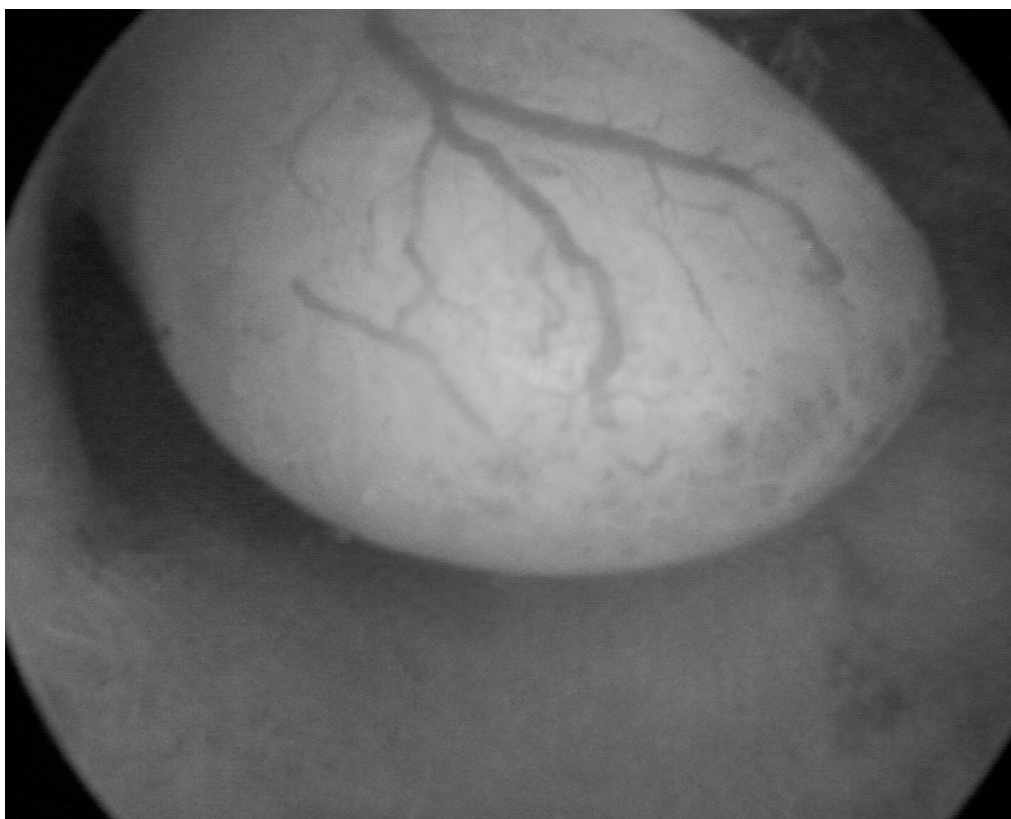

Figure 1. Image of an endometrial polyp during hysteroscopy procedure

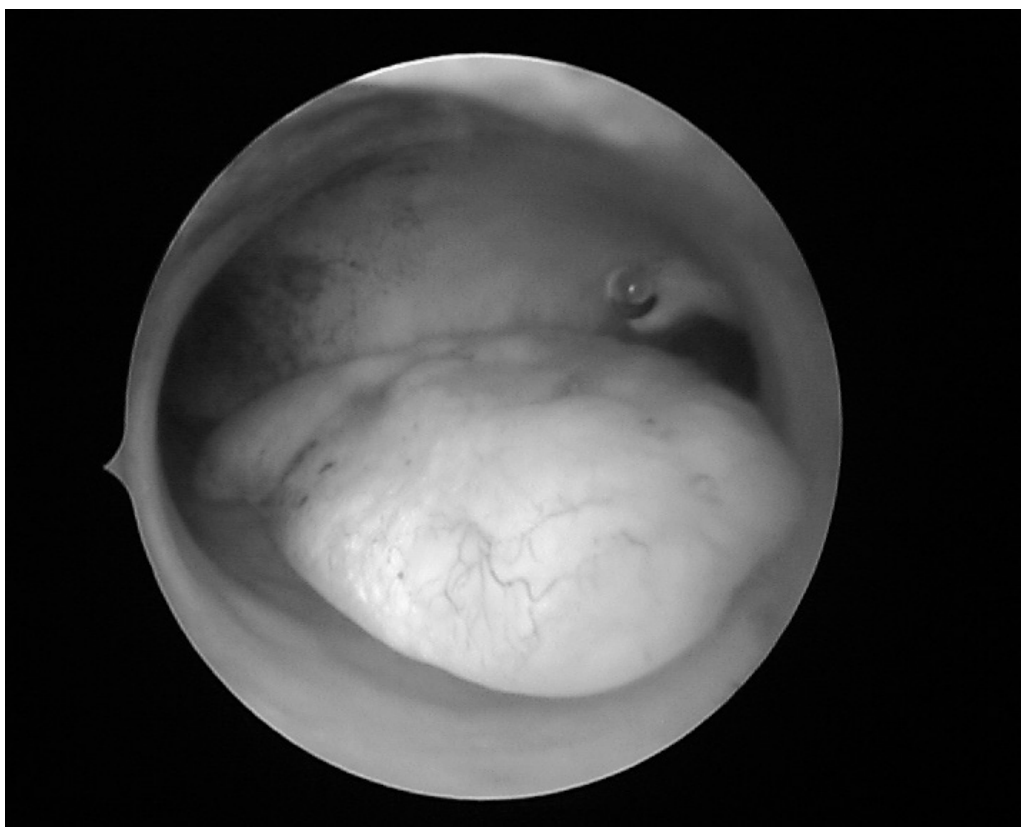


Figure 2. Image of endometrial polyps during hysteroscopy procedure

Material and methods

The material was collected on the basis of retrospective studies conducted on materials and collected as part of routine medical procedures. Medical records of 79 patients hospitalized in the Obstetrics and Gynecology Department of the Provincial Specialist Hospital in Biała Podlaska, who underwent hysteroscopy due to suspicion of presence of endometrial polyps, were analyzed. In the statistical analysis of the study, the basic methods of describing and evaluating the results were used. The analysis was carried out using the statistical package Statistica 12.0. The assumed significance level p was 0.05.

Results

79 women aged from 19 to 75 years (mean age - 46 years) were referred to the hospital with the diagnosis of endometrial polyps. 53 women were of premenopausal age and 26 of them were of postmenopausal age (age > 50 years). In all patient's ultrasound measurement of uterine size was performed. Its longitudinal dimension ranged from 24 to 91 mm (mean 56 ± 13 mm) and its transverse dimension from 18 to 64 mm (mean 42 ± 11 mm).

The endometrium thickness measurement results ranged from 3.9 to 26.1 mm (mean 12.5 ± 5.1 mm). Pathology (thickness >10 mm before menopause or > 4 mm after menopause) was found in 53 subjects (67.1%). The majority of cases of endometrial hyperplasia (34 out of 53) concerned premenopausal women, who constituted the majority of the study group (51 out of 79), but the incidence of endometrial hyperplasia was significantly higher in postmenopausal women (95% vs. 67%). The relationship between menopause age and endometrial hyperplasia was statistically significant ($\chi^2 = 6.1$; $p = 0.014$) (Table 1, Table 2).

Table 1. Table of relationships between age and endometrial hyperplasia

Age	Endometrial hyperplasia		Both
	No	Yes	
Premenopause	17 [33.3%]	34 [66.7%]	51
Postmenopause	1 [5.0%]	19 [95.0%]	20
Both	18	53	71

Table 2. Table of correlations between menopause age and confirmation of polyp diagnosis in histopathological examination

Menopause age	Polyp in histopathological evaluation		Both
	No	Yes	
Before	46 [86.8%]	7 [13.2%]	53
After	19 [73.1%]	7 [26.9%]	26
Both	65	14	79

Hysteroscopy was performed in the whole group of patients:

- in 75 (95%) surgical hysteroscopy,
- in 4 (5%) diagnostic hysteroscopy.

In all 53 women with endometrium hyperplasia, hysteroscopy performed was surgical.

In the final histopathological evaluation after the procedure, the results were as following:

- normal result - 35 (44.3%)
- endometrial hyperplasia without atypia - 18 (22.8%)
- endometrial hyperplasia with atypia - 1 (1.3%)
- endometrial atrophy - 2 (2.5%)
- endometrial polyp - 14 (17.7%)
- uterine fibroid cells - 7 (8.9%)
- cancer cells - 2 (2.5%).

12 (92%) out of 13 patients with histopathologically confirmed polyps which had their endometrium measured earlier had endometrial hyperplasia.

However, the relationship between endometrial pathology and referral accuracy was not statistically significant ($\chi^2 = 1.6$; $p = 0.21$).

Discussion and conclusions

The findings presented in this article highlight an important cause for concern. Out of 79 women referred to the hospital because of endometrial polyps, histopathological confirmation was obtained only in 14 patients. In the majority of cases the initial diagnosis was established on the basis of routine ultrasound examination. Hysterosonography (administration of contrast agent into the uterine cavity) enables improvement of ultrasound imaging and, consequently, better differential diagnostics. Another option for enhanced diagnostics is the use of color Doppler. Characteristic of polypoid lesions is vascularization in the form of one or more vessels penetrating directly into the lesion (these are nutrient vessels). However, the final diagnosis of pathological changes in the uterine cavity should be based on hysteroscopic examinations - they enable accurate assessment of the uterine cavity and allow for targeted biopsy collection. Very often hysteroscopy is not only a diagnostic but also a therapeutic tool [11, 12, 13].

References:

1. Fortunato JS. The use of Power Doppler and color power angiography in fetal imaging. *Am. J. Obstet. Gynecol.* 1996; 174: 1828-1833. [https://doi.org/10.1016/S0002-9378\(96\)70217-X](https://doi.org/10.1016/S0002-9378(96)70217-X)
2. Brązert J, Pietryga M. [Endometrial imaging. Basics of practical ultrasonography in obstetrics & gynecology]. Poznań: Exemplum; 2009. p. 85-90 (in Polish).
3. Barnett S. Recommendation on the safe use of ultrasound. Paper presented at: Proceedings of the Symposium on Safety of Ultrasound in Medicine, WFUMB (World Federation for Ultrasound in Medicine and Biology); 1998.
4. Jędrzejczyk S. [Transvaginal ultrasonography in the assessment of endometrium and pathological changes filling the uterine cavity in postmenopausal women]. *Nowa medycyna.* 1998; 15: 31-34 (in Polish).

5. Kroon C, Bock G, Dieben S, Jansen F. Saline contrast hysterosonography in abnormal uterine bleeding: a systematic review and meta-analysis. *BJOG*. 2003; 110: 938-947.
[https://doi.org/10.1016/S1470-0328\(03\)02472-8](https://doi.org/10.1016/S1470-0328(03)02472-8), <https://doi.org/10.1111/j.1471-0528.2003.02472.x>
6. Alcazar J, Galan M, Minguez J, Garcia-Manero M. Transvaginal color Doppler sonography versus sonohysterography in the diagnosis of endometrial polyps. *J. Ultras. Med*. 2004; 23: 743-748.
<https://doi.org/10.7863/jum.2004.23.6.743>
7. Grimbizis G, Camus M, Tarlatzis B, Bontis J, Devroey P. Clinical implications of uterine malformations and hysteroscopic treatment results. *Human Reproductive Update*. 2001; 7: 162-174.
<https://doi.org/10.1093/humupd/7.2.161>
8. Hata K, Hata T, Manabe A, Makihara K, Kitao M. New pelvic sonoangiography for detection of endometrial carcinoma: a preliminary report. *Gynecol. Oncol*. 1995; 45: 179-184.
[https://doi.org/10.1016/0090-8258\(92\)90282-N](https://doi.org/10.1016/0090-8258(92)90282-N)
9. Dueholm M, Lundorf E, Hansen ES, Ledertoug S, Olsen F. Evaluation of the uterine cavity with magnetic resonance imaging, transvaginal sonography, hysteroscopic examination, and diagnostic hysteroscopy. *Fertil Steril*. 2001; 76: 350-357. [https://doi.org/10.1016/S0015-0282\(01\)01900-8](https://doi.org/10.1016/S0015-0282(01)01900-8)
10. Adel M, Kandil M, Abo-Elnasr M, Sanad Z, Farag H. Three-dimensional sonohysterography may replace hysteroscopy for women with perimenopausal bleeding. *Climacteric*. 2014; 17: 55-9.
<https://doi.org/10.3109/13697137.2013.801014>
11. Callen P. *Ultrasonography in obstetrics and gynecology*. Philadelphia: Saunders/Elsevier; 2008. p. 887-941.
12. Stetkiewicz T, Stachowiak G, Surkont G, Pawłowicz P, Pertyński T. [The role of hysteroscopy in modern diagnostics and therapy]. *Przegl Menopauz*. 2007; 3: 173-6 (in Polish).
13. Tinelli R, Tinelli F, Cicinelli E, Malvasi A, Tinelli A. The role of hysteroscopy with eye-directed biopsy in postmenopausal women with uterine bleeding and endometrial atrophy. *Menopause*. 2008; 15(4): 737-42.
<https://doi.org/10.1097/gme.0b013e31815b644e>