

Autoantibodies spectrum in HCV and HBV infected patients

Joanna Cielecka-Kuszyk¹, Joanna Jabłońska², Tomasz Chmielewski¹, Milena Dunal-Szczepaniak¹, Joanna Siennicka¹

¹ Department of Virology, National Institute of Public Health, National Institute of Hygiene, Warsaw, Poland

² Department of Hepatology and Acquired Immunodeficiencies, Warsaw Medical University, Warsaw, Poland

Cielecka-Kuszyk J, Jabłońska J, Chmielewski T, Dunal-Szczepaniak M, Siennicka J. Autoantibodies spectrum in HCV and HBV infected patients. *J Pre-Clin Clin Res.* 2013; 7(2): 114–117.

Abstract

Hepatitis B and C viruses have the potential for generating autoimmune processes with dysregulation of the cytokines, Th1 chemokines and molecular or epitope mimicry between self-antigens and viral proteins. These phenomena include the production of autoantibodies, but their clinical significance is still unknown. The aim of this study was to determine the presence of autoantibodies in HCV compared to HBV infected patients, and to find the association of their presence with the age, sex and microscopical changes in the liver. The incidence of autoantibodies presence parallel to the liver biopsy was assessed in 363 consecutive patients with hepatitis C, and 71 patients with hepatitis B. It was found that 66 (18%) HCV and 8 (11%) HBV infected patients had positive results. Pathomorphological changes typical for autoimmune hepatitis were not found in this group of patients with viral infection. The HCV infected patients with autoantibodies were significantly older than patients without autoantibodies. This correlation could be connected with the worsening of the self-mechanisms protecting against autoimmune reactions and the longer duration especially of HCV infection. No such similar correlation was observed in the group of HBV infected patients.

Key words

Hepatitis C, Hepatitis B, Autoantibodies

INTRODUCTION

HCV infection is a worldwide health problem concerning about 170 million persons, which is 3% of the world population [1]. Every year, about 3 million people are newly diagnosed as infected with HCV [2]. The HCV infection often progresses to chronic hepatitis (to 85%), cirrhosis (20%) and hepatocellular carcinoma (5%) [3]. Among other viruses, HBV is similar to HCV as a noncytolytic virus with the capacity to induce an inefficient T-cell response unable to completely clear viral antigens from the liver [4].

The systemic HCV-related extrahepatic manifestations, such as mixed cryoglobulinemia, lymphoproliferative disorders, and thyroid autoimmune diseases, are associated with dysregulation of the cytokines and Th1 chemokines and molecular or epitope mimicry between self-antigens and viral proteins [5]. These phenomena include the production of autoantibodies shared with autoimmune hepatitis. However, autoantibodies production could also be related to the direct infection of B lymphocytes [6]. The extrahepatic manifestations connected with HBV infection may occur in up to 10% of patients as polyarteritis nodosa, glomerulonephritis and autoantibodies production [7].

Histological changes in the liver reveal different degree of necroinflammatory activity and fibrosis which can also be found in other infectious and autoimmune hepatitis. However, the overlap of viral and autoimmune disease is very rare. In contrast to this statement, the occurrence of autoantibodies in HCV infection is frequent [8]. HCV infection may lead to the development of autoimmune

processes and production of autoantibodies, such as antibodies to nuclei (ANA), smooth muscle (SMA), liver/kidney microsomes (LKM), mitochondrial autoantibodies (AMA) and parietal cells (APCA). The clinical significance of the presence of these autoantibodies is still unknown. Some authors report that the autoantibody-positive chronic hepatitis C is more common in females and exhibits a more severe biochemical and histological activity [9].

The aim of the presented study was to determine the presence of autoantibodies in HCV compared to HBV infected patients, and to find the association of their presence with the age, sex and microscopical changes in the liver.

MATERIALS AND METHOD

A total of 363 patients infected by HCV (197 males and 166 females, median age 42 yrs) with consecutive liver biopsies were included in the study. All patients were diagnosed on the basis of plasma presence of anti-HCV antibodies by immunoenzymatic method (Abbot, Chicago, USA), and presence of HCV RNA by reverse transcription-polymerase chain reaction (RT-PCR). The control group consisted of consecutive liver biopsies obtained from 71 patients (42 males and 29 female, mean age 35 yrs) with HBV diagnosed on the basis of plasma presence of HBsAg, anti-HBc and HBV DNA (Tab. 1). Parallel to the liver biopsy, sera of all 434 patients were examined for the presence of autoantibodies. Three group of HCV infected patients were compared with the control group of 71 liver biopsies obtained from HBV infected patients.

Examination of autoantibodies. The sera of all 434 patients were screened by IIF parallel to the liver biopsy examination.

Address for correspondence: Joanna Cielecka-Kuszyk, Department of Virology, National Institute of Public Health, National Institute of Hygiene, Warsaw, Poland e-mail: joannack@onet.pl

Received: 27 July 2013; accepted: 17 December 2013

Table 1. Demographic characteristics of HCV and HBV infected patients

	Sex	No patients (%)	Age min-max (mean)
HCV	Female	166 (46)	16–74 (42.8)
	Male	197 (54)	17–71 (41.6)
	Total no patients	363	16–74 (42.2)
HBV	Female	29 (41)	18–72 (36.0)
	Male	42 (59)	14–69 (33.8)
	Total no patients	71	14–72 (34.7)

Rat liver, kidney, pancreas and stomach as a substrate and polyclonal rabbit anti-human IgA, IgG, IgM, kappa and lambda antibodies, labelled with FITC (Dako) were used for detection of antinuclear antibodies (ANA), anti-mitochondrial antibodies (AMA), anti-smooth muscle antibodies (SMA), antibodies to liver/kidney microsome (LKM), anti-parietal cell antibodies (APCA) in patients serum by IIF. Following the recommendations for autoantibody detection by immunofluorescence, positive titer was considered by initial dilution of the examined serum >1:80.

Examination of the liver. The specimens taken by a blind liver biopsy with 1.6 mm needle were fixed in 4% buffered formalin and routinely processed to paraffin. Slides 4 microns thick were stained with H&E, impregnated with silver by the Gomori method for reticulin fibres, and stained by chromotrope 2R and aniline blue for collagen fibres.

Liver changes were diagnosed according to the generally accepted criteria [10]. Examination of the inflammatory activity and stage of fibrosis were performed according to Batts and Ludwig classification [11]. The grade of inflammation (G) was assessed as:

- 0 – inflammation only in the portal tract;
- 1 – minimal inflammation with minimal interface activity;
- 2 – mild inflammation with mild interface activity and/or mild lobular activity;
- 3 – moderate activity with moderate piecemeal necrosis and/or moderate lobular activity;
- 4 – severe activity with severe piecemeal necrosis and/or severe lobular activity.

The stage of fibrosis (S) was assessed as:

- 0 – no fibrosis;
- 1 – fibrous portal expansion;
- 2 – periportal or rare portal-portal septa;
- 3 – fibrous septa with architectural distortion;
- 4 – cirrhosis.

All histological features were finally scored using a two-point scale: low grade according to no/minimal and mild changes (G low, S low) and high grade according to moderate and severe changes (G high, S high) for statistical analysis.

Statistical analysis. For determination of differences between groups the Anova test for data exhibiting normal distribution and the Kruskal-Wallis for non-normal distributed data were used. To compare the distribution, chi-squared test with Yates' correction was used. The $p < 0.05$ was considered as significant and $p < 0.1$ as marginally significant. Statistical analysis was performed using Stat graphics Plus v.4.1. software.

RESULTS

HCV infected patients. In 363 HCV infected patients autoantibodies were found in 66 cases (18%). The patients with autoantibodies presence were significantly older ($p = 0.0052$) than patients without autoantibodies (Fig. 1). The mean age of patients with autoantibodies was 46 years and without autoantibodies 41 years. The occurrence of autoantibodies was marginally significant ($p = 0.084$), and more frequently detected in males (22%) than females (15%).

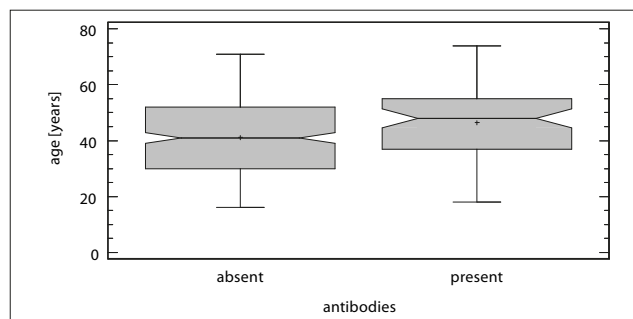


Figure 1. Box and whisker plot showing the distribution of age in group of HCV infected patients with or without autoantibodies (ANA and/or AMA and/or ASMA and/or LKM and/or APCA) presence ($p = 0.0052$)

In the group of 66 autoantibody positive patients, ANA was found in 17 (26%), ANA/SMA in 9 (14%), ANA/APCA in 3 (5%), ANA/LKM in 1 (1%), ANA/AMA in 1 (1%), ANA/SMA/APCA in 1 (1%), SMA in 13 (20%), APCA in 13 (20%), LKM in 5 (8%), AMA in 3 (4%) (Fig. 2A).

The occurrence of necroinflammatory changes (G), fibrosis (S), presence of liver cell steatosis and lymph follicles is presented in Table 2. The distribution of these features in autoantibodies positive and negative HCV infected patients was evaluated. It was found that patients with higher necroinflammatory

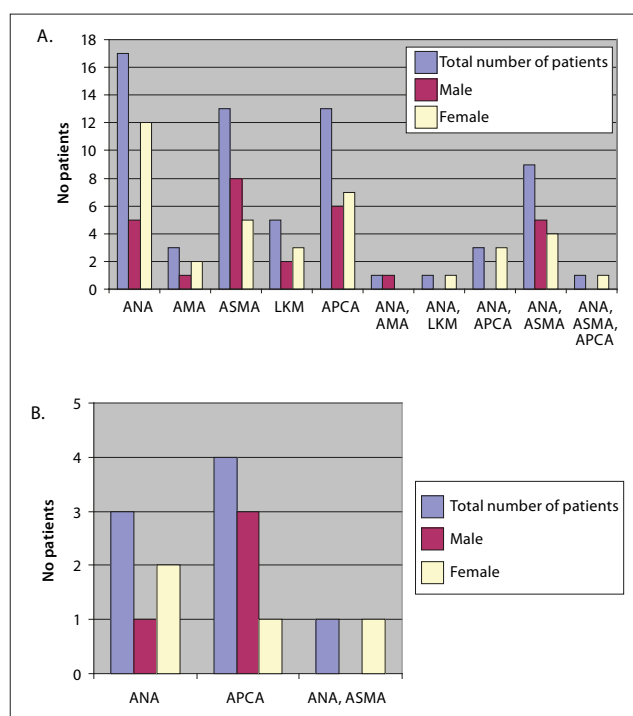


Figure 2. The occurrence of autoantibodies in HCV (A) and HBV (B) infected patients

Table 2. Characteristics of microscopical changes in HCV and HBV infected patients

Total no patients		Necroinflammatory activity (G)		Fibrosis (S)		Steatosis		Lymph follicle
		Mild	Severe	Mild	Severe	Absent	Present	No patients (%)
		No patients (%)	No patients (%)	No patients (%)	No patients (%)	No patients (%)	No patients (%)	
HCV	363	226 (62.3)	137 (37.7)	307 (84.6)	56 (15.4)	175 (48.2)	188 (51.8)	193 (53.2)
HBV	71	51 (71.8)	20 (28.2)	61 (85.9)	10 (14.1)	45 (63.4)	26 (36.6)	16 (22.5)

activity (G high) more frequently produced autoantibodies than those with low necroinflammatory activity (G low) ($p=0.064$). The grade of fibrosis, as well as the distribution of lymph follicles and steatosis, was similar in patients with and without autoantibodies. (Fig. 3A). While the LKM were more frequently detected ($p=0.058$) in patients with severe necroinflammatory changes (G high) in comparison to those with low activity (G low), the presence of other autoantibodies did not correlate with any microscopical changes.

HBV infected patients. Parallel analysis was undertaken for 71 HBV infected patients with and without autoantibodies presence. The mean age of these patients was lower than that of HCV infected patients, and no correlation was found between the age and presence of autoantibodies. The occurrence of necroinflammatory changes (G), fibrosis (S) was similar with HCV infected patients, but the presence of liver cell steatosis was lower and lymph follicles occurred less frequently than in HCV infected patients (Tab. 2). The autoantibodies positive titers occurred less frequently within HBV vs. HCV infected persons (11% vs.18%), but this difference was not statistically significant ($p=0.21$) (Fig. 2B). In the group of 8 autoantibody positive patients, ANA was

found in 3 (38%), APCA in 4 (50%) and ANA/SMA in 1 patient (12%). In contrast to the HCV group, in the HBV group none of the tested parameters (age, sex, G, S, steatosis, lymph follicles presence) were correlated with the presence or absence of autoantibodies (Fig. 3B).

DISCUSSION

Autoantibodies associated with liver diseases occur as specific for autoimmune hepatitis or cholangitis and may also be associated with viral and non-viral diseases. In the literature, the prevalence of closely associated autoantibodies in HCV infected patients was 9–38% for ANA, 5–91% for SMA, 0–10% for LKM, and provisionally associated for APCA and AMA [9, 12]. The material for the current study consisted of 363 sera obtained from patients with HCV infection and 71 sera from patients with HBV infection. The overall prevalence of autoantibodies was 18% and 11%. A high prevalence of APCA in HCV infected patients was also found. These autoantibodies are often observed in children but their clinical significance is still unknown [13].

Despite the marginally statistical difference of the necroinflammatory activity in HCV infected patients with autoantibodies, compared to patients without autoantibodies, the presented study supports the lack of characteristic histopathological changes in the liver in patients with serum autoantibodies. The study shows a correlation between the age of HCV infected patients and presence of autoantibodies. This correlation could be connected with the worsening of the mechanisms protecting against autoimmune reactions and the longer duration, especially of HCV infection. The contribution to worse outcomes of viral hepatitis in the elderly may be associated with several physiological changes, greater prevalence of co-morbid conditions and cumulative exposure to environmental hepatotoxins [14]. The authors have not seen a similar correlation in the group of HCV infected patients.

Autoantibodies in HCV infected group were more common in males and in older patients. This correlation was not found in HBV infected patients. In HCV infected patients, ANA was the most frequent autoantibody, followed by SMA and APCA. A similar prevalence of autoantibodies has been demonstrated in previous studies [15]. Cassani et al. found an association between female gender, transaminases activity and necroinflammatory activity in liver biopsies [9]. In HCV infected patients, the presence of autoantibodies may predict a worse response to the treatment and more severe disease in terms of histological score and serological profile [15, 16]. Other authors have reported that in 1,759 HCV infected patients only 5.2% presented intense interface hepatitis [17]. These patients with severe inflammatory infiltrates in the liver had a low prevalence of autoantibodies, such as ANA in 12% and SMA in 5%, (without LKM) of the examined sera. The presence of intense interface hepatitis was associated with more advanced age, both at the time of infection and at the time of the biopsy. In the presented material, patients with higher necroinflammatory activity more frequently produced autoantibodies than those with low necroinflammatory activity, but it was not statistically significant.

The reactivity of LKM antibodies was found in the sera of 9% of HCV infected patients, but not in the HBV infected patients. The majority of patients with HCV infection and

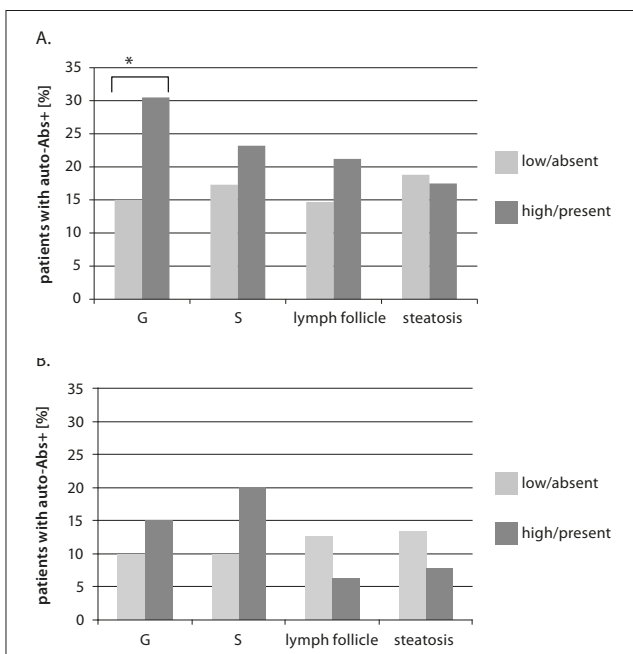


Figure 3. Microscopical changes in 66 autoantibodies positive HCV infected patients (A) and in 8 autoantibodies positive HBV infected patients (B) presented as a percentage of the grade of necroinflammatory activity (G low and G high), stage of fibrosis (S low and S high), presence or absence of lymph follicle, presence or absence of steatosis

LKM antibodies were females [18, 19, 20]. The current finding is in contrast to other publications because the predominance of men is discussed. The reactivity to this antibody has been found more frequently in sera of HCV infected children than in HCV infected adults. The main molecular target for LKM antibodies has been identified as P4502D6 (CYP2D6). The LKM+ sera from HCV infected patients recognize CYP2D6 linear epitopes. The B-type immunologic response against CYP2D6 overlap with that observed in AIH type 2 patients and adults with chronic hepatitis [21, 22]. In the literature, LKM antibodies have been found in the sera 2%-3% of adult HCV infected patients; additionally, they often appear in combination with other autoantibodies ANA, liver cytosol antibodies and antibodies to asialoglycoprotein receptor [26].

The presence of autoantibodies in HCV and HBV infection is also explained by molecular mimicry between viral and host proteins. Gregorio et al. found similarities between HCV polyproteins and human three nuclear proteins such as matrin 3, histone H2, replication protein A, and also between three human smooth muscle proteins: smoothelin, myosin, and vimentin [23]. The evidence for immunological cross-reactivity as a mechanism for the generation of ANA and SMA has been based on following criteria: local sequence homology between HCV and human smooth-muscle and nuclear components, the potential of homologous HCV peptides to serve as B-cell epitopes, simultaneous recognition of HCV and self peptides by HCV sera, specificity of the antiself response to HCV infection, the capacity of HCV peptides to competitively inhibit antibody recognition of homologous self peptides. [23]. HBV proteins show cross-reactivity with nuclear proteins and smooth muscle caldesmon and myosin [24, 25].

CONCLUSION

In summary, HCV infected patients were found to have a higher incidence of autoantibodies, compared to HBV infected patients. The presence of autoantibodies correlated with the age of patients and were more common in patients with severe necroinflammatory activity. The same correlation was not observed in HBV infected patients. Although no concomitant autoimmune hepatitis, patients with autoantibodies should be monitored for the development of autoimmune diseases.

REFERENCES

1. National Institutes of Health National Institutes of Health Consensus Development Conference Statement. Management of hepatitis C. *Hepatology* 2002; 36: 3–20.
2. World Health Organization. Hepatitis C Fact. 2012, sheet N° 164 www.who.int/mediacentre/factsheets/fs164/en/ (access: 2013.07.23).
3. Alter HJ, Seeff LB. Recovery, persistence and sequelae in hepatitis C virus infection: a perspective on long-term outcome. *Semin Liver Dis* 2000; 20: 17–35.
4. Guidotti LG, Chisari FV. Immunobiology and pathogenesis of viral hepatitis. *Ann Rev Pathol*. 2006; 1: 23–61.
5. Oldstone MB. Molecular mimicry and immune-mediated diseases. *FASEB J*. 1998; 12: 1255–1259.
6. Zignero AL, De Carli M, Monti M, Careccia G, La Villa G, Gainini C et al. Hepatitis C virus infection of mononuclear cells from peripheral blood and liver infiltrates in chronically infected patients. *J Med Virol*. 1995; 47: 58–63.
7. Terrier B, Cacoub P. Hepatitis B virus, extrahepatic immunologic manifestations and risk of viral reactivation. *Rev Med Interne*. 2011; 10: 622–627.
8. Jarmay K, Karakcseny G, Ozvar Z et al. Assessment of histological features in chronic hepatitis C. *Hepatogastroenterology* 2002; 49: 239–243.
9. Cassani F, Cataleta M, Valentini P et al. Serum autoantibodies in chronic hepatitis C: comparison with autoimmune hepatitis and impact of the disease profile. *Hepatology* 1997; 26(3): 561–566.
10. Desmet VJ, Gerber M, Hoofnagle JH, Manns M, Scheuer PJ. Classification of chronic hepatitis: diagnosis, grading and staging. *Hepatology* 1994; 19: 1513–1520.
11. Batts KP, Ludwig J. Chronic hepatitis. An update on terminology and reporting. *Am J Surg Pathol*. 1995; 19: 1409–1417.
12. Muratori P, Muratori L, Stroffolini T, Pappas G, Terlizzi P, Ferrari R et al. Prevalence of non-organ specific autoantibodies in HCV-infected subjects in the general population. *Clin Exp Immunol*. 2003; 131: 118–121.
13. Gregorio GV, Pensati P, Iorio R, Vegnente A, Mieli-Vergani G, Vergani D. Auto-antibody prevalence in children with liver disease due to chronic hepatitis C virus (HCV) infection. *Clin Exp Immunol*. 1998; 112: 471–86.
14. Carrion AF, Martin P. Viral hepatitis in the elderly. *Am J Gastroenterol*. 2012; 107(5): 691–697.
15. Wasmuth H, Stolte C, Geier A, Dietrich C, Gartung C, Lorenzen J, Matern S, Lammert F. The presence of non-organ specific autoantibodies is associated with a negative response to combination therapy with interferon and ribavirin for chronic hepatitis C. *BMC Infect Dis* 2004 <http://biomedcentral.com/1471-2334/4/4> (access; ...).
16. Cielecka-Kuszyk J, Komorowski M, Godzik P, Jablonska J, Madalinski K. Non organ specific and parietal cell autoantibodies in chronic liver diseases evaluated in the National Institute of Hygiene. *E&C Hepatology* 2011; 7(91–2): 39–43.
17. Badiani RG, Becker V, Perez RM et al. Is autoimmune hepatitis a frequent finding among HCV patients with intense interface hepatitis? *WJG*. 2010; 16(29): 3704–3708.
18. McFarlane IG, Smith HM, Johnson PJ, Bary GP, Vergani D, Williams R. Hepatitis C virus antibodies in chronic active hepatitis: Pathogenetic factors or false-positive result? *Lancet* 1990; 335: 754–757.
19. Lunel F, Abuf N, Franguel F. Liver/kidney microsome antibody type 1 and hepatitis C virus infection. *Hepatology* 1992; 1: 359–364.
20. Fallahi P, Ferri C, Ferrari SM, Corrado A, Sansonno D, Antonelli A. Cytokines and HCV-related disorders. *Clin Develop Immunol*. 2012.
21. Herzog D, Yamato A, Jara P, Maggione G, Sarles J, Alvares F. Sera of children with hepatitis C infection and Anti-Liver-Kidney Microsome-1 Antibodies recognize different CYP2D6 epitopes than adults with LKM+/HCV+ sera. *J Pediatr Gastroenterol Nutr*. 1999; 29(5): 551–555.
22. Karlsen AE, Dyrberg T. Molecular mimicry between non-self, modified self and self in autoimmunity. *Semin Immunol*. 1998; 10: 25–30.
23. Gregorio GV, Ghoudhuri K, Ma Y. Mimicry between the hepatitis C virus polyprotein and antigenic targets of nuclear and smooth muscle antibodies in chronic hepatitis C virus infection. *C; In Exp Immunol*. 2003; 133: 404–413.
24. Gregorio GV, Ghoudhuri K, Ma Y, Vegnente A, Vergani GM, Vergani D. Mimicry between the hepatitis B virus DNA polymerase and the hepatitis B virus infection. *J Immunol*. 1999; 162: 1802–1810.
25. Cusick M, Libbey JE, Fujinami RS. Molecular mimicry as a mechanism of autoimmune disease. *Clin Rev Allergy Immunol*. 2012; 42(1): 102–111.