

Pathological phalanges in a camarasaurid sauropod dinosaur and implications on behaviour

EMANUEL TSCHOPP, OLIVER WINGS, THOMAS FRAUENFELDER,
and BRUCE M. ROTHSCHILD



Tschopp, E., Wings, O., Frauenfelder, T., and Rothschild, B.M. 2016. Pathological phalanges in a camarasaurid sauropod dinosaur and implications on behaviour. *Acta Palaeontologica Polonica* 61 (1): 125–134.

Several types of pathological bony overgrowth are known from various dinosaur taxa but, except for stress fractures, are rarely reported from appendicular elements. Herein we describe pathological manual and pedal phalanges of a camarasaurid sauropod (SMA 0002), which show features rarely recognised in non-avian dinosaurs. They include lateral osteophytes and smoothing of phalangeal articular surfaces, a deep pit, proximal enthesophytes in pedal unguals, distal overgrowth associated with a fracture, and a knob-like overgrowth lateral to the distal condyles of a pedal phalanx. Their causes were assessed by means of visual examination, CT scans, and bone histology, where possible. The lateral osteophytes are interpreted as symptoms of osteoarthritis. The ossified tendon insertions in the unguals are most probably the result of prolonged, heavy use of the pedal claws, possibly for scratch-digging. The distal overgrowth is interpreted to have developed due to changed stress regimes, and to be the cause for the fracture. The deep pit represents most likely a case of osteochondrosis, whereas the knob-like overgrowth likely represents a post-traumatic phenomenon not previously reported in dinosaurs. The study confirms that a rigorous assessment of pathologies can yield information about behaviour in long-extinct animals.

Key words: Dinosauria, Sauropoda, camarasaurids, paleopathology, osteoarthritis, enthesophytes, osteochondrosis, bone tumour, Morrison Formation, Jurassic, USA, Wyoming.

Emanuel Tschopp [etschopp@unito.it], *GeoBioTec, Faculdade de Ciências e Tecnologia, Universidade Nova de Lisboa, 2829-516 Caparica, Portugal*; *Museu da Lourinhã, Rua João Luis de Moura, 2530-158 Lourinhã, Portugal*; *Dipartimento di Scienze della Terra, Università di Torino, Italy*.

Oliver Wings [dr.wings@gmail.com], *Niedersächsisches Landesmuseum Hannover, Willy-Brandt-Allee 5, 30169 Hannover, Germany*; *Museum für Naturkunde Berlin, Invalidenstraße 43, 10115 Berlin, Germany*.

Thomas Frauenfelder [thomas.frauenfelder@usz.ch], *Institute of Diagnostic and Interventional Radiology, University Hospital Zurich, Rämistr. 100, 8091 Zürich, Switzerland*.

Bruce M. Rothschild [spondylair@gmail.com], *Carnegie Museum of Natural History, 4400 Forbes Ave, Pittsburgh, PA 15213, USA*; *Department of Geology, University of Kansas, Lawrence, Kansas 66045, USA*; *Department of Medicine, Northeast Ohio Medical University, Rootstown, Ohio 44272, USA*.

Received 4 September 2014, accepted 1 December 2014, available online 18 December 2014.

Copyright © 2016 E. Tschopp et al. This is an open-access article distributed under the terms of the Creative Commons Attribution License (for details please see <http://creativecommons.org/licenses/by/4.0/>), which permits unrestricted use, distribution, and reproduction in any medium, provided the original author and source are credited.

Introduction

A wide variety of pathologies has been reported from fossil dinosaur bones in the past, including osteoarthritis (see Rothschild and Martin 1993; Tanke and Rothschild 1997), osteochondrosis (e.g., Rothschild and Tanke 2007), reactive bone growth after injuries (e.g., Tanke and Rothschild 2010; Evers et al. 2015), or developmental failures (e.g., Lovelace 2014). However, an accumulation of various pathological features in a single individual is rare. The herein reported manus and pedes of the camarasaurid sauropod specimen

SMA 0002 show five different bone anomalies, four of which are various kinds of overgrowths.

Pathologies detectable in bones are often induced by trauma, and can thus record particular moments or recurrent activities in an animal's life, and give insights into behaviour and activity (Rothschild and Tanke 1992; Tanke and Currie 1998; Rothschild and Molnar 2005; Tanke and Rothschild 2010; Rega 2012; Evers et al. 2015). In dinosaurs, for example, analyses of healed rib fractures and skull lesions in ceratopsians showed that genera other than *Triceratops* with its well-developed nasal and brow horns rather used flank-butting behaviour than head-to-head encounters for establish-

ing dominance (Farlow and Dodson 1975; Farke et al. 2009; Tanke and Rothschild 2010). Healed bite marks in tyrannosaur skulls were interpreted as dominance or territorial behaviour against other tyrannosaurids, given the good fit of tyrannosaur tooth shape and the bite marks (Tanke and Currie 1998). Also, occurrences of thumb deformation in two specimens of chasmosaurine ceratopsians were used to infer locomotion patterns in the forelimb (Rega et al. 2010). These reports show that the study of paleopathology is a promising approach for new information on the biology of extinct animals.

As the “-itis” suffix semantically implies inflammation, its use in naming this non-inflammatory form of arthritis is paradoxical but represents what has been standard usage in the medical literature. There has been a trend to replace it with the more etiologically accurate term osteoarthritis. Because it is often complicated by an inflammatory crystalline arthritis (calcium-pyrophosphate deposition disease; Rothschild and Martin 2006), we have elected to continue the convention and general usage in paleopathologic descriptions of calling it osteoarthritis in this article.

Institutional abbreviations.—CPT, Conjunto Paleontológico de Teruel, Dinópolis, Teruel, Spain; SMA, Sauriermuseum Aathal, Switzerland; Tate, Tate Geological Museum, Casper, Wyoming, USA.

Anatomical abbreviations.—phm II-2, second phalanx of manual digit II; php III-1, first phalanx of pedal digit III.

Material and methods

The pathological manual and pedal phalanges are from specimen SMA 0002. It was found in the Upper Jurassic Morrison Formation at Howe-Stephens Quarry, north of Shell, Wyoming in 1992 (Ayer 2000). The specimen is an almost complete skeleton. It was identified as *Cathetosaurus*, based on the morphology of the pelvic girdle and dorsal transverse processes (Mateus and Tschopp 2013), but a more recent preliminary specimen-based phylogenetic analysis favors an identification as *Camarasaurus* (ET, unpublished data). Further studies are in preparation to clarify the exact identification of the specimen. All four autopodia were found in articulation with the rest of the skeleton (Tschopp et al. 2015). Histologic studies showed that the specimen is a very old adult (Klein and Sander 2008; Waskow and Sander 2014).

Foot bones were photographed, drawn, and compared to other taxa. A CT scan of the left manus was carried out with a medical CT scanner (Somatom Definition 64, Siemens, Germany) at the University Hospital Zurich, Switzerland. The manus was scanned using a dedicated CT protocol with a slice thickness of 1.5 mm. All images were stored in the DICOM-III-format.

Textured 3D models from pathologic phalanges were produced with photogrammetry (see SOM, Supplementary

Online Material available at http://app.pan.pl/SOM/app61-Tschopp_etal_SOM.pdf). One element was digitized per pathological type as described below (L php I-2 for type 1; R phm III-1 for type 2; L phm IV-1 for type 3; L php IV-1 for type 4; L php II-1 for the pit). Digital photographs were taken with a Nikon D40 and subsequently processed with the methods described by Mallison and Wings (2014) in the photogrammetric software Agisoft PhotoScan Professional 1.0.4 build 1847 (64 bit) with generally high settings.

Thin sections of the bone overgrowth from the first right pedal ungual were made at the Steinmann Institut für Paläontologie der Universität Bonn, Germany, and studied and photographed under light microscope at the Paläontologisches Institut und Museum der Universität Zürich, Switzerland.

Osteological description

Four different types of bone overgrowth were detected in the manus and pedes of SMA 0002 (Fig. 1). They are herein termed types 1 to 4. Additionally, a deep pit originally identified as extreme case of eburnation (Tschopp 2010) is described in detail and its cause reassessed.

Overgrowth type 1.—Proximal extensions are present above the proximal articular surface of nearly all pedal unguals (Figs. 2–4; see SOM for a textured 3D model of the left php I-2). Where completely preserved, the overgrowth is flat with a triangular outline, and appears to follow the curvature of the dorsal edge of the articular facet. In the left php I-2, the base of the triangle is oriented mediolaterally (Fig. 2). With its concave plantar face, this small ossification enlarges the articulation facet for the distal condyles of php I-1. The overgrowth fits nicely into the dorsal depression of the distal articular surface of the previous phalanx. In the right pes, a slightly larger piece of bone is preserved in the upper part of the proximal surface of the first ungual (Fig. 3A). It has been separated from the right claw during preparation, but is still stored with the original, currently not mounted unguals of the right pes. Other than the medi-

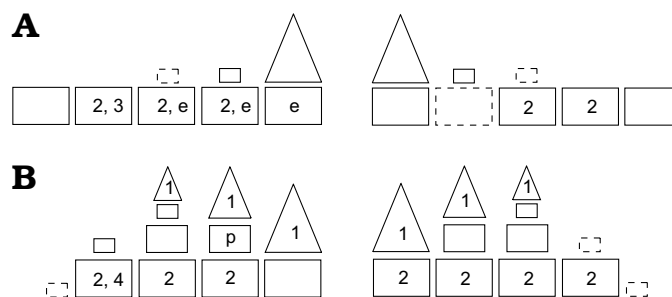


Fig. 1. Schematic drawing of the left and right manual (A) and pedal (B) phalanges of the camarasaurid sauropod SMA 0002, marking the elements affected by pathologies described herein. Rectangles are normal phalanges, triangles are unguals. Dashed lines indicate lacking elements. Numbers correspond to the overgrowth types as defined in the text; e, possible eburnation; p, deep pit.

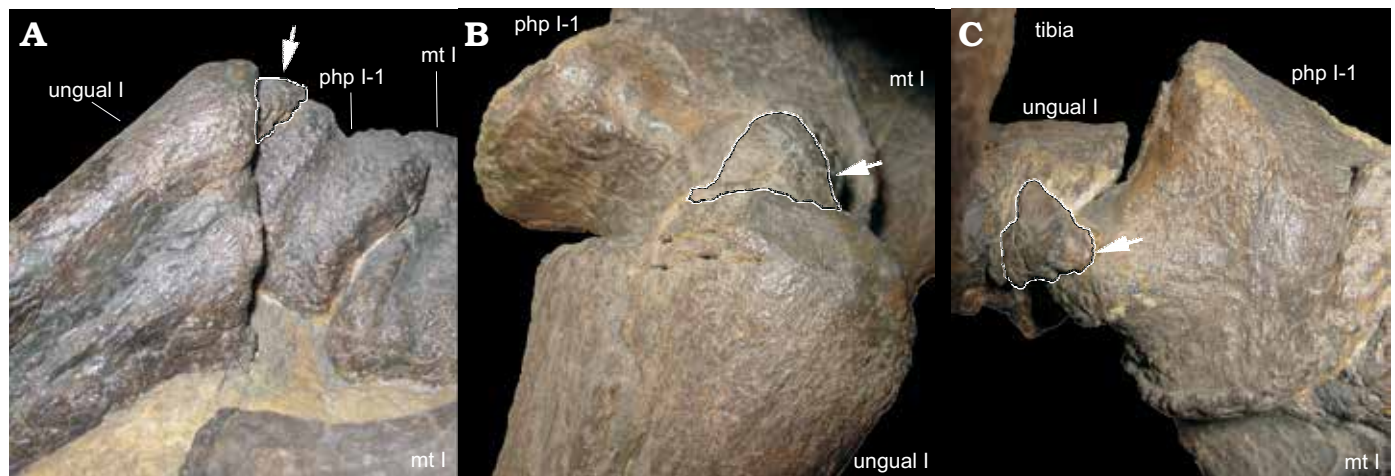


Fig. 2. Overgrowth type 1 (arrow) in left pedal ungual I of the camarasaurid sauropod SMA 0002 from Upper Jurassic Morrison Formation, Howe-Stephens Quarry, Wyoming, USA; in lateral (A), dorsal (B), and proximodorsal (C) views. Note the dorsal position of the overgrowth on the proximal articular surface, and how it fits in the notch in the distal articular surface of php I-1 (C, slightly displaced taphonomically). Abbreviations: mt, metatarsal; php, pedal phalanx. Not to scale, the proximodistal length of php I-1 is 45 mm.

olaterally oriented left element, the right one is shifted medially and plantarly. It is orientated dorsoplantarly, forming a large outgrowth on the upper part of the medial margin of the proximal side. At its dorsal end, it is incomplete. The surface texture of both left and right elements resembles that of sesamoids. Although only obvious in the first and third claw of the right pes of SMA 0002, the second ungual also shows incomplete surfaces that indicate the presence of similar bone overgrowth (Fig. 4). Histological thin sections of the right osteophyte show avascular bone and areas with coarse-grained textures (Fig. 5).

Overgrowth type 2.—Transverse extensions of the proximal articular surface edges mark both manual and pedal phalanges (Fig. 6; see SOM for a textured 3D model of the right phm III-1). They are generally very irregularly shaped and highly distinct. CT scans of manual phalanges show a generally lower bone density within the transverse spurs compared with adjacent bone (Fig. 6B). The spurs are sometimes accompanied by smoothed areas on proximal and distal articulation surfaces of the phalanges (Fig. 7).

Overgrowth type 3.—Only one occurrence of the third type of overgrowth is present in SMA 0002. It is a distally projecting spur at the distal articular surface of the left manual phalanx IV-1 (Fig. 8; see SOM for a textured 3D model). The spur is located at the centre of the surface. It has an oblique anterior side, whereas the posterior side forms a 90° angle with the distal surface of the phalanx. The anterior and posterior sides of the overgrowth meet distally in a thin crest. An oblique, stepped fracture extends from the lateral end of the distal spur dorsomedially to the upper third of the medial surface. The edges of the fracture are relatively smooth, there is no dislocation of the distomedial portion nor reactive bone growth around the fracture. A CT scan shows that this oblique fracture is internally recognisable by a line of denser bone extending throughout the entire dorsopalmar thickness of the phalanx (Fig. 8C).

Overgrowth type 4.—As type 3, the type 4 only occurs in a single bone of SMA 0002. It is a knob-like overgrowth on the laterodistal corner of the left pedal phalanx IV-1 (Fig. 9; see SOM for a textured 3D model). The overgrowth has a very round appearance, unlike the irregular morphology of the types above mentioned. The surface is relatively smooth. Given that the element is mounted, no CT scanning or histological sectioning was possible in this phalanx.

Deep pit.—The left pedal phalanx II-1 bears a deep pit in the proximal articular surface (Fig. 10; see SOM for a textured 3D model). The pit is located in the lateral half of the articular surface, which thus has a conical shape. The entire surface is equally rugose. No ridges or grooves extending towards the pit are present, and no surface smoothing is observable.

Discussion and diagnosis

Overgrowth type 1.—The first type of overgrowth is herein diagnosed as ossified tendon insertions, also called enthesophytes. Proximally projecting spurs have not been reported from other sauropod pedal unguals. However, observations (ET personal observations 2012) of the pedal claws of *Turiasaurus riodevensis* (CPT-1256, CPT-1257, CPT-1259) revealed similar extensions. The position of the spurs correlates with the insertion site for the retractor tendons of the claws in tetrapods (Haines 1939), indicating that the overgrowth represents the first reported case of enthesophytes in dinosaurs. Peripheral enthesophytes are known in lizards, rats, and humans (Benjamin et al. 2000; Suzuki et al. 2002), caused by an exposition to high strains (Schneider 1955; Rogers et al. 1997; Benjamin et al. 2000; Organ 2006; Shaw and Benjamin 2007) or representing a degradation after an injury or sudden and strong stretchings (Amprino 1948; Benjamin et al. 2000). They mostly occur in old individuals

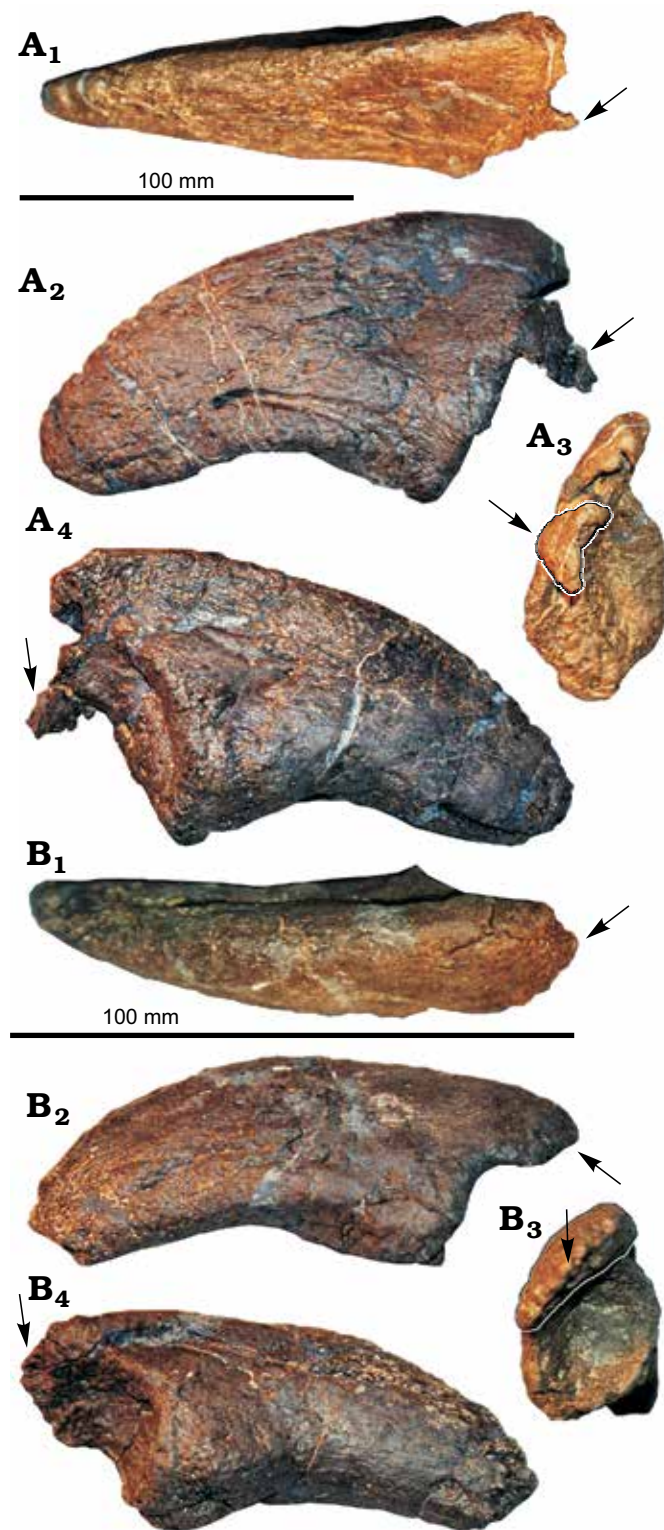


Fig. 3. Overgrowth type 1 (arrows) in right pedal unguals I (A) and III (B) of the camarasaurid sauropod SMA 0002 from Upper Jurassic Morrison Formation, Howe-Stephens Quarry, Wyoming, USA. Overgrowth projects proximally from the proximal articular surface. Note the medial to mediadorsal position of the overgrowths on the proximal articular surfaces. Unguals shown in dorsal (A₁, B₁), medial (A₂, B₂), proximal (A₃, B₃), and lateral (A₄, B₄) views. Photos taken by Esther Premru (Mönchaltorf, Switzerland) and modified from Tschopp et al. (2015).

(Amprino 1948; Knese and Biermann 1958) and are often associated with osteoarthritis in humans (Sokoloff 1963a; Jaffe 1972; Halstead 1974; Benjamin et al. 2000).

As is known for enthesophytes in rats and humans (Benjamin et al. 2000), the ones in SMA 0002 mark the inferior part of the retractor tendon. Additionally, bone histology of the type one overgrowth in SMA 0002 appears similar to that of ossified tendons (Broili 1922; Moodie 1928; Organ and Adams 2005): spongiosa is absent, areas with coarse-grained texture, areas with avascular bone, and regions with several generations of Haversian systems (Fig. 5). Finally, histological sections of the humerus, femur, scapula, and ribs of the specimen SMA 0002 revealed an advanced individual age (Klein and Sander 2008; Waskow and Sander 2014), which correlates with enthesophyte growth (Amprino 1948; Knese and Biermann 1958).

Overgrowth type 2.—The second type of overgrowth is interpreted here as a symptom of osteoarthritis. The formation of marginal, transversely projecting bony spurs and the grinding down and smoothing of articular surfaces, also called eburnation, are typical symptoms of osteoarthritis (Bunim 1956; Larson 1962; Sokoloff 1963b; Jaffe 1972; Halstead 1974; Rothschild and Tanke 1992; Rothschild and Martin 1993; Rothschild 1997), although eburnation actually represents the final common pathway of any severe arthritis and is not specific for osteoarthritis (Rothschild and Martin 2006).

So-called primary and secondary osteoarthritis exists. Primary osteoarthritis is a joint disease, in which the cartilage cover of the bone is damaged, and gradually thinning. It is most commonly known from senescent individuals (Larson 1962; Sokoloff 1963a; Halstead 1974), but the disease may also appear as a secondary phenomenon in both adults and juveniles (Schneider et al. 2005). Whereas the initial cause of primary osteoarthritis is still unknown (this type of disease normally develops spontaneously with old age), secondary osteoarthritis is often a consequence of another disease or a traumatic incident that affects the articular cartilage (Bunim 1956; Larson 1962; Sokoloff 1963a; Jaffe 1972).

Although several cases of osteoarthritis have been reported from the dinosaur fossil record (e.g., Johnson and Storer 1974; Rega and Brochu 2001), the term was often misapplied to vertebral osteophytes, where the exact technical term should be spondylosis deformans (Rothschild and Martin 2006). Actual appendicular joint osteophytes (identifier for osteoarthritis) are rare in dinosaurs (Rothschild and Martin 1993; Tanke and Rothschild 1997): only two confirmed cases have been published, both in specimens of the ornithomimid *Iguanodon* (Rothschild and Martin 1993; Tanke and Rothschild 1997). An unpublished case is present in the pes of the *Eobrontosaurus* specimen Tate-001, which appears to show arthritic overgrowth associated with a greenstick fracture in one of its phalanges (BMR personal observations). All these cases are interpreted as secondary osteoarthritis (Rothschild and Martin 1993; Tanke and Rothschild 1997; BMR personal observations).

In the specimen SMA 0002, transversely projecting osteophytes are present in the majority of both manual and pedal phalanges, resulting in considerably enlarged proximal articular surfaces compared to normal sauropod phalanges (Fig. 11). The common association of overgrowth type 2 with smoothed articular surfaces indicates that eburnation was present. Given that osteoarthritis mostly occurs in joints that are exposed to high loads (Bunim 1956; Jaffe 1972), the metapodial-phalangeal joints in the weight-bearing, semi-digitigrade pes and the unguligrade manus were likely to be affected in sauropods. Although the senescent age revealed by histology (Klein and Sander 2008; Waskow and Sander 2014) suggests the possibility of primary osteoarthritis, presence of other pathologies, with their gait-altering effect, makes the secondary variety of osteoarthritis more likely.

Overgrowth type 3.—The diagnosis for this distal overgrowth and the associated fracture is difficult. However, we propose this overgrowth to have developed as a consequence of altered stress-regimes. Tschopp (2010) proposed that this distal spur might represent an incomplete fusion of a terminal phalanx to its neighboring element, and took this as evidence that fusion of bones played a part in the reduction of manual phalanges during sauropod evolution. The neosauropod manus has a highly reduced number of phalanges; in some derived titanosauriforms, manual phalanges were even lost completely (Wilson 2002; Bonnan 2003). Vestigial, terminal elements are preserved in SMA 0002 in the second manual digits (Tschopp et al. 2015), and the transversely concave distal surface of phm III-1 indicates that a similar element was present as well in the third digit. The fact that phm IV-1 has a transversely straight anterodistal edge could be taken as an indication that such a vestigial element fused with the more proximal element, thereby filling in the concavity. However, the irregular surface is different from the smoother surface of the preserved left and right phm II-2. Also, if the overgrowth would be an incomplete fusion, one would expect to see at least slight indentations along the fusion line.

The association of the distal spur with the oblique fracture leads to additional questions: which pathology occurred first? Did one cause the other? The most evident diagnosis would be that the overgrowth represents reactive bone growth after the injury that caused the fracture. However, the restriction of the overgrowth to the distal end would then have to be explained by a differential timing of reactive bone growth along a fracture, similar to a post-fracture disproportionate growth of portions of the manus distal to the fracture in a specimen of *Acrocantosaurius* (BMR personal observations). Nonetheless, given that differential reactive bone growth appears to be very rare, other explanations might be more parsimonious.

The presence of the spur must have altered the distribution of stresses during impacts, possibly resulting in a higher probability of bone fracture. Even though reactive bone growth is lacking, the perfect alignment of the fractured and the main portion of the element, and the higher internal bone density observable in the CT scan, indicate




Fig. 4. Photo (A) and drawing (B) of the right pedal ungual II of the camarasaurid sauropod SMA 0002 (Upper Jurassic Morrison Formation, Howe-Stephens Quarry, Wyoming, USA) in proximal view, showing the broken surface indicating overgrowth attachment. Modified from Tschopp et al. (2015).

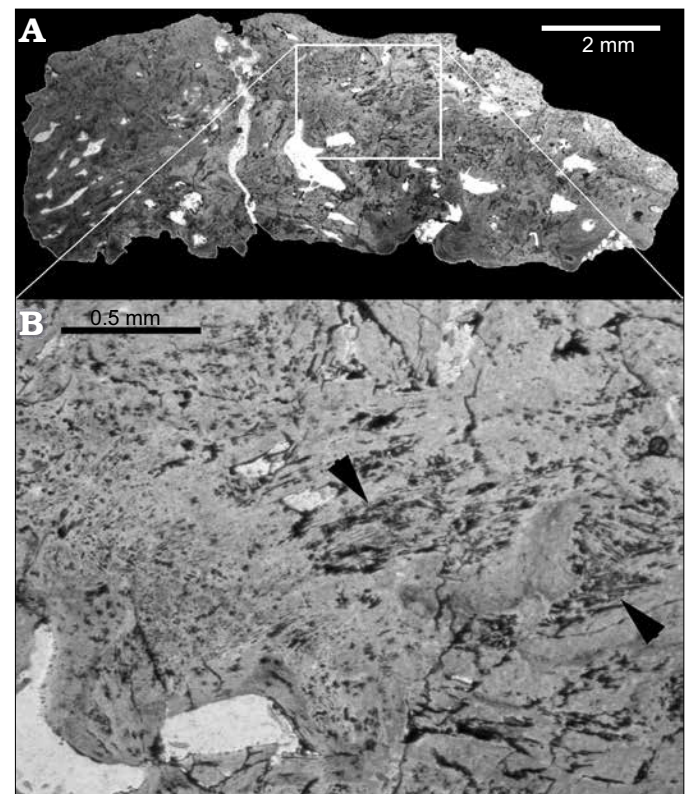


Fig. 5. Thin section of the overgrowth type 1 from the right pedal ungual I of the camarasaurid sauropod SMA 0002 from Upper Jurassic Morrison Formation, Howe-Stephens Quarry, Wyoming, USA (A). Detail (B), showing coarse-grained structure bone in mainly avascular bone (arrowheads).

that the fracture happened during life, and that bone remodelling has started internally. The absence of external reactive bone growth potentially indicates that the incident happened shortly before the death of the animal. Taken all this together, it is thus most probable that the formation of the distal spur preceded and even potentially caused the

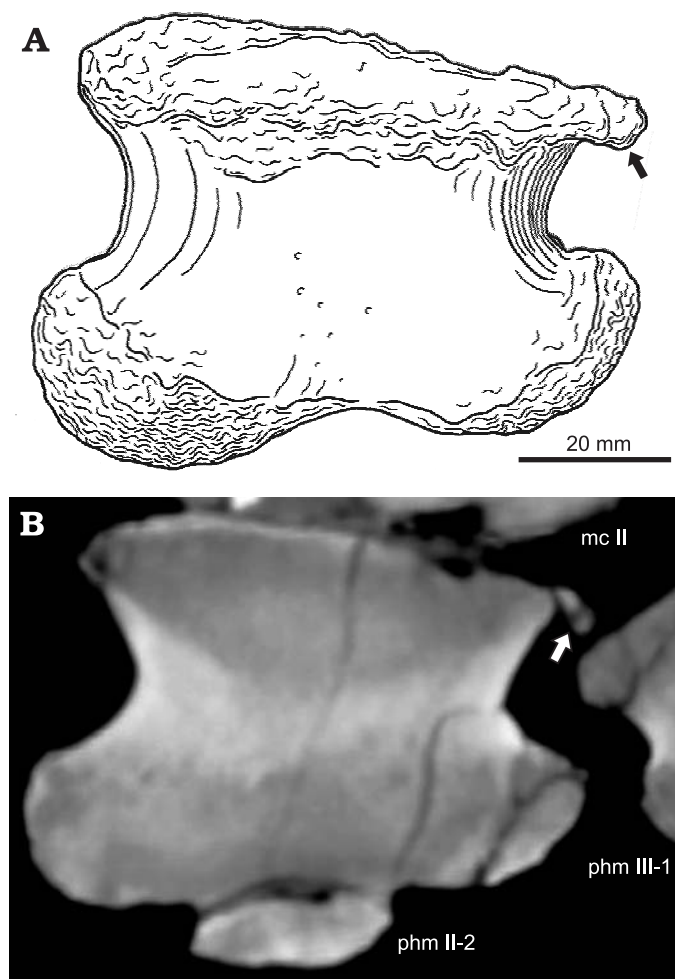


Fig. 6. Overgrowth type 2 exemplified in a drawing (A, modified from Tschopp et al. 2015) and CT scan (B) of the left manual phalanx II-1 of the camarasaurid sauropod SMA 0002 from Upper Jurassic Morrison Formation, Howe-Stephens Quarry, Wyoming, USA. CT scan shows variable bone densities in the osteophyte, indicated by the different gray scales. Abbreviations: phm, phalanx of manual digit; mc, metacarpal.

fracture. The formation of the distal spur could have been indirectly caused by the other pathologies in the manus, which changed the gait such that the altered stress-regimes on the phalanx resulted in additional bone growth.

A similar case of distal overgrowth is present in the left manual phalanx IV of *Turiasaurus riodevensis* CPT-1207 (ET personal observations 2012). The overgrowth appears slightly more detached from the distal surface than in SMA 0002, which indicates that in the case of *T. riodevensis*, incomplete fusion cannot be ruled out completely. No CT scans were available from this specimen to check for signs of trauma as a cause for the overgrowth.

Overgrowth type 4.—The last type of overgrowth is here diagnosed as a bone tumour. The smooth surface and the position of overgrowth type 4 at the laterodistal corner indicate a non-arthritic cause. The singular occurrence and the regular shape imply that it represents a bone tumour. Plausible diagnoses are an osteoma or an osteoblastoma, both of them representing benign bone-forming lesions (Greenspan 1993).

These two forms of bone tumours are very similar and can, in humans, externally only be tentatively distinguished by their size: osteomas are generally smaller than 1.5 cm in diameter, whereas osteoblastomas are larger (Byers 1968; Kitsoulis et al. 2006; Atesok et al. 2011). However, it remains unclear if the same size constraints applied as well to the gigantic sauropods. The size of the knob described herein is approximately 1.5 cm, which falls into the size range of both tumours, although being at the lower end for osteoblastomas (Byers 1968; Atesok et al. 2011). In humans, osteoblastomas are preferentially found in the vertebral column, and osteomas in long bones, but both also occur in the feet (Kitsoulis et al. 2006; Atesok et al. 2011). Osteomas occur mostly in juvenile to young adults (Kitsoulis et al. 2006; Atesok et al. 2011), whereas SMA 0002 was confidently identified as a very old individual, based on long bone and dorsal rib histology (Klein and Sander 2008; Waskow and Sander 2014).

Both osteomas and osteoblastomas were already reported in dinosaurs (Rothschild et al. 2003; Capasso 2005; Rega 2012), but without CT scans, a more detailed diagnosis of overgrowth type 4 is impossible.

Deep pit.—The deep pit marking the proximal articular surface of the left pedal phalanx II-1 is interpreted as a sign of osteochondrosis, or osteochondritis. During normal bone growth, articular cartilage is replaced by bone. When this replacement does not take place, an osseous defect (osteochondrosis) results. The non-transformed cartilage is referred to as a “cartilage rest”. This is recognised in defleshed (e.g., fossil) subchondral bone as a smooth pit of relatively uniform depth, variable breadth and with smooth graded borders. Cases of osteochondrosis were reported from a hadrosaurid dinosaur (Rothschild and Tanke 2007).

Osteochondritis (avascular necrosis) is recognised by sharp borders, typically with subsidence of the internal portion. Whereas osteochondritis has been considered eti-




Fig. 7. Smoothened area (a possible case of eburnation) on the distal articular surface of the left manual phalanx I-1 of the camarasaurid sauropod SMA 0002 from Upper Jurassic Morrison Formation, Howe-Stephens Quarry, Wyoming, USA. The distal dorsopalmar height is 55 mm.

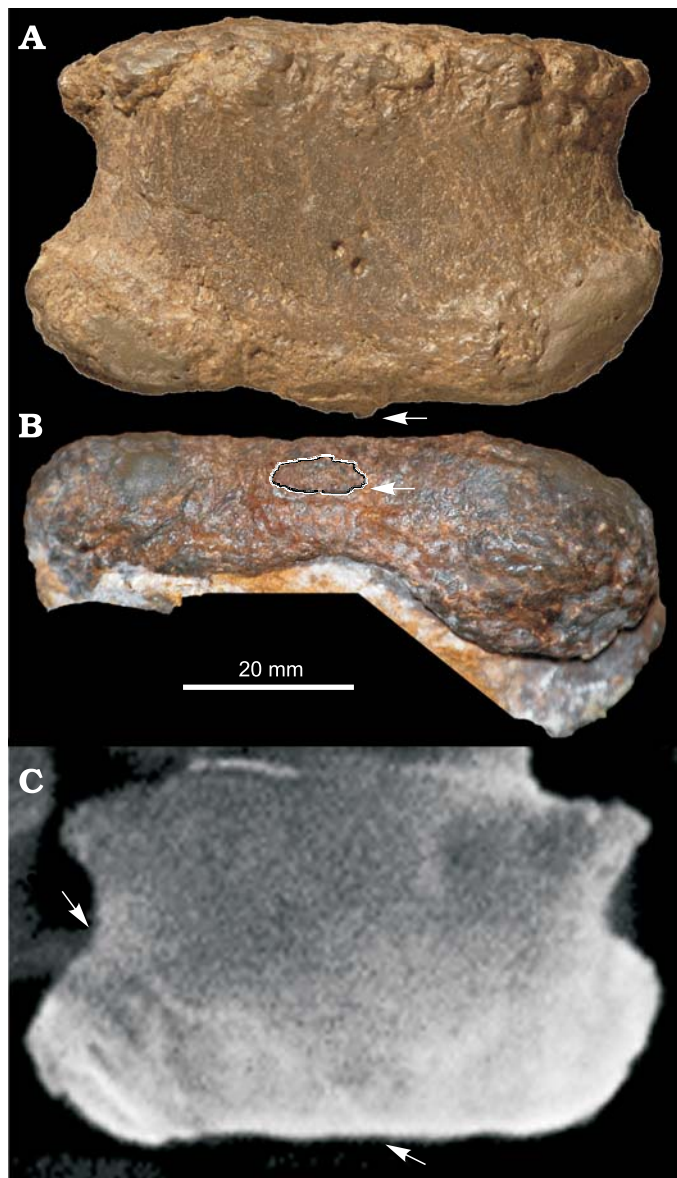


Fig. 8. Overgrowth type 3 (arrows in A, B) on the distal articular surface of the left manual phalanx IV-1 of the camarasaurid sauropod SMA 0002 from Upper Jurassic Morrison Formation, Howe-Stephens Quarry, Wyoming, USA; in anterior/dorsal (A) and distal (B) views, and CT scan of frontal slice (C), note the probable healed fracture (arrows). Photos taken by Rosemarie Roth (University of Zurich, Switzerland).

ologic in the past (Aglietti et al. 1983), it is now generally considered to represent a fracture of the subchondral bone (Rothschild and Martin 2006). The relatively smooth borders of the deep pit therefore rather indicate osteochondrosis as a cause, but CT scans or histological sections of the phalanx would have to be produced in order to check for subluxation before a definitive diagnosis can be made.

Implications on behaviour

Enthesophytes (ossification of tendons, ligaments, or joint capsules) are often interpreted to occur more commonly




Fig. 9. Overgrowth type 4 (arrow) on the laterodistal corner of the left pedal phalanx IV-1 of the camarasaurid sauropod SMA 0002 from Upper Jurassic Morrison Formation, Howe-Stephens Quarry, Wyoming, USA; in anterior/dorsal view. Abbreviation: php, phalanx of pedal digit.




Fig. 10. Deep pit (arrow) in the proximal articular surface of the left pedal phalanx II-1 of the camarasaurid sauropod SMA 0002 from Upper Jurassic Morrison Formation, Howe-Stephens Quarry, Wyoming, USA; in antero-proximal view. The proximal width of the phalanx is 72 mm. Abbreviation: mt, metatarsal.

in joints that are in heavy use or have to bear high loads (Schneider 1955; Rogers et al. 1997; Benjamin et al. 2000; Claudepierre and Voisin 2005). The presence of such structures in the pes of SMA 0002 might therefore shed a light on the function of the unguals in camarasaurid sauropods. Since such a condition is exceptionally rare in sauropods, it




Fig. 11. Comparison of the normal development of articular surfaces of phalanges of diplodocid sauropod SMA 0087 (php II-1, **A**) with the pathological elements of camarasaurid sauropod SMA 0002 (php III-1, **B**); both from the Upper Jurassic Morrison Formation, Howe Ranch, Wyoming, USA. Note the considerable extension of the lateral spurs in SMA 0002.

is not plausible that a sole use as traction device (the main function of the pedal unguals proposed for all sauropods) can account as a cause for ossified tendons insertions. The ideas of Gallup (1989) and Upchurch et al. (2004) that the claws were also used for excavating nests or digging for food or water therefore seem to be more feasible. Scratch-digging was also inferred as reasonable behaviour of sauropods based on a comparison of ungual orientation and nesting trace morphology between sauropods and tortoises (Fowler and Hall 2013). Both of these taxa are known to bury their eggs (Vila et al. 2010a, b; Fowler and Hall 2013; Sander 2013), although probably at different depths (Seymour 1979; Werner and Griebeler 2013). The presence of enthesophytes indicates an additional function to traction device of the

pedal unguals in at least the sauropods *Camarasaurus* and *Turiasaurus*. Further pes skeletons of sauropod individuals with a histologically derived age should be investigated for existing enthesophytes.

Conclusion

The pathologies observed in a camarasaurid sauropod represent a rare case of various types of bone overgrowth and other symptoms in a single sauropod individual. They illustrate a large spectrum of bone reaction to trauma and degeneration, possibly in parts related to the advanced age of the individual, which favoured the accumulation of different pathologies in a single specimen. A specific type of pathological overgrowth, spurs above the proximal articular facet, are interpreted as enthesophytes, which were formed after prolonged heavy use during life. This finding provides additional support for the hypothesis that at least certain sauropods used their hindfeet for scratch-digging.

Acknowledgements

This contribution was originally a part of ET's Master thesis, and he wishes to thank his supervisor Winand Brinkmann (University of Zurich, Switzerland) for guidance and support. Many thanks go to Hans-Jakob Siber (SMA) for access to this valuable specimen, and Esther Premru, Ben Pabst (both SMA), and Barbara Bichsel-von Arb (University Hospital of Zurich, Switzerland) for its preparation. Hatem Alkadhi (University Hospital of Zurich, Switzerland) organized the medical CT scanning. Olaf Dülfer, with kind support from Martin Sander (both University of Bonn, Germany), produced the thin sections of the enthesophytes. Rosemarie Roth (University of Zurich, Switzerland) assisted with specimen photography. Rafael Royo-Torres and Eduardo Espilez (both CPT) provided access to *Turiasaurus* material, and shared pictures. We thank Torsten Scheyer (University of Zurich, Switzerland) and Emilie Läng (Muséum national d'Histoire naturelle, Paris, France) for valuable discussion on histology and phalangeal pathologies, and Jay Nair (University of Queensland, St Lucia, Australia), Paul Koning (Rijnstate Hospital, Arnhem, The Netherlands), and Joseph van Buskirk (University of Zurich, Switzerland) for comments on an early version of the manuscript, and corrections concerning the English. Joseph Peterson (University of Wisconsin, Oshkosh, USA), and an anonymous reviewer provided additional helpful comments. Financial support to ET and OW was provided by the "Europasaurus-Project", funded by the Volkswagen Foundation.

References

- Aglietti, P., Insall, J.N., Buzzi, R., and Deschamps, G. 1983. Idiopathic osteonecrosis of the knee. Aetiology, prognosis and treatment. *Journal of Bone and Joint Surgery, British Volume* 65-B: 588–597.
- Amprino, R. 1948. A contribution to the functional meaning of the substitution of primary by secondary bone tissue. *Cells Tissues Organs* 5: 291–300.
- Atesok, K.I., Alman, B.A., Schemitsch, E.H., Peyser, A., and Mankin, H. 2011. Osteoid osteoma and osteoblastoma. *Journal of the American Academy of Orthopaedic Surgeons* 19: 678–689.

- Ayer, J. 2000. *The Howe Ranch Dinosaurs*. 96 pp. Sauriermuseum Aathal, Switzerland.
- Benjamin, M., Rufai, A., and Ralphs, J.R. 2000. The mechanism of formation of bony spurs (enthesophytes) in the Achilles tendon. *Arthritis and Rheumatism* 43: 576–583.
- Bonnan, M.F. 2003. The evolution of manus shape in sauropod dinosaurs: implications for functional morphology, forelimb orientation, and phylogeny. *Journal of Vertebrate Paleontology* 23: 595–613.
- Broili, F. 1922. Über den feineren Bau der „Verknöcherten Sehnen“ (= Verknöcherten Muskeln) von *Trachodon*. *Anatomischer Anzeiger* 55: 465–475.
- Bunim, J.J. 1956. Arthritis in the elderly patient (osteoarthritis). *Bulletin of the New York Academy of Medicine* 32: 102–115.
- Byers, P.D. 1968. Solitary benign osteoblastic lesions of bone. Osteoid osteoma and benign osteoblastoma. *Cancer* 22: 43–57.
- Capasso, L.L. 2005. Antiquity of cancer. *International Journal of Cancer* 113: 2–13.
- Claudepierre, P. and Voisin, M.-C. 2005. The entheses: histology, pathology, and pathophysiology. *Joint Bone Spine* 72: 32–37.
- Farke, A.A., Wolff, E.D.S., and Tanke, D.H. 2009. Evidence of combat in *Triceratops*. *PLoS ONE* 4: e4252.
- Farlow, J.O. and Dodson, P. 1975. The behavioral significance of frill and horn morphology in ceratopsian dinosaurs. *Evolution* 29: 353.
- Foth, C., Evers, S.W., Pabst, B., Mateus, O., Flisch, A., Patthey, M., and Rauhut, O.W.M. 2015. New insights into the lifestyle of *Allosaurus* (Dinosauria: Theropoda) based on another specimen with multiple pathologies. *PeerJ* 3: e940.
- Fowler, D.W. and Hall, L.E. 2011. Scratch-digging sauropods, revisited. *Historical Biology* 23: 27–40.
- Gallup, M.R. 1989. Functional morphology of the hindfoot of the Texas sauropod *Pleurocoelus* sp. indet. Paleobiology of the Dinosaurs. *Geological Society of America Special Paper* 238: 71–74.
- Greenspan, A. 1993. Benign bone-forming lesions: osteoma, osteoid osteoma, and osteoblastoma. *Skeletal Radiology* 22: 485–500.
- Haines, R.W. 1939. A revision of the extensor muscles of the forearm in tetrapods. *Journal of Anatomy* 73: 211–233.
- Halstead, L.B. 1974. *Vertebrate Hard Tissues*. 179 pp. Wykeham, London.
- Jaffe, H.L. 1972. *Metabolic, Degenerative, and Inflammatory Diseases of Bones and Joints*. 1101 pp. Lea and Febiger, Philadelphia.
- Johnson, H. and Storer, J.E. 1974. *A Guide to Alberta Vertebrate Fossils from the Age of Dinosaurs*. 129 pp. Provincial Museum of Alberta, Edmonton.
- Kitsoulis, P., Mantellos, G., and Vlychou, M. 2006. Osteoid osteoma. *Acta Orthopædica Belgica* 72: 119–125.
- Klein, N. and Sander, P.M. 2008. Ontogenetic stages in the long bone histology of sauropod dinosaurs. *Paleobiology* 34: 247–263.
- Knese, K.-H. and Biermann, H. 1958. Die Knochenbildung an Sehnen- und Bandansätzen im Bereich ursprünglich chondraler Apophysen. *Zeitschrift für Zellforschung und Mikroskopische Anatomie* 49: 142–187.
- Larson, C.B. 1962. The wearing-out of joints. *Journal of the American Geriatrics Society* 10: 558–566.
- Lovelace, D.M. 2014. Developmental failure of segmentation in a caudal vertebra of *Apatosaurus* (Sauropoda). *The Anatomical Record* 297: 1262–1269.
- Mallison, H. and Wings, O. 2014. Photogrammetry in paleontology—a practical guide. *Journal of Paleontological Techniques* 12: 1–31.
- Mateus, O. and Tschopp, E. 2013. *Cathetosaurus* as a valid sauropod genus and comparisons with *Camarasaurus*. In: E. Maxwell, J. Miller-Camp, and R. Anemone (eds.), *SVP 73rd Annual Meeting, Program and Abstracts. Supplement to the online Journal of Vertebrate Paleontology* October 2013: 173.
- Moodie, R.L. 1928. The histological nature of ossified tendons found in dinosaurs. *American Museum Novitates* 311: 1–15.
- Organ, C.L. 2006. Thoracic epaxial muscles in living archosaurs and ornithomimid dinosaurs. *The Anatomical Record Part A: Discoveries in Molecular, Cellular, and Evolutionary Biology* 288A: 782–793.
- Organ, C.L. and Adams, J. 2005. The histology of ossified tendon in dinosaurs. *Journal of Vertebrate Paleontology* 25: 602–613.
- Rega, E. 2012. Disease in dinosaurs. In: M.K. Brett-Surman, T.R.J. Holtz, and J.O. Farlow (eds.), *The Complete Dinosaur*, Second Edition, 667–711. Indiana University Press, Bloomington.
- Rega, E.A. and Brochu, C.A. 2001. Paleopathology of a mature *Tyrannosaurus rex* skeleton. *Journal of Vertebrate Paleontology* 21: 92A.
- Rega, E., Holmes, R.B., and Tirabasso, A. 2010. Habitual locomotor behavior inferred from manual pathology in two Late Cretaceous chasmosaurine ceratopsid dinosaurs, *Chasmosaurus irvinensis* (CMN 41357) and *Chasmosaurus belli* (ROM 843). In: M.J. Ryan, B.J. Chinnery-Allgeier, and D.A. Eberth (eds.), *New Perspectives on Horned Dinosaurs*, 340–354. Indiana University Press, Bloomington.
- Rogers, J., Shepstone, L., and Dieppe, P. 1997. Bone formers: osteophyte and enthesophyte formation are positively associated. *Annals of the Rheumatic Diseases* 56: 85–90.
- Rothschild, B.M. 1997. Dinosaurian paleopathology. In: J.O. Farlow and M.K. Brett-Surman (eds.), *The Complete Dinosaur*, 426–448. Indiana University Press, Bloomington.
- Rothschild, B.M. and Martin, L.D. 1993. *Paleopathology: Disease in the Fossil Record*. 386 pp. CRC Press, London.
- Rothschild, B.M. and Martin, L.D. 2006. Skeletal impact of disease. *New Mexico Museum of Natural History and Science Bulletin* 33: 1–226.
- Rothschild, B.M. and Molnar, R.E. 2005. Sauropod stress fractures as clues to activity. In: V. Tidwell and K. Carpenter (eds.), *Thunder-lizards: the Sauropodomorph Dinosaurs*, 381–392. Indiana University Press, Bloomington.
- Rothschild, B.M. and Tanke, D.H. 1992. Paleocene 13. Paleopathology of vertebrates: insights to lifestyle and health in the geological record. *Geoscience Canada* 19: 73–82.
- Rothschild, B.M. and Tanke, D.H. 2007. Osteochondrosis in Late Cretaceous Hadrosauria: a manifestation of ontologic failure. In: K. Carpenter (ed.), *Horns and Beaks: Ceratopsian and Ornithomimid Dinosaurs*, 171–183. Indiana University Press, Bloomington.
- Rothschild, B.M., Tanke, D.H., Helbling, M., and Martin, L.D. 2003. Epidemiologic study of tumors in dinosaurs. *Naturwissenschaften* 90: 495–500.
- Sander, P.M. 2013. An evolutionary cascade model for sauropod dinosaur gigantism—overview, update, and tests. *PLoS ONE* 8: e78573.
- Schneider, D.S., Schmitt, G., Mau, H., Schmitt, H., Sabo, D., and Richter, W. 2005. Prävalenz und Korrelate der Osteoarthritis in der BRD. *Der Orthopäde* 34: 782–790.
- Schneider, H. 1955. Die Struktur der Sehnenansatzzone und Abnutzungserkrankungen in ihrem Bereich. *Münchener Medizinische Wochenschrift* 97: 1479–1480.
- Seymour, R.S. 1979. Dinosaur eggs; gas conductance through the shell, water loss during incubation and clutch size. *Paleobiology* 5: 1–11.
- Shaw, H.M. and Benjamin, M. 2007. Structure–function relationships of entheses in relation to mechanical load and exercise. *Scandinavian Journal of Medicine and Science in Sports* 17: 303–315.
- Sokoloff, L. 1963a. Degenerative joint disease in birds. Laboratory investigation. *Journal of Technical Methods and Pathology* 12: 531–537.
- Sokoloff, L. 1963b. The biology of degenerative joint disease. *Perspectives in Biology and Medicine* 7: 94–106.
- Suzuki, D., Murakami, G., and Minoura, N. 2002. Histology of the bone-tendon interfaces of limb muscles in lizards. *Annals of Anatomy* 184: 363–377.
- Tanke, D.H. and Currie, P.J. 1998. Head-biting behavior in theropod dinosaurs: paleopathological evidence. *Gaia* 15: 167–184.
- Tanke, D.H. and Rothschild, B.M. 1997. Paleopathology. In: P.J. Currie and K. Padian (eds.), *Encyclopedia of Dinosaurs*, 525–530. Academic Press, San Diego.
- Tanke, D.H. and Rothschild, B.M. 2010. Paleopathologies in Albertan ceratopsids and their behavioral significance. In: M.J. Ryan, B.J. Chinnery-Allgeier, and D.A. Eberth (eds.), *New Perspectives on Horned Dinosaurs*, 355–384. Indiana University Press, Bloomington.
- Tschopp, E. 2010. Bony overgrowth in phalanges of a *Camarasaurus* (Di-

- nosauria: Sauropoda) indicates old ontogenetic age and provides insights into the process of phalangeal reduction in sauropods. *Journal of Vertebrate Paleontology* 30 (Supplement 3): 177A.
- Tschopp, E., Wings, O., Frauenfelder, T., and Brinkmann, W. 2015. Articulated bone sets of manus and pedes of *Camarasaurus* (Sauropoda, Dinosauria). *Palaeontologia Electronica* 18: 1–65.
- Upchurch, P., Barrett, P.M., and Dodson, P. 2004. Sauropoda. In: D.B. Weishampel, P. Dodson, and H. Osmólska (eds.), *The Dinosauria*, Second edition, 259–322. University of California Press, Berkeley.
- Vila, B., Galobart, À., Oms, O., Poza, B., and Bravo, A.M. 2010a. Assessing the nesting strategies of Late Cretaceous titanosaurs: 3-D clutch geometry from a new megaloolithid egg site. *Lethaia* 43: 197–208.
- Vila, B., Jackson, F.D., Fortuny, J., Sellés, A.G., and Galobart, À. 2010b. 3-D modelling of megaloolithid clutches: insights about nest construction and dinosaur behaviour. *PLoS ONE* 5: e10362.
- Waskow, K. and Sander, P.M. 2014. Growth record and histological variation in the dorsal ribs of *Camarasaurus* sp. (Sauropoda). *Journal of Vertebrate Paleontology* 34: 852–869.
- Werner, J. and Griebeler, E.M. 2013. New insights into non-avian dinosaur reproduction and their evolutionary and ecological implications: linking fossil evidence to allometries of extant close relatives. *PLoS ONE* 8: e72862.
- Wilson, J.A. 2002. Sauropod dinosaur phylogeny: critique and cladistic analysis. *Zoological Journal of the Linnean Society* 136: 215–275.