

DOI 10.2478/pjvs-2014-0035

Original article

Usefulness of the assessment of discharge accumulation in the lower airways and tracheal septum thickening in the differential diagnosis of recurrent airway obstruction (RAO) and inflammatory airway disease (IAD) in the horse

B. Wysocka, W. Kluciński

Department of Pathology and Veterinary Diagnostics, Faculty of Veterinary Medicine,
Warsaw University of Life Sciences, Nowoursynowska 159C, 02-776, Warsaw, Poland

Abstract

The aim of the present study was to use endoscopic evaluation to compare the grade of accumulation of discharge in the lower airways of horses with recurrent airway obstruction (RAO) and inflammatory airway disease (IAD), and to estimate the usefulness of endoscopic evaluation in differential diagnosis of these diseases. Endoscopic evaluation consists of: the amount of discharge in the lower part of the trachea and tracheal bifurcation, and the assessment of tracheal septum thickness.

This study was performed on 248 horses, 10 were healthy, 97 were diagnosed as RAO, and 141 were diagnosed as IAD. In all animals both a clinical and endoscopic examination were performed. During endoscopy, a score of mucus accumulation was estimated in 3/4 lower of the trachea and in the tracheal bifurcation. In addition to this, thickening of the tracheal septum was also assessed. According to the results of this study, it was estimated that the accumulation of mucus in the lower airways was much more advanced in RAO horses compared to horses with IAD. In horses with RAO there was a marked thickening of the tracheal septum compared to IAD horses.

The results indicate the efficacy of scoring the amount of mucus in the tracheal lumen and tracheal bifurcation, as well as the efficacy of the assessment of tracheal septum thickness in the diagnosis of these diseases.

Key words: horses, endoscopy of lower airways, RAO, IAD, mucus, tracheal septum thickening

Introduction

Chronic noninfectious diseases of the lower respiratory tract in the horse are one of the biggest problems in modern veterinary medicine, particularly in the central European climate zone. These diseases are the cause of significant losses in equine sports and racing. Today, the prevalence of recurrent airway obstruction (RAO) and inflammatory airway disease (IAD) is one of the most significant causes of economic loss in the equine sports industry.

Recurrent airway obstruction is one of the oldest known equine diseases but its pathogenesis and aetiology are still not recognised. This disease is also defined as chronic allergic bronchitis. Clinical signs are: cough, nasal discharge, exercise intolerance, mixed dyspnea with predominance of expiratory effort (Kluciński and Olszewski 1993). If left untreated, this disease leads to permanent inflammatory changes and remodelling of the bronchi. As a consequence of chronic dyspnea, pulmonary emphysema develops.

Characteristic environmental factors for this condition are exposure to organic dust from hay and straw, thus causing bronchitis and dyspnea. This disease is diagnosed in animals over six years old and there is no breed or sex predilection. There is significant evidence (Gerber et al. 2009) that RAO is inherited. After manifestation of the first clinical signs of respiratory distress, the affected animal will be sick for the rest of its life.

A few years ago, IAD was described as inflammation of the lower airways in young horses aged under 5 years (mostly race horses) with mixed aetiology. This disease lasted no longer than 6 months.

Nowadays, according to the consensus of 2007, (Couëtil et al. 2007) IAD is a non-infectious, chronic disease of the lower airways characterised by poor performance and cough (with or without accumulation of mucus in airways) without symptoms of dyspnea. This disease can affect horses at any age, and similarly to RAO, there are no sex or breed predilections. To this day, the aetiology is not known, but infectious agents and allergens are not excluded (Laus et al. 2009). To diagnose IAD, broncho-alveolar lavage should be performed, where three different cytological patterns are described.

Since we are still lacking a simple definition differentiating between these two disease entities, it is necessary to use obtained results in order to create a gold standard that will assist in the differential diagnosis of these diseases (Cardwell et al. 2011).

The aim of this study was to use endoscopy to compare the grade of accumulation of mucus in the lower airways in horses with RAO and IAD, and to

estimate the usefulness of this procedure in the differential diagnosis of these diseases through the assessment of the amount of mucus in the lower part of the trachea, and the assessment of the thickening of the tracheal septum.

Materials and Methods

This study was conducted on 248 horses of different breeds and sex, aged between 4-23 years, and used in sports, racing or as pleasure horses. All animals were examined clinically and endoscopically. A detailed history was collected from all owners, trainers and riders. Division of these horses into three groups was made on the basis of history and clinical examination and was confirmed by cytological and microbiological examination. Horses in the control group had no history of respiratory disease and no clinical signs of respiratory disease. The main criteria in this division of horses with RAO or IAD was the presence or absence, in either clinical history or in clinical examination, of respiratory distress at rest. Horses with signs of dyspnea were classified into the RAO group, and horses lacking history and symptoms of respiratory distress at rest, but with other clinical signs such as, cough, poor performance or nasal discharge were classified into the IAD group.

Clinical examination included the description of the animal, measure of rectal temperature, examination of mucus membranes, palpation of superficial lymph nodes, and heart auscultation. In the detailed clinical exam, attention was paid mostly to the examination of the respiratory tract, including palpation of the larynx and trachea, auscultation of the trachea and both lung fields, respiratory rate, presence or absence of dyspnea and type of dyspnea, presence of cough, and presence of nasal discharge.

The first group had 10 horses, which were clinically healthy and without any signs of respiratory disease. Collected blood results were within reference ranges.

The second group consisted of 97 horses, and in these animals, based on clinical examination and endoscopy with cytological and microbiological examination of tracheal washes and broncho-alveolar lavage fluid, recurrent airway obstruction (RAO) was diagnosed. Horses were admitted due to chronic cough and dyspnea. During the collection of clinical history information, special attention was paid to signs typical for respiratory distress in RAO, including environment-dependent deterioration, and seasonal episodes of respiratory distress. Most of the horses had signs of dyspnea with expiratory effort and, in auscultation,

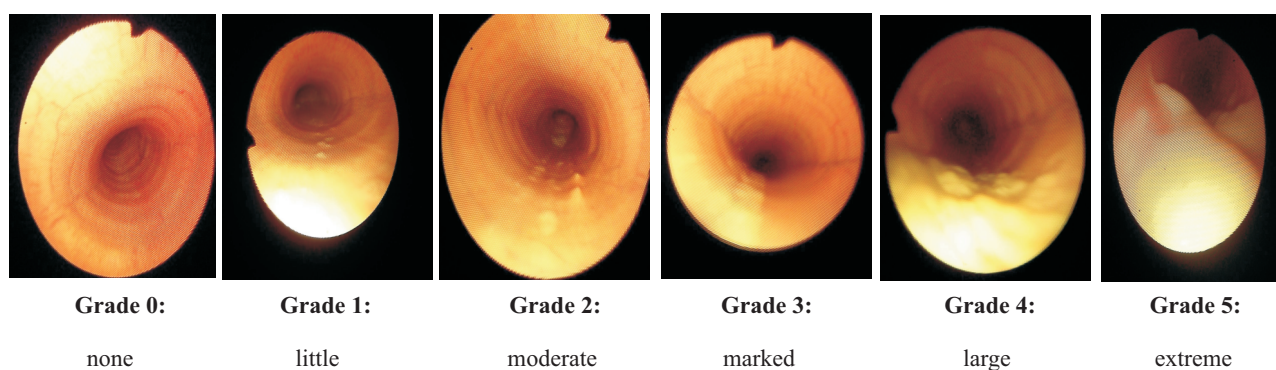


Fig. 1. Endoscopic assessment of discharge in tracheal lumen according to the six grade scale (Allen and Franklin 2007, Bartner et al. 2006).

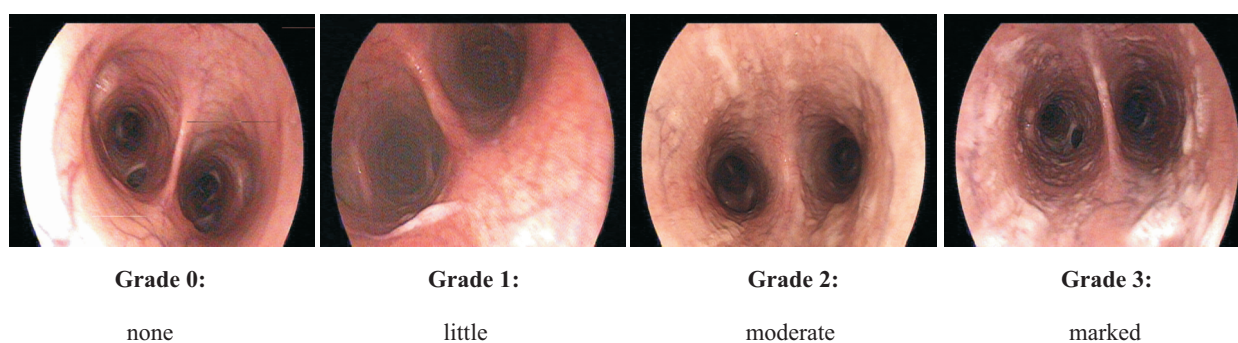


Fig. 2. Endoscopic assessment of discharge in the area of tracheal bifurcation according to the fourth grade scale by Wysocka.

crackles and wheezes were noted. Body temperature was normal.

The third group contained 141 animals. These horses, based on clinical and endoscopic exam with cytological and microbiological exam of tracheal washes and bronchoalveolar lavage fluid, were diagnosed with inflammatory airways disease (IAD). Horses were admitted due to cough, nasal discharge and poor performance. Often, these horses were clinically asymptomatic, but many showed a prolonged expiratory phase, and harsh lung sounds. Body temperature was normal.

Endoscopic exam

Endoscopic exam was performed by using a 1.7 m long Fujinon Col mp2 endoscope with a 1 cm external diameter. Pictures required for assessment of airways were taken with a digital camera adjusted to the endoscope. Before use of the endoscope, animals were sedated with xylazine 0.3-0.5 mg b.w., i.v. and butorphanol 0.01 – 0.03 mg/kg b.w., i.v.

During the endoscopic procedure, special attention was paid to assessing:

- accumulation of discharge in 3/4 of lower of the trachea. Evaluation was performed using 6th grade

scale (Allen and Franklin 2007, Bartner et al 2006) for visually determining the amount of secretion (Fig. 1),

- accumulation of discharge in the area of tracheal bifurcation and main bronchi. Evaluation was performed using 4 grade scale by Wysocka for visually determining the amount of secretion in this area (Fig. 2),

- the ratio of the horizontal diameter of the right main bronchus to the thickness of tracheal the septum at mid-height was calculated. Both measurements (in millimeters) were obtained from digital picture and analysed by computer using the GIMP ink 2.6 program. The obtained ratio was the indicator for tracheal septum thickness.

The next stage of the procedure was collection of tracheal aspirates and bronchoalveolar lavage fluid in accordance with generally accepted principles (Derksen et al. 1989, Kluciński et al. 1994, Beech 1975). Tracheal washes were submitted for cytological and microbiological analysis. Bronchoalveolar lavage fluid was analysed cytologically to diagnose RAO and IAD (Kluciński et al. 1994).

Statistical analysis

Results were analysed statistically with student test, with assigned statistical significance $p = 0.05$.

Table 1. Assessment of accumulation of muco-purulent discharge in the six grade scale in control horses and sick horses with diagnosed RAO and IAD.

Groups of horses	Number of horses (N)	Number (n) and percentage (%) of horses included in different grades in 6 grade scale											
		0		1		2		3		4		5	
		n	%	n	%	n	%	n	%	n	%	n	%
Control	10	10	100.0	0	0	0	0	0	0	0	0	0	0
With diagnosed RAO	97	1	1.0	9	9.3	32	33.0	30 ^b	30.9 ^b	20	20.6	5	5.2
With diagnosed IAD	141	30	21.3 ^a	39	27.7 ^a	46	32.6	23	16.3 ^a	3	2.1 ^a	0	0.0 ^a

Commentary:

^a – differences statistically relevant $p < 0.05$ compared to RAO horses

^b – differences statistically relevant ($p < 0.05$) compared to other grades in 6 th grade scale

Results

In control horses (group 1), all clinical parameters were within normal limits. Mean rectal temperature was $37.7 \pm 0.5^\circ\text{C}$, mean number of breaths was 12 ± 3.0 breaths/minute, and mean heart rate was 34 ± 8 beats/minute. In this group, horses showed no signs of cough, dyspnea, nasal discharge, or enlargement of superficial lymph nodes.

During endoscopy, there were no abnormal findings in upper or lower airways. In the cytological examination of bronchoalveolar lavage, the results showed $9.2 \pm 2.8\%$ of neutrophils, $64.1 \pm 9.1\%$ of macrophages, $21.9 \pm 4.2\%$ of lymphocytes, and $4.8 \pm 1.1\%$ of epithelial cells. In this group, there were no positive results for pathogenic bacteria in tracheal washes.

In group number two, with diagnosed recurrent airway obstruction (RAO), we included horses with symptoms such as cough, presence of mixed dyspnea (predominantly expiratory), prolonged expiratory phase with formation of a “heave line”, abnormal lung sounds including crackles and wheezes, exercise intolerance, and nasal discharge. In these horses mean body temperature was $37.2 \pm 0.5^\circ\text{C}$ and was thus within normal limits. In the cytology of the bronchoalveolar lavage fluid there were $72.54 \pm 2.58\%$ neutrophils, $0.65 \pm 0.79\%$ eosinophils, and $17.18 \pm 2.01\%$ macrophages. The remaining percentage of cells consisted of lymphocytes and epithelial cells. There was no presence of pathogenic bacteria in tracheal washes.

The largest number of horses were categorized into group three and diagnosed with inflammatory airway disease (IAD). These horses were aged from 4 to 21 years. The clinical exam revealed a mean body temperature of $37.5 \pm 0.7^\circ\text{C}$ and, thus, it was thus within normal limits. In these horses, the most

common clinical findings were: increased lung sounds, cough, and nasal discharge. Tracheal washes contained an elevated neutrophil count, but less elevated than in horses with RAO. In bronchoalveolar lavage, a percentage of $41.0 \pm 2.1\%$ of neutrophils and $39.7 \pm 1.7\%$ of macrophages was found. The remainder of the cells were lymphocytes and epithelial cells. There were no positive results for pathogenic bacteria.

Comparison of accumulation of discharge in the trachea of control, RAO and IAD horses

During endoscopic evaluation of healthy horses, no accumulation of discharge was noted in the lumen of the trachea (Fig. 1, Table 1). In 99% of horses with diagnosed recurrent airways obstruction (RAO), accumulation of discharge in of the lower 3/4 of the trachea was discovered in the amount described as a grade from 1 to 5 according to the six – grade scale (Allen and Franklin 2007, Bartner et al 2006) (Fig. 1). 63.3% of horses from group 2 showed the presence of a medium or large amount of discharge i.e. grades 2 and 3. In five horses in this group we noted extreme accumulation of discharge constituted 5.3% of examined animals (Fig. 1, Table 1).

In diseased animals from the third group with diagnosed inflammatory airways disease (IAD) the accumulation of discharge was less intense. Accumulation of discharge was noted in 78.7% of affected horses. Second and third grade of accumulation was only present in 48.9% of animals. In horses of this group there was no extreme accumulation of discharge which could be described as grade five in the six grade scale (Fig. 1, Table 1).

Table 2 Assessment of accumulation of muco-purulent discharge in area of tracheal bifurcation in the fourth grade scale by Wysocka in horses with diagnosed RAO and IAD.

Groups of horses	Number of horses (N)	Number (n) and percentage (%) horses included in particular grades in 4 grade scale							
		0		1		2		3	
		n	%	n	%	n	%	n	%
Control	10	10	100	0	0	0	0	0	0
With diagnosed RAO	97	19	19.07	28	29.1 ^b	29	29.6 ^b	21	21.6
With diagnosed IAD	141	92	65.3 ^{a,b}	33	23.3 ^b	15	10.7 ^{a,b}	1	0.7 ^{a,b}

Commentary:

^a – differences statistically relevant ($p < 0,05$) compared to RAO horses

^b – differences statistically relevant ($p < 0,05$) compared to other grades in 4 grade scale

Table 3. Mean values of the ratio of the diameter of the right main bronchus to the thickness of the tracheal septum in control horses and horses with diagnosed RAO or IAD. Values in $X \pm SD$.

Groups of horses	N	Mean index of tracheal septum thickness
Control	10	12.49 \pm 0.67
Horses with diagnosed RAO	97	4.81 \pm 0.22 ^{a,b}
Horses with diagnosed IAD	141	6.81 \pm 0.18 ^a

Commentary:

^a – differences statistically relevant ($p < 0,05$) compared to control horses

^b – differences statistically relevant ($p < 0,05$) compared to horses with IAD

Comparison of accumulation of discharge in the area of tracheal bifurcation

In healthy horses there was no accumulation of discharge in the area of tracheal bifurcation (Fig. 2, Table 2).

In 80.3% of horses with diagnosed recurrent airway obstruction (RAO), an accumulation of discharge in area of tracheal bifurcation was noted. In our research it was found, that the greatest number of horses had little or moderate amounts of mucus i.e. grade 1 and 2, this consisted of 57 examined horses which constituted 58.7% (Fig. 2, Table 2).

In horses from group 3, with inflammatory airway disease (IAD), the presence of discharge in the tracheal bifurcation was noted in 34.7% of horses including 23.3% with little accumulation (grade 1 in Wysocka's scale).

Comparison of tracheal septum thickness index in control, RAO and IAD horses

Based on the measurement of the ratio of the diameter of the main bronchus lumen to the tracheal septum thickness, our research showed that the mean value of this index in healthy animals was 12.49 ± 0.67

(Fig. 3, Table 3). In sick animals, we noted a statistically relevant decrease of this index providing evidence about oedema of the tracheal septum. The greatest decrease of this index compared to that of healthy horses was 61% and occurred in horses with diagnosed recurrent airways obstruction (RAO). In horses from group 3, with inflammatory airway disease (IAD), the decrease of this index was 45% compared to that of healthy horses.

Discussion

Despite the large amounts of research which have focused on the differential diagnosis of non-infectious lower respiratory diseases in the horse, particularly RAO and IAD, this problem still remains unresolved. Therefore, a detailed analysis of observed symptoms which are recorded during clinical and endoscopic examination can significantly contribute to a precise description of these diseases in respect to their pathogenesis, aetiology and accurate diagnosis.

In our studies, a diagnosis of specific symptoms was performed, which allowed us to classify each horse to one of two groups. This diagnosis was based on a detailed case history, general clinical examination and detailed examination of the airways. Horses

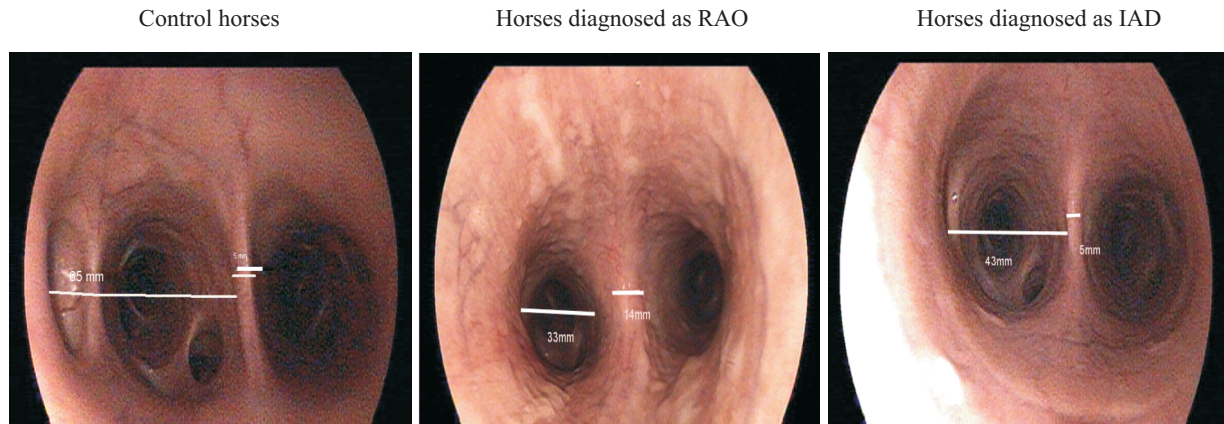


Fig. 3. Measurement of tracheal septum thickness index.

with chronic respiratory distress, presentation of dyspnea during the examination with the formation of a “heave line”, violent cough, nasal discharge, and presence of 70% of neutrophils in bronchoalveolar lavage fluid were assigned to the RAO group.

Horses exhibiting similar symptoms, but to a less severe degree, lacking respiratory distress, and with a lower percentage of neutrophils in bronchoalveolar lavage fluid (only up to 40%) than RAO horses were assigned to the IAD group.

Neither group of sick animals exhibited an elevation of body temperature or growth of pathogenic bacteria known to cause disease in the equine airways, thus indicating the non-infectious aetiology of these diseases.

Assigning horses to one of two groups was based on both our years of professional experience and classification accepted by other authors (Derksen et al. 1989, Whitweel and Greet 1984, Gerber et al. 2004, Couëttil et al. 2007, Allen and Franklin 2007). Precise differential diagnosis at this stage of knowledge is almost impossible. There is a high risk that horses with RAO, but in disease remission, will show the same symptoms as horses with IAD. For the purpose of this study doubtful cases were excluded.

In all horses undergoing endoscopy, attention was focused on the assessment of accumulation of discharge in the lower 3/4 of the tracheal lumen and in the area of tracheal bifurcation and the main bronchi. The primary reason for the assessment of these two spaces was that during endoscopic examination of the horses we observed displacement of discharge as a result of coughing and repositioning of the head and neck after sedation. Due to this displacement, we determined that the assessment of these two areas would provide more precise results. Similar assessment of accumulation of mucus was done by Gerber et al. 2004 and consisted of the examination of 16 horses

diagnosed as either RAO, IAD or healthy and the assessment was done without division to three different groups. To this day in literature the 6 grade scale of accumulation of discharge in the trachea (Allen and Franklin 2007, Bartner et al. 2006) is widely used, but there is no unification of the grading system of mucus in equine airways.

Our study, which provides the results published in this paper, attempts to describe the difference in the amount of discharge more precisely, by taking into account both of the six grade of accumulation of discharge in the tracheal lumen and the four grade scale of accumulation discharge in the area of tracheal bifurcation by Wysocka. Through the use of these two methods, it can be more precisely described that in RAO horses there is higher accumulation of discharge, both in the tracheal lumen and in the tracheal bifurcation, compared to IAD horses (Fig. 1,2, Table 1,2).

In our research, and likewise in Gerber et al 2004, we estimated that the assessment of colour and viscosity of mucus was difficult, but it was noted that in horses with more severe symptoms viscosity was higher. With the accumulation of discharge, a measured increase in the thickness of the tracheal septum was noted, as was previously described by Koblinger et al 2011 only by visual assessment. In our research, pictures from this area were digitally analysed, and then the tracheal septum thickness index was then calculated, which provided an objective description of tracheal septum thickness (Fig. 3).

Analysis of this index showed the usefulness of this parameter to differentiate RAO and IAD. Our analysis showed that horses suffering from RAO typically exhibit an increase of tracheal septum thickness, and this thickening is much greater when compared to IAD horses (Table 3, Fig. 3).

It should be noted that in many cases, where

horses were determined to have medium grades of accumulation of discharge, there is a potential risk that horses with advanced IAD can have the same grade of discharge as horses with a less severe case of RAO.

With respect to the application of the index of tracheal septum thickness, our measurements were more objective and clarified than in previous studies (Koch et al. 2009). Aside from this, we also noted, as was previously described by Koch et al 2009, that there is a difference in the thickness of the tracheal septum between inspiration and expiration, but that this phenomenon was present only in sick animals. In a few animals, there was a decrease in the index as a result of atypical anatomic conformation, but these horses were excluded from the study.

In line with previous studies, such as those by Gerber et al. 2004, the assessment of the accumulation of discharge and the calculation of the tracheal septum thickness index were performed without knowledge of the horse's group assignment in order to avoid biased interpretation of the picture.

Based on our studies, we conclude that the assessment of accumulation of discharge in the tracheal lumen and in the tracheal bifurcation, and the assessment of tracheal septum thickness (based on the measurement of the diameter of the right main bronchus and tracheal septum) extends the list of helpful diagnostic parameters in the differential diagnosis of these two diseases.

Interpretation of the parameters identified should be supported by a detailed case history, along with the examination of both cytological and microbiological results of tracheal washes and bronchoalveolar lavage fluid.

References

Allen K, Franklin S. (2007), RAO and IAD: respiratory disease in horses revisited. *In Practice* 29: 76-85.

- Bartner LR, Robinson NE, Kiupel M, Tesfaigzi (2006) Persistent mucus accumulation: consequences of delayed bronchial mucous cell apoptosis in RAO affected horses? *Am J Physiol Lung Cell Mol Physiol* 291: L602-609.
- Beech J (1975) Cytology of tracheobronchial aspirates in horses *Vet Pathol* 12: 157-164.
- Cardwell JM, Christley RM, Gerber V, Malkide N, Wood J LN, Newton R, Hodgson JL (2011) What's in a name? Inflammatory airway disease in racehorses in training. *Equine Vet J* 43: 756-758.
- Couëtill LL, Hoffman AM., Hodgson J, Buechner – Maxwell V, Viel L, Wood JLN , Lavoie JP. (2007) Inflammatory airway disease of horses. *J Vet Intern Med* 21: 356-361.
- Derksen FJ, Brown CM, Sonea I, Darien BJ, Robinson NE. (1989) Comparison of transtracheal aspirate and bronchoalveolar lavage cytology in 50 horses with chronic lung disease. *Equine Vet J* 21: 23-26.
- Gerber V, Baleri D, Klukowska-Rotzler J, Swinburne JE, Dolf G (2009) Mixed inheritance of equine recurrent airway obstruction. *J Vet Intern Med.* 23: 626-630.
- Gerber V, Straub R, Marti E, Hauptman J, Herholz C, King M, Imhof A, Tahon L, Robinson NE (2004) Endoscopic scoring of mucus quantity and quality: observer and horse variance and relationship to inflammation, mucus viscoelasticity and volume. *Equine Vet J* 36: 576-582.
- Kluciński W, Winnicka A, Olszewski M, Sikora J, Sitarska E, Niemiałtowski M, Muzyłak M, Bylinka G, Wyszynski M (1994) Phagocytic activity of polymorphonuclear leukocytes lavaged from the lungs of horses with clinically diagnosed chronic pulmonary disease. *Zentralbl Veterinarmed A* 41: 558-567.
- Koblinger K, Nicol J, McDonald K Wasko A, Logie N, Weiss M, Le'guillette R (2011) Endoscopic assessment of airway inflammation in horses. *J Vet Intern Med* 25: 1118-1126.
- Koch C, Straub R, Ramseyer A, Widmer A, Robinson NE, Gerber V (2007) Endoscopic scoring of the tracheal septum in horses and its clinical relevance for the evaluation of lower airway health in horses. *Equine Vet J* 39: 107-122.
- Laus F, Attil AR, Cerquetella M, Spaterna B, Tesse B, Cuteri V (2009) Endoscopic findings, microbiological and cytological evaluation of tracheal aspirates in a population of standardbred horses with poor performances. *Vet Med – Czech* 54: 444-450.
- Olszewski M, Kluciński W (1993), Chronic pulmonary disease in horse (COPD). *Medycyna Wet.* 49:70-73.
- Whitweel KE, Greet TR, (1984) Collection and evaluation of tracheobronchial washes in the horse. *Equine Vet J* 16: 499-508.