

Severe gynaecomastia associated with spironolactone treatment in a patient with decompensated alcoholic liver cirrhosis – Case report

Katarzyna Schab¹, Andrzej Prystupa², Dominika Mulawka³, Paulina Mulawka³

¹ 1st Military Teaching Hospital and Polyclinic, Lublin, Poland

² Department of Internal Medicine, Medical University, Lublin, Poland

³ Cardinal Stefan Wyszyński District Specialist Hospital, Lublin, Poland

Schab K, Prystupa A, Mulawka D, Mulawka P. Severe gynaecomastia associated with spironolactone treatment in a patient with decompensated alcoholic liver cirrhosis – Case report. *J Pre-Clin Clin Res.* 2015; 9(1): 92–95. doi: 10.5604/18982395.1157586

Abstract

Gynaecomastia is uni- or bilateral breast enlargement in males associated with benign hyperplasia of the glandular, fibrous and adipose tissue resulting from oestrogen-androgen imbalance. Asymptomatic gynaecomastia is a common finding in healthy male adults and does not have to be treated, while symptomatic gynaecomastia might be the symptom of many pathological conditions and requires meticulous diagnosis and therapeutic management. The commonest causes of gynaecomastia in the Polish population include liver cirrhosis and drugs used to treat its complications. The current study presents the case of severe painless gynaecomastia in a patient with decompensated alcoholic liver cirrhosis, treated with spironolactone because of ascites. Breast enlargement assessed a IIb according to the Simon's Scale or III according to the Cordova-Moschella classification, developed slowly over the two-year period of low-dose spironolactone therapy. The course and dynamics of disease are described and the main mechanisms leading to its development discussed. The importance of effective treatment of patients with severe gynaecomastia is emphasized as the disease may result in significant psychosocial problems.

Key words

gynaecomastia, spironolactone, decompensated alcoholic liver cirrhosis

INTRODUCTION

Gynaecomastia is uni- or bilateral breast enlargement in males associated with benign hyperplasia of the glandular, fibrous and adipose tissue, resulting from oestrogen-androgen imbalance affecting functional integrity of the glands [1]. Asymptomatic palpable gynaecomastia appears to be a frequent finding in healthy adult men; its estimated prevalence is 32–65% [2]. The incidence of clinically evident, symptomatic gynaecomastia, however, is significantly lower [1]. Both types of gynaecomastia are commonly diagnosed in patients with BMI > 25 kg/m² (even 80%) [2] and liver cirrhosis (40–60%) [3]. Gynaecomastia coexists with many pathological conditions, including chronic liver disease, which is of unquestionable epidemiological importance for the Polish population. Another common trigger for gynaecomastia-inducing mechanisms may be drugs, affecting the hormonal balance. The most frequent causes of gynaecomastia are listed in Table 1. This study presents the clinical case of a patient with alcoholic liver cirrhosis who developed severe gynaecomastia due to the treatment of ascites. The possible mechanisms leading to breast enlargement are analyzed and the clinical implications of gynaecomastia for the patient considered.

Table 1. Causes of gynaecomastia based on [4]

Physiological states (20%)	Pathological conditions (30%)	Drugs taken (10–20%)	Idiopathic (25%)
neonatal period	alcoholic cirrhosis or malnutrition (8%)	hormonal therapies, spironolactone,	
adolescence	primary hypogonadism (8%), testicular tumours (3%), secondary hypogonadism (2%)	antifungal, anti-HIV, PPI, psychotropic	
aging	hyperthyroidism (2%)	drugs circulatory	
	hyperthyroidism (2%)	drugs	
	kidney diseases (1%)		
	others (6%)		

CASE REPORT

In February 2013, a 44-year-old male patient with alcoholic liver cirrhosis was admitted to the Department of Internal Medicine at the Medical University in Lublin, with coffee ground vomits, jaundice, distinct weakness, considerably decreased exertion tolerance and episodes of anxiety. The patient was conscious and remained in good verbal contact; BMI remained within normal limits (BMI=24.01 kg/m²), abdominal size was increased. Teleangiectasiae were found on the chest and limbs, the pubertal and axillary hair was significantly reduced. The patient reported breast enlargement enhancing for three years. The substantially enlarged breasts were inspected and palpated. In a sitting position with arms relaxed, a firm, mobile lump was palpated beneath each nipple. No focal nodular thickening was palpated. High frequency ultrasound of each breast confirmed true gynaecomastia with

Address for correspondence: Andrzej Prystupa, Department of Internal Medicine, Medical University, Staszica 16, 20-081 Lublin, Poland
E-mail: aprystup@mpl

Received: 15 November 2013; accepted: 28 January 2015



fibrous tissue predominance. The enlargement of each breast was evaluated as IIB according to the Simon's Scale, and III according to the Classification of Cordova-Moschella (Tab. 2).

Table 2. Morphological classifications of gynaecomastia

Classification by Simon and [5]	Classification by Cordova-Moschella, modified by [6]
I Minor breast enlargement without skin redundancy	I Increased diameter and slight protrusion limited to the areolar region
II a Moderate breast enlargement without skin redundancy	II Moderate hypertrophy of the breast with the nipple-areolar complex above the inframammary fold.
II b Moderate breast enlargement with skin redundancy	III Major hypertrophy of the breast with glandular ptosis and nipple-areolar complex situated at the same height as or as much as 1 cm below the inframammary fold.
III Gross breast enlargement with skin redundancy that stimulated a pendulous female breast.	IV Major breast hypertrophy with skin redundancy, severe ptosis and the nipple-areolar complex positioned more than 1 cm below the inframammary fold.

Laboratory tests at admission revealed anaemia (RBC = 3.97 M/ul, HGB = 10 g/dl, MCV = 78.8 fl, MCH = 25.2 pg), low platelets (PLT = 58 K/ul) and granulocytes (NEU = 1.71 K/ul), elevated liver enzymes (AspAT = 78.7 IU/l, ALAT = 16.8 IU/l) higher total bilirubin (4.34 mg/dl) and hypokalemia (3.14 mmol/l).

The patient had been attending the Department of Internal Medicine for four years. During this period he was repeatedly hospitalized, twice with the symptoms of severe exacerbation. He first presented to our outpatient clinic in 2009 with growing fatigability, pain, and spragging in the right upper abdomen, jaundice and oesophageal varices. Laboratory findings included elevated liver enzymes (AspAT = 92 IU/l, ALAT = 34 IU/l), high serum bilirubin (2.85 mg/dl) and elongated clotting times (PT = 19.4s, INR = 1.7). The above findings and negative results of HBV and HCV tests, together with the long alcohol abuse, led to the diagnosis of decompensated alcoholic liver cirrhosis. Spironolactone was one of the medications recommended for home use (Tab. 3) and it has been taken regularly in low doses (50 mg daily) since October 2009. The gradually progressing symmetrical painless breast enlargement was first observed after six months of spironolactone treatment; initially it was building up slowly and was not troublesome for the patient until it became significantly intense. The progression of gynaecomastia resulted in severe psychological and physical distress and limited the patients activities. He gave up swimming and started to avoid people because of strong dissatisfaction with his appearance and resultant low self-esteem.

In July 2011, the patient was admitted with massive bleeding from the digestive tract, deep anaemia (RBC = 2.92 M/ul, HGB = 9.3 g/dl), jaundice (total bilirubin = 20.34 mg/dl), haemostasis impairment (PT = 25.86 s, INR = 2.27, APTT = 41.79 s), oedemas, and qualitative and quantitative consciousness disturbances. Laboratory findings indicated acute pancreatitis (serum amylase = 133 IU/l, CRP = 43.2 mg/l, procalcitonine = 1.2 ng/ml, glucose = 193.4 mg/dl) and severely deteriorated liver function (AspAT = 241.2 IU/l, ALAT = 29.9 U/l, GGTP = 83.2 IU/l, urea = 100.4 mg/dl, albumin = 2.4 g/dl). Abdominal ultrasound scan demonstrated an enlarged liver with heterogeneous

echogenicity, polycyclic contour and reduced vascular pattern. The residual amount of fluid in the perihilar region was visualized. The pancreatic area was broadened and hypoechogenic with evident Wirsung's duct, indicating acute pancreatitis. The spleen and splenic vein were slightly widened. Endoscopic obliteration of oesophageal varices and subsequent Segstaken-Blakemoore tube insertion were required. The pharmacological management instituted significantly improved the patient's condition.

Since the time when the patient ceased to drink alcohol, his results are slightly better. On physical examinations the liver evolved from strongly enlarged to reduced in size, fibrotic and not palpable. The medications were continued because of recurring exacerbations, bleeding from the digestive tract and remaining ascites. The patient did not consent to switching from spironolactone to another drug because of a significant difference in price. Currently, the patient remains under the care of substance abuse outpatient services, and has been qualified for liver transplantation.

Table 3. Drugs recommended for home use after discharge

timonacicum 100 mg	hydroxyzine 25 mg
cyclonamine	propranolol 40 mg
spironolactone 50 mg	omeprazol 80 mg
furosemidum 40 mg	kalium
quetiaprine	

DISCUSSION

Hormonal balance in healthy male adults is maintained with proper gonadal function (testosterone, dehydrotestosterone and low oestrogenes production, limited conversion of androstenedione to oestrone in the adipose tissue (optimal fat content in males aged 30–50 years is between 17–25%, BMI < 25 kg/m²), correct metabolic function of the liver (androstenedione utilization) and normal tissue's sensitivity to androgens. In the patient in the presented study, three main mechanisms inducing hormonal imbalance were considered:

1. metabolic impairment to severely compromised function of cirrhotic liver;
2. side-effects of drugs taken (spironolactone; omeprazole; quetiaprine);
3. previous long-term alcohol abuse, affecting the hypothalamic-pituitary-gonadals axis.

Gynaecomastia commonly coexists with liver cirrhosis and 40–60% of cirrhotic patients are affected [3]. Lower testosterone production, restrained androstenedione metabolism and its enhanced conversion to oestrone, are common anomalies resulting from cirrhosis. Additionally, oversynthesis of sex hormone-binding globulin (SHBG) by the fibrotic liver elevates the already increased free oestrogen to androgen ratio, as SHBG bind androgens with greater affinity than oestrogens[7].

Although the involvement of ethyl alcohol in the development of gynaecomastia remains unclear, its influence on the levels of sex hormones and SHBG synthesis is well known [8]. The presented patient had abused alcohol for several years and ceased to drink in 2011. The alcohol-related hormonal disturbances are believed to maintain for a long

period after withdrawal; thus, in the case described, the ethanol's contribution to the development of gynaecomastia cannot be excluded.

The correlation between spironolactone treatment and hormonal changes leading to gynaecomastia has been well demonstrated. The mechanisms of relative hyperestrogenism are shown in Fig. 1. According to previous studies, the risk of gynaecomastia during spironolactone therapy is strongly correlated with its doses [9]. Relatively low doses taken by the patient (50 mg daily) compared to those used in the studies mentioned, should induce gynaecomastia after a longer period of time than in the presented patient (about 6 months). The effects of omeprazol on gonadal hormones changes have not been fully elucidated. Its larger doses inhibit oestrogen metabolism and thus increase the oestrogen to androgen ratio [10]. Several other studies described cases of proton pump inhibitor- induced gynaecomastia subsiding after drug discontinuation [11, 12].

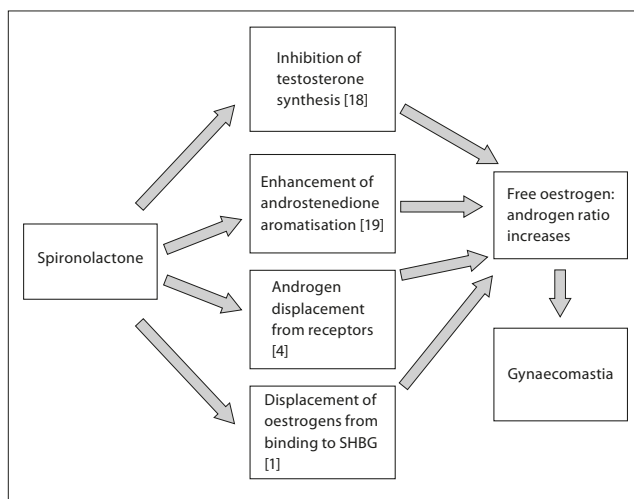


Figure 1. Mechanisms of spironolactone involvement in the developing gynaecomastia

Diagnostic procedures. The first step in the diagnosis is to differentiate true gynaecomastia and pseudogynaecomastia (lipomastia, steatomastia) which is mammary enlargement due to accumulation of the adipose tissue with no glandular proliferation. On palpation the stromal and glandular tissue appears as a firm discoid structure beneath the nipple, separated from the softer adipose surroundings. Pseudogynaecomastia is commonly found in obese or overweight men, and body mass reduction results in its reversion; true gynaecomastia, on the other hand, results from hormonal imbalance coexisting with certain pathology that needs to be treated. The next step is to differentiate the two forms of true gynaecomastia i.e. florid and fibrous, by high-frequency ultrasound examination. This is the most suitable method for visualizing both the fibrous and glandular tissue, assessing their proportions and identifying reversible gynaecomastia, which can be treated pharmacologically [20].

Management. According to literature reports, the incidence of spontaneous remission of gynaecomastia is 85%, yet the majority of those spontaneously reversible cases are physiological gynaecomastia (adolescence, aging) [4]. The other types of gynaecomastia require a comprehensive

diagnostic and therapeutic approach. In the presented patient, three mechanisms leading to gynaecomastia had to be eliminated to ensure his recovery. The patient has stopped drinking alcohol and is being prepared for liver transplantation that should significantly improve his hormonal imbalance. Moreover, the withdrawal of spironolactone or its replacement with another agent of a similar therapeutic profile is advisable. Previous studies demonstrated the beneficial effects of cancreonate on reversing spironolactone-induced gynaecomastia [13]. Cancreonate, as one of two spironolactone metabolites which shows therapeutic effects similar to those of spironolactone, but without the side-effects of the other metabolite, i.e. 7- α -hydroxyspironolactone responsible for gynaecomastia [14]. Elplerenon is described as a safe and beneficial option for spironolactone therapy in liver cirrhosis [15]. The reliability of these data, however, is limited by the fact that the studies were performed in small groups of patients. Another factor that limits the use of these drugs is their price, a significant factor for many patients.

An important factor that should be considered while choosing the best therapeutic approach in patients with gynaecomastia is the time elapsing from the onset of first symptoms. In patients with chronic gynaecomastia (>1 year), the amount of fibrous tissue increases and gynaecomastia is less likely to remit after the removal of its cause. Surgical treatment should be considered in cases of persistent severe gynaecomastia (IIb/III Simon Scale), resistant to conservative treatment and causing significant distress, as in the presented patient [4]. However, its use is still limited by a high incidence of complications and unsatisfactory cosmetic effects [16].

CONCLUSIONS

True gynaecomastia in liver cirrhosis is a significant issue in clinical practice. It constitutes an embarrassing problem and a strong psychological burden for the patient, irrespective of age. The studies conducted in 47 patients with symptomatic gynaecomastia clearly showed the extent of psychological problems in this group of patients: 100% of them experienced emotional discomfort and significant limitations in their everyday activities, and the great majority reported difficulties in social contacts and with isolation [17], as proved by the presented study.

REFERENCES

1. Johnson RE, Murad MH. Gynecomastia: Pathophysiology, Evaluation, and Management *Mayo Clin Proc.* 2009; 84(11): 1010–1015.
2. Niewoehner CB, Nuttal FQ. Gynecomastia in a hospitalized male population. *Am J Med.* 1984; 77(4): 633–638.
3. Trivedi M. Androgen replacement in early alcoholic cirrhosis? *Postgrad Med.* 2005; 117:32.
4. Braunstein GD. Gynecomastia. *N Engl J Med.* 1993; 328: 490–495.
5. Simon BE, Hoffman S, Kahn S. Classification and surgical correction of gynecomastia. *Plast Reconstr Surg.* 1973; 51: 48.
6. Alfredo Carlos Simões Dornellas de Barros, Marcelo de Castro Moura Sampaio. Gynecomastia: physiopathology, evaluation and treatment. *Sao Paulo Med J.* 2012; 130(3): 187–197.
7. Baker HWG, Burger HG, deKretser DM, et al. A study of the endocrine manifestations of liver cirrhosis. *Q J Med.* 1976; 45(new series):145–178.
8. Bannister P, Lowosky MS. Ethanol and hypogonadism. *Alcohol and Alcoholism* 1987; 22(3): 213–217.

9. Pitt B, Zannad F, Remme WJ, et al. The effect of spironolactone on morbidity and mortality in patients with severe heart failure. Randomized Aldactone Evaluation Study Investigators. *N Engl J Med.* 1999; 341(10): 709–717.
10. Satoh T, Fujita KI, Munakata H, et al. Studies on the interactions between drugs and estrogen: analytical method for prediction system of gynecomastia induced by drugs on the inhibitory metabolism of estradiol using *Escherichia coli* coexpressing human CYP3A4 with human NADPH-cytochrome P450 reductase. *Anal Biochem.* 2000; 286(2): 179–186.
11. Carvajal A, Macias D, Gutierrez A, et al. Gynaecomastia associated with proton pump inhibitors: a case series from the Spanish Pharmacovigilance System. *Drug Saf.* 2007; 30(6): 527–531.
12. Santucci L, Farroni F, Fiorucci S, et al. Gynecomastia during omeprazole therapy. *N Engl J Med.* 1991; 324(9): 635.
13. Bellati G, Ideo G. Gynecomastia after spironolactone and potassium canrenoate. *Lancet* 1986; I: 626.
14. Overdiek JWPM, Markus FWHM. Spironolactone metabolism and gynecomastia. *Lancet* 1986; 10:1103.
15. Dimitriadis G, Papadopoulos V, Mimidis K. Eplerenone reverses spironolactone-induced painful gynecomastia in cirrhotics. *Hepatol Int.* 2011; 5: 738–739.
16. Colombo-Benkmann M, Buse B. Surgical therapy of gynecomastia and its results. *Langenbecks Arch Chir Suppl Kongress.* 1998; 11: 1282–1284.
17. Kasielska A, Antoszewski B. Effect of operative treatment on psychosocial problems of men with gynecomastia. *Polski Przegląd Chirurgicalny* 2011; 83(11): 614–621.
18. Loriaux DL, Menard R, Taylor A, Pita JC, Santen R. Spironolactone and endocrine dysfunction. *Ann Intern Med.* 1976; 85: 630–636.
19. Coen P, Kulin H, Ballantine T, et al. An aromatase producing sex-cord tumour resulting in prepubertal gynecomastia. *N Engl J Med.* 1991; 324(5): 317–322.
20. Cilotti A, Campassi C, Bagnolesi P, Moretti M, Caramella D, Bartolozzi C. Gynecomastia: diagnostic value of high frequencies ultrasound (10–13 MHz). *Breast Dis.* 1996; 9: 61–69.

