

Prenatal development of the stomach in the goat (*Capra hircus*)

Natalia Wojtasiak[#], Tomasz Stankiewicz

West Pomeranian University of Technology, Faculty of Biotechnology and Animal Husbandry,
Department of Animal Reproduction Biotechnology and Environmental Hygiene, ul. Janickiego
29, 71-270 Szczecin, Poland

SUMMARY

During organogenesis in the developing goat embryo, a four-chamber stomach is formed from an extension of the primary intestine. Due to histological and morphological changes, each chamber of the stomach takes on characteristic features associated with its function. The histological structure of the stomach wall consists of four layers, the mucosa, submucosa, tunica muscularis and serosa. This work presents the current state of knowledge of the changes observed in each layer of the developing stomach and its morphogenesis in the prenatal period. Practical applications of this information in prenatal ultrasound diagnostics in goats are suggested as well.

KEY WORDS: prenatal development, organogenesis, stomach, goat

INTRODUCTION

The embryonic and foetal development of goats is an interesting subject of research, especially with regard to the histological and morphological changes taking place in the differentiating cells of the embryonic layers. Cells taking on features characteristic of tissues of the digestive system form organs that eventually develop into the four-chamber stomach characteristic of the species. During embryonic development, a four-chamber stomach is formed, whose structure influences the functions it performs. Analysis of the course of development of the goat stomach during the prenatal period can contribute to a better understanding of the functioning of this organ and possible causes of its dysfunction.

The goat stomach has the capacity to transform low-quality feed into products of high nutritional value (Jakhesara et al., 2010; Agrawal et al., 2014). To meet the body's nutritional needs, four separate chambers have developed in it: the rumen, reticulum, omasum and abomasum.

Each chamber has species-specific histological structures that reflect its morphological and

[#] Corresponding author e-mail: wojtasiak1natalia@gmail.com

Received: 11.01.2021

Received in revised form: 15.03.2021

Accepted: 17.03.2021

Published online: 19.03.2021

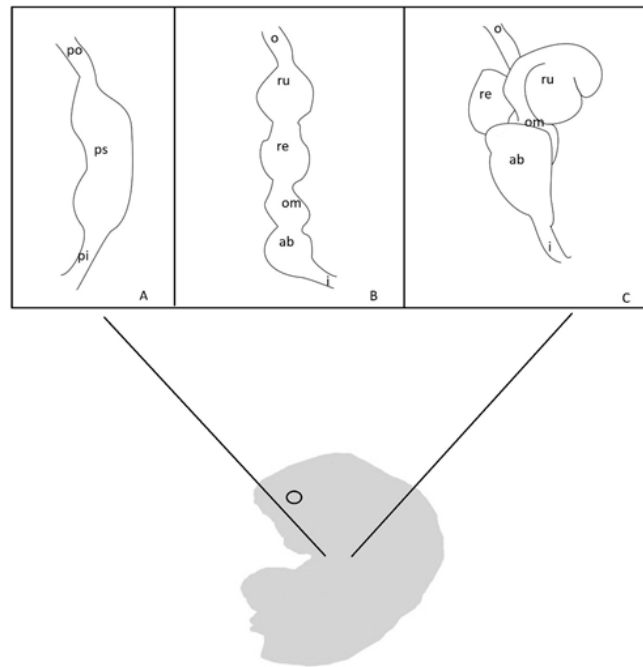
functional adaptation to the processing and digestion of plant material (Giger-Reverdin et al., 2020). Before the food reaches the abomasum, which is the counterpart of a monogastric glandular stomach, it undergoes digestion in the three other chambers, known as the forestomach (Teixeira et al., 1998). These play the primary role in bacterial digestion of cellulose, acting as fermentation chambers. At the same time, peristaltic movements are observed in them, as well as contractions and separation of fluids from solids (Membrive, 2016). The histological structure of the stomach wall in the goat consists of four layers, the mucosa, submucosa, tunica muscularis and serosa. In the mucosa, we can distinguish the stratified squamous epithelium, lamina propria and muscular layer. The muscular layer is not present in the mucosa of the rumen (Garcia et al., 2014a). The rumen is distinguished by cranial and caudal transverse pillars, left and right longitudinal pillars, and dorsal and ventral coronary pillars on its inner surface. On its outer surface there are cranial and caudal transverse grooves, left and right longitudinal grooves, and dorsal and ventral coronary grooves. The pillars and grooves together demarcate the ventral and dorsal ruminal sacs, while the dorsal and ventral coronary grooves demarcate the blind sacs of the rumen, i.e. the ventrocaudal and dorsocaudal blind sacs (Gupta et al., 2017a). The papillae of the rumen are projections from the epithelium that give the ruminal mucosa its characteristic appearance. The reticulum has cristae reticuli, which give the mucosa an appearance reminiscent of honeycomb, and these have papillae on them. The omasum has longitudinal folds of varied height known as laminae, with numerous conical papillae. In the abomasum, the surface of the mucosa is characterized by numerous folds (El-Gendy and Derbalach, 2010; Garcia et al., 2014a).

Prenatal development of the forestomach and abomasum in the domestic goat

During its passage through the oviduct, the fertilized goat oocyte undergoes a series of mitotic divisions known as cleavage. The first division, dividing the embryo into two blastomeres, can be observed 30 h after fertilization (Cheng et al., 1995; Majeed et al., 2019). On the 6th day after fertilization the goat embryo shows structural changes indicative of transformation into a blastocyst. At this time the central embryonic cells exhibit signs of strong growth, and the blastocyst cavity begins to form. The cells concentrated on one embryonic pole form the primitive node, in which we can distinguish cells of the epiblast and hypoblast, which lines the trophoblast around the blastocyst cavity, thus forming the yolk sac (Molinari and Goicoechea, 1993). Further embryonic development involves the disappearance of the zona pellucida, rapid growth and development of the blastulas, and the formation of the germ layer, i.e. gastrulation. In this form the embryo is implanted in the wall of the uterus, where subsequent stages of embryonic development take place. The endoderm, ectoderm and mesoderm formed during gastrulation form most of the organs and tissues.

The epithelium of the digestive tract is of endodermal origin, while the connective tissue and muscles originate in the splanchnic mesoderm (McGeady et al., 2017). The stomach in the goat embryo appears as an extension of the primary intestine in its midline, in the future cervical region. With further development, its shape and orientation change. The stomach primordium grows rapidly. Its dorsal margin grows faster than the ventral margin, which leads to the formation of the greater and lesser curvatures. The compartments of the stomach develop separately from the same extension – the rumen and reticulum from the greater curvature and the omasum from the lesser curvature (McGeady et al., 2017). On the 38th day of gestation the stomach is visible in the goat embryo as four consecutive extensions. The first extension on the left is the rumen, and the second, placed caudoventrally with respect to the rumen, is the reticulum. The third extension, appearing along the

lesser curvature, is the omasum. The abomasum is located along the ventral midline of the stomach in the pyloric part (Fig. 1.) (Gupta et al., 2017ab).



A (about 30 d of gestation): po – primordial oesophagus, ps – primordial stomach, pi – primordial intestine; B (38 d of gestation), C (about 50 d of gestation): o – oesophagus, ru – rumen, re – reticulum, om – omasum, ab – abomasum, i – intestine

Fig. 1. Diagram of consecutive stages of stomach development in the goat foetus

Prenatal development of the rumen in the goat foetus

Histogenesis of the foetal rumen

The outline of the rumen appears as a spindle-shaped tube with one cavity. Its walls consist of two well-differentiated layers. The first, the inner layer of stratified epithelium, is composed of cylindrical cells with a nucleus at the base and apical cytoplasm. The second is outer pluripotent blastemal tissue, composed of randomly distributed elliptical layered cells, with a round cell nucleus and eosinophilic cytoplasm (Garcia et al., 2012; Okpe et al., 2016; Soni et al., 2016). Then the serous layer is formed of a single layer of flat cells (the mesothelium) supported by connective tissue. As the embryo develops, the thickness of the ruminal epithelium is increased through an increase in the number of cells. On the 39th day of foetal life the epithelium of the rumen has two bands of cells: darker cells, rich in nuclei, and lighter ones with apical cytoplasm. On day 46, small papilla-like protrusions grow out of the epithelial layer into the lumen, forming primary pillars of the rumen. These pillars ensure the inner division of the rumen into sacs, and all tissue layers of the wall are involved in their formation. On day 50 of foetal life, the pluripotent blastemal tissue of the rumen

shows signs of differentiation into the lamina propria and submucosa. A primary muscular layer develops, consisting of two layers of myoblasts – an inner, circular layer and an outer longitudinal layer (Garcia et al., 2014a; Gupta et al., 2017a; Soni et al., 2016). On day 53, the epithelium of the goat rumen has two distinctly differentiated bands, a thinner band of oval cells with basophilic cytoplasm forming a basal layer and a thicker apical band of polyhedral cells forming a granular layer. Next, delicate depressions of the basal layer into the granular layer form the primary papillae of the rumen. The lamina propria protrudes within the basal layer, thus creating papillae. The tunica muscularis at this stage consists of two interwoven bundles of smooth muscle fibres – inner circular bundles and outer longitudinal bundles. It is thicker within the pillars of the rumen (Garcia et al., 2012; Garcia et al., 2014a; Soni et al., 2016). On day 76 of the foetal life of the goat, the serosa consists of squamous epithelium. Connective tissue rich in reticulin fibres, an extracellular matrix and blood vessels is formed as well. The epithelium has four layers. On the inner side there is a basal layer consisting of cells with basophilic cytoplasm. Next are a granular layer, a spinous layer, and a horny layer, which is formed of a single layer of flat cells. The papillae of the rumen gradually become longer and thicker. Next, the lamina propria and submucosa become highly vascularized. At this stage, the tunica muscularis becomes thicker, while the serosa consists of squamous epithelium and connective tissue. The epithelium of the most developed ends of the papillae undergoes corrugation. The lamina propria, visible in every pillar forming the skeleton of the papilla in the foetal goat rumen, is made of dense, fibrous connective tissue. The submucosa consists of fibres of elastin and collagen. At the same time, the tunica muscularis of the rumen becomes vascularized and thickened (Garcia et al., 2012; Garcia et al., 2014a; Okpe et al., 2016; Soni et al., 2016)

Morphogenesis of the rumen

On day 35, the stomach of the foetal goat has the form of a tube. On day 46, there is a change in the position of the sacs in the rumen. Its dorsal part, together with the developing spleen, is adjacent to the cranial end of the Wolffian duct, while the ventral part is associated with the developing gonads (Gupta et al., 2015; Gupta et al., 2017a). The dorsal and ventral sacs of the rumen of the foetal goat attain the same position at the start of the second trimester (Fig. 1. C). Throughout gestation, the visceral surface of the dorsal sac adjoins the developing abomasum. Garcia et al. (2012, 2014a) report that after 55 days of gestation emerging papillae are observed on the inner surface of the rumen, and after 90 days they are fully formed. According to other authors, the inner surface of the rumen of the goat foetus is smooth, soft and whitish on day 75 of gestation, and distinct papillae are visible after 113 days (Gupta et al. 2015; Gupta et al., 2017b). The development of the rumen during the embryonic period involves the formation and differentiation of the rumen wall and differentiation of the epithelial layer. Numerous regulatory factors are involved in genetic control of rumen development, including miRNA – microRNA (Zhong et al., 2017). Transcriptome profiling was used to determine the role of miRNA in pathways taking part in rumen development. The miRNA expression profile in rumen tissue at various stages of prenatal development showed that miRNA may play an important role in forming the layers of the rumen (Zhong et al., 2017; Zhong et al., 2020).

Prenatal development of the reticulum in the goat

Histogenesis of the foetal reticulum

The reticulum in the goat foetus becomes a separate compartment of the stomach 35 days after fertilization (Garcia et al., 2013c). The wall of the reticulum consists of three layers during this period: an inner epithelial layer, a middle layer of pluripotent cells forming blastemal tissue, and an outer layer – the serosa (Okpe et al., 2016; Soni et al., 2016; Gupta et al., unpublished data). The epithelium consists of two layers. The first layer is formed of cells with a centrally located nucleus, and the second, outer layer is formed of spherical cells with apical nuclei. The pluripotent blastemal layer consists of an extracellular matrix with suspended star-shaped mesenchymal cells. The serosa consists of loose connective tissue covered with a squamous epithelium (Garcia et al., 2013c; Soni et al., 2016). On day 50 of foetal life, the epithelium of the reticulum is clearly divided into a basal layer, formed by three layers of horny cells, and a thicker, granular layer with 6 to 8 layers of spherical cells, located closest to the lumen of the rumen. The pluripotent blastemal tissue consists of an extracellular matrix with suspended mesenchymal cells reminiscent of fibroblasts. The appearance of fibroblasts differentiates the blastemal tissue into the lamina propria and the submucosa. At this stage we can distinguish the tunica muscularis from the pluripotent blastemal tissue as a layer of longitudinally arranged myoblasts. The serosa consists of loose connective tissue lying under a squamous mesothelium (Garcia et al., 2013c; Garcia et al., 2014ab; Okpe et al., 2016; Soni et al., 2016). After 53 days of gestation, the wall of the reticulum in the goat foetus consists of four distinct tissue layers: the epithelium, lamina propria with the submucosa, the tunica muscularis, and the serosa. The lamina propria and submucosa consist of cellular elements, such as fibroblasts, and collagen and reticulin fibres, suspended in an extracellular matrix. In the tunica muscularis, we can distinguish two layers: an inner layer composed of obliquely arranged smooth muscle fibres and an outer layer consisting of longitudinally arranged muscle fibres. On day 59 of goat gestation, primary cristae reticuli are visible in the foetal reticulum as protrusions from the basal epithelial layer. On day 65 they are larger and regularly distributed on the epithelium. At mid-gestation the histological structure of the wall of the reticulum is similar to that observed in the earlier stages, although some of its layers are markedly different (Garcia et al., 2013c; Garcia et al., 2014ab; Okpe et al., 2016; Soni et al., 2016; Gupta et al., unpublished data). The primary cristae reticuli become more visible and grow towards the lumen of the reticulum. On day 87 of gestation the surface of the lateral walls of the cristae reticuli is covered with numerous papillae formed of cells of the basal layer of the epithelium. On day 113 of gestation the stratified epithelium of the reticulum of the goat foetus consists of four fully developed layers (basal, granular, horny and spinous). The skeletons of the primary and secondary cristae reticuli and papillae are formed by the lamina propria, consisting of fibroblasts and collagen fibres containing numerous blood vessels. The submucosa consists of a small number of spindle-shaped and star-shaped cells suspended in an extracellular matrix. Towards the end of gestation, the upper part of the cristae reticuli contains a well-developed muscular layer of the mucosa, which is visible as a continuous band of muscle tissue connecting one crista to another. The tunica muscularis of the reticulum looks the same as in the earlier stages of gestation and consists of two layers of smooth muscle. The outer serosa is formed of a sublayer of loosely arranged fibrous connective tissue surrounded by a mesothelial layer of flat cells (Garcia et al., 2013c; Garcia et al., 2014ab; Okpe et al., 2016; Soni et al., 2016).

Morphogenesis of the reticulum

The reticulum in the goat becomes a separate compartment of the stomach after 35 days of foetal life (Garcia et al., 2013c). The reticulum grows along the dorsoventral axis of the embryo. It is visible as the second extension lying by the larger curvature of the stomach. In the initial embryonic stages, the reticulum is observed as a rounded recess lined with a smooth, soft and whitish mucosa. After the change in position of the rumen, the reticulum lies in a cranioventral position. From day 50 of gestation a clear demarcation can be seen between the rumen and reticulum in the form of the ruminoreticular fold. After 66 days, the reticulum becomes the most cranially oriented part of the stomach (Fig. 1. C). In the second trimester, the first cristae reticuli begin to appear, and at about 115 days of foetal life they give the inner surface of the reticulum an irregular shape reminiscent of honeycomb (Gupta et al., 2017b).

Prenatal development of the omasum in the goat

Histogenesis of the foetal omasum

On day 35 of the foetal life of the goat, the wall of the omasum consists of two layers: an epithelial layer and an outer layer of pluripotent blastemal tissue. On day 38 of gestation, the wall of the omasum also contains a third, serous layer. At this stage papillae of the omasum appear as protrusions from the wall of the omasum. The epithelium of the omasum consists of two layers, the first of which is lighter and contains spherical cells. The other is darker and built of cylindrical cells. The pluripotent layer of blastemal tissue consists of mesenchymal stem cells suspended in an extracellular matrix. Towards the end of the first trimester, histological changes take place in each layer of the omasum wall. The epithelium is clearly divided into a basal layer, consisting of 2 to 4 layers of horny cells, and a thicker outer granular layer consisting of 6-10 layers of spherical cells (Garcia et al., 2013b; Garcia et al., 2014a; Okpe et al., 2016; Soni et al., 2016). On day 50 of foetal life, secondary omasal laminae appear between the primary laminae. Both the primary and secondary laminae appear as outer folds of the basal layer of the epithelium. The middle layer of blastemal tissue is formed of connective tissue suspended in an extracellular matrix. At this time, the first signs of differentiation of this layer into the lamina propria and submucosa are visible. Both layers take part in the formation of the omasal laminae. During this period we also observe the first myoblasts surrounded by blastemal tissue, which later form the muscle layer of the omasum wall. The serosa of the omasum at 50 days of foetal life contains a sublayer of loosely arranged connective tissue under a layer of flat mesothelial cells. From 53 to 75 days of foetal life, the wall of the omasum consists of four layers: the mucosa, formed of the epithelium and lamina propria, the submucosa, the tunica muscularis, and the serosa (Garcia et al., 2013b; Okpe et al., 2016; Soni et al., 2016). The epithelium consists of a basal layer and a granular layer. At this stage of foetal life we can also see an outer horny epithelium, formed by flat nucleated cells. The lamina propria consists of fibroblast-rich connective tissue suspended in an extracellular matrix. The tunica muscularis is formed from the inside by a circular layer and from the outside by a longitudinal layer of smooth muscle cells. After day 64 of gestation, in the centre of the omasal laminae, a layer of flat muscle fibres originating in the inner circular layer of the tunica muscularis is visible. During this period of the foetal life of the goat, the primary and secondary omasal laminae are thicker and higher than the tertiary and quaternary laminae. They are built of all tissue layers: epithelial, lamina propria and submucosa, and muscularis. However, they do not have a serosa (Garcia et al., 2013b; Okpe et al., 2016; Soni et al., 2016). From day 70 of the foetal life of the goat, conical papillae are observed on the surface of the primary and secondary

laminae as protrusions from the basal layer of the epithelium. Between 76 and 112 days of foetal life, the horny epithelium, formed by flat nucleated cells, is the layer of the wall of the omasum located closest to its lumen. The conical papillae on the primary and secondary omasal laminae are filled with connective tissue derived from the lamina propria and submucosa. After 100 days of foetal life, the tunica muscularis is visible within the omasal laminae. At the end of prenatal development, all of the omasal laminae, of varying thickness, can be seen. The surfaces of the laminae are covered with conical papillae. The laminae and papillae are formed by the lamina propria and submucosa and by connective tissue with the tunica muscularis. The tunica muscularis of the omasum at the end of foetal life consists of two layers of smooth muscle, circular and longitudinal. The muscular layer of the mucosa in the omasal laminae is fully developed and occupies most of it. The serosa, formed by the endothelium and a sublayer of connective tissue, is the thinnest layer of the wall of the omasum in the goat foetus (Nwaogu and Ezeasor, 2008; Garcia et al., 2013b; Garcia et al., 2014a; Okpe et al., 2016; Soni et al., 2016).

Morphogenesis of the omasum

On day 35 of gestation the omasum can be seen as a separate compartment of the stomach with an oval shape, pressed against the side of the cavity and lined on the inner side with a mucosa with small elevations corresponding to its layers. It is the smallest compartment of the foetal goat stomach and grows along the dorsoventral axis. On day 50 of foetal life, the omasum is located on the right side of the median plane of the embryo under the reticulum (Fig. 1. C). From day 75, primary, secondary, tertiary and quaternary laminae begin to protrude into the cavity of the omasum. From day 112, conical papillae become visible on the lateral surface of the laminae (Gupta et al., 2017b).

Prenatal development of the abomasum in the goat

Histogenesis of the foetal abomasum

The abomasum becomes a separate compartment of the stomach on day 35 of the foetal life of the goat. At this time its wall consists of three layers – the epithelium, pluripotent blastemal tissue, and the serosa. The epithelium is formed of cylindrical cells. The pluripotent blastemal tissue is formed of mesenchymal cells suspended in an extracellular matrix. The serous layer is composed of a layer of connective tissue under a mesothelium of flat cells (Garcia et al., 2013a). On day 38 of gestation, primordial abomasal folds appear as small projections of the epithelial layer towards the lumen. During further prenatal development, the epithelium of the abomasum is divided into two well-differentiated layers: a basal layer with evenly distributed nuclei and a layer of cells with apical cytoplasm. The pluripotent blastemal tissue is clearly separated from the epithelium by a basal membrane (Garcia et al., 2013a). At 50 days of foetal life, the appearance of fibroblasts and collagen fibres differentiates the pluripotent blastemal tissue of the abomasum into the lamina propria and the submucosa. At this stage we can distinguish the muscular layer from the pluripotent blastemal tissue in the form of four layers of myoblasts derived from mesenchymal cells. The serosa is formed of loose connective tissue under a flat layer of mesothelial cells (Garcia et al., 2013a; Garcia et al., 2014a). After 52 days of gestation, folds are clearly visible in the foetal abomasum of the goat as elevations of the epithelium, lamina propria and submucosa. The wall of the abomasum of the goat foetus consists of four separate tissues: the epithelium, the lamina propria with the submucosa, the tunica muscularis and the serosa (Garcia et al., 2013a). Similar observations were made in a study on Nelore cattle, which confirms that goats and cattle belong to the same suborder of mammals, the ruminants (Nascimento et al., 2013). On day 64 of foetal life, the epithelium is transformed into a

simple columnar epithelium. At this stage, the muscular layer of the mucosa consists of several layers of smooth muscle fibres from the inner layer of the tunica muscularis. At the top of the folds of the abomasum irregularities can be seen on the surface; these are the villi of the abomasum. At mid-gestation the distances between the tops of the folds are much greater due to the abomasum cavities formed in the grooves separating them (Lee et al., 1994; Garcia et al., 2014a). After 87 days of the foetal life of the goat, the first glandular cells are visible on the fundus of the abomasum. The muscular layer of the mucosa has several layers separating the lamina propria from the submucosa, while the tunica muscularis consists of two bundles of smooth muscle fibres. The first of these is an outer bundle of fibres arranged longitudinally, and the second is an inner, circular one (Lee et al., 1994; Garcia et al., 2013a; Garcia et al., 2014a). On day 113, we can distinguish regions in the abomasum with the types of glands corresponding to them. One of these is the cardiac region, located between the omasum and abomasum, with the cardiac glands located closest to the abomasum cavities. Next is the region of the fundus and body of the abomasum, with oxyntic glands located deep in the abomasum cavities. The next glandular region is the pyloric region, located further along the abomasum, with the pyloric glands. The lamina propria, composed of dense connective tissue, fills the spaces between the stomach glands of the abomasum. The submucosa at this stage of foetal life consists of vascularized connective tissue, while the tunica muscularis contains two well-developed bundles of smooth muscle fibres and scattered nerve plexuses. The serosa consists of connective tissue, blood vessels, and nerve fibres with a top layer of flat mesothelial cells (Lee et al., 1994; Garcia et al., 2013a; Garcia et al., 2014a)

Morphogenesis of the abomasum

At the initial stages of gestation the abomasum is comma-shaped, but as it develops the anterior part becomes more elongated and wider, while the posterior part becomes narrower (Fig. 1. C). It is located between the eighth rib and the third lumbar vertebra. In the initial prenatal period, it is completely covered by the left lobe of the liver. From day 41 of gestation the fundus of the abomasum can be distinguished from the pyloric part. The first folds appear in its lower part on day 51. During the foetal development of the goat, the abomasum is the largest compartment of the stomach (Gupta et al., 2015; Gupta et al., 2016; Gupta et al., 2017b).

CONCLUSIONS

Knowledge of the changes taking place during the prenatal development of the goat stomach at the histological and morphological level can have practical application, e.g. in prenatal diagnostics in this species. In this context, ultrasound examination can be an excellent tool. Ultrasonography exploits the echogenicity specific to individual embryonic and foetal structures to produce images with darker or lighter regions. Technological progress, especially continual improvement in the resolution of ultrasound imaging, enables precise visualization of embryonic and foetal structures (Wojtasiak et al., 2020). The available literature indicates that an ultrasound image of the stomach of the goat foetus can be obtained at about 78 days of gestation (Sadi, 2019). Nevertheless, there is a lack of precise data on the visualization of characteristic structures of the stomach in this species. Therefore research focused on precise analysis of the chambers and structure of the stomach and determination of its biometric parameters at each stage of prenatal development would be interesting and important, not only from a diagnostic perspective. This would undoubtedly provide an additional,

ultrasonographic marker that would be helpful in assessing the course of gestation in the domestic goat.

REFERENCES

1. Agrawal A.R., Karim S.A., Kumar R., Sahoo A., John P. (2014). Sheep and goat production: basic differences, impact on climate and molecular tools for rumen microbiome study. *International Journal of Current Microbiology and Applied Sciences*, 3: 684-706.
2. Cheng G.X., Wang Y.G., Zhou X.G., Du F., Xiao Y.D., Xu S.F. (1995). A preliminary study on early development of goat (*Capra hircus*) reconstituted embryos. *Shi Yan Sheng Wu Xue Bao*. 28: 147-55.
3. El-Gendy S.A., Derbalah A. (2010). Macroscopic and microscopic anatomy of the omasum of the Baladi goat. *Journal of Applied Biological Sciences*, 4: 37-45.
4. García A., Masot J., Franco A., Gazquez A., Redondo E. (2012). Histomorphometric and immunohistochemical study of the goat rumen during prenatal development. *Histology and Histopathology*, 28: 737-748.
5. García A., Masot A.J., Franco A., Gazquez A., Redondo E. (2013a). Histomorphometric and immunohistochemical study of the goat abomasum during prenatal development. *Histology and Histopathology*, 28: 1639–1649. <https://doi.org/10.14670/HH-28.1639>
6. García A., Masot A.J., Franco A., Gázquez A., Redondo E. (2013b). Histomorphometric and immunohistochemical study of the goat omasum during prenatal development. *Histology and Histopathology*, 28: 737–748. <https://doi.org/10.14670/HH-28.737>
7. García A., Masot A.J., Franco A., Gázquez A., Redondo E. (2013c). Histomorphometric and immunohistochemical study of the goat reticulum during prenatal development. *Histology and Histopathology*, 28: 1369–1381. <https://doi.org/10.14670/HH-28.1369>
8. García A., Rodríguez P., Masot J., Franco A., Redondo E. (2014a). Histomorphometric study of the goat stomach during prenatal development. *Animal Science Journal*, 85: 951-962.
9. García A., Masot J., Franco A., Gazquez A., Redondo E. (2014b). Immunohistochemical evaluation of the goat forestomach during prenatal development *Journal of Veterinary Science*, 15: 35-43. <https://doi.org/10.4142/jvs.2014.15.1.35>
10. Giger-Reverdin S., Domange C., Broudiscou L., Sauvant D., Berthelot V. (2020). Rumen function in goats, an example of adaptive capacity. *Journal of Dairy Research*, 87: 45–51. doi: 10.1017 / S0022029920000060
11. Gupta V., Farooqui M. M., Archana M., Kumar P. (2015). Morphogenesis of rumen in goat (*Capra hircus*). *Journal of Veterinary Anatomy*, 8: 37-48.
12. Gupta V., Farooqui M.M., Ajay P., Rakesh G. (2016). Morphological changes in foetal goat abomasum (*Capra hircus*). *Indian Journal of Veterinary Anatomy*, 28: 61-65.
13. Gupta V., Farooqui M.M., Prakash A., Pathak A., Kumar P. (2017a). Organogenesis of rumen of goat (*Capra hircus*) in early prenatal stage (0-50 days) of gestation. *Ruminant Science*, 6: 247-254.
14. Gupta V., Farooqui M.M., Prakash A., Verma, A. (2017b). Gestational variations in the macro anatomy of the fore stomach of goat (*Capra hircus*). *Indian Journal of Animal Research*, 52: 974-982.

15. Histogenesis of the reticulum of non-descript goat (*Capra hircus*) of India Varsha Gupta, Muneer Mohhammad Farooqui, Ajay Prakash Sharma, Archana Pathak bioRxiv 2020.02.14.950311; doi: <https://doi.org/10.1101/2020.02.14.950311>
16. Jakhesara S., Koringa P. G., Ramani U. V., Ahir V., Tripathi A., Soni P., Sajjani M. R. (2010). Comparative study of tannin challenged rumen microbiome in goat using high throughput sequencing technology. *Developmental Microbiology and Molecular Biology*, 1: 95-106.
17. Lee J.H., Huh C.K., Kim C.S., Kwak S.D. (1994). Development on the abomasum of fetuses and neonates in Korean native goats. *Korean Journal of Veterinary Research*, 34: 219-227.
18. Majeed A. F., Al-Timimi I. H., Al Saigh M. N. (2019). In vitro embryo production from oocyte recovered from live and dead Iraqi black goat: A preliminary study. *Research Journal of Biotechnology*, 14: 226-233
19. Membrive C. M. B. (2016). Anatomy and Physiology of the Rumen. In *Rumenology*. Springer, Cham. (pp. 1-38)
20. McGeedy T. A., Quinn P. J., FitzPatrick E. S., Ryan M. T., Kilroy D., & Lonergan P. (2017). *Veterinary embryology*. John Wiley & Sons.
21. Molinari E., Goicoechea O. (1993). Anatomía del Desarrollo del Tracto Digestivo y Forma Corporal Externa Durante el Período Embrionario en el Caprino (*Capra hircus*). *Anatomia, Histologia, Embryologia*, 22: 123-143.
22. Nascimento G., Carvalho R., Perri S., Monteiro C.M. (2013). Development of bovine abomasum in prenatal period. *Brazilian Journal of Veterinary Research and Animal Science*, 50, 279-285.
23. Nwaogu C.I., Ezeasor N.D. (2008). Studies on the development of omasum in west African dwarf goats (*Capra hircus*). *Veterinary Research Communications*, 32: 543-552.
24. Okpe G. C., Chukwudi C. U. (2016). Histogenesis of the forestomach of red Sokoto goats. *Animal Research International*, 13: 2428-2435.
25. Sadi F. (2019). Study of Diagnosis of Pregnancy and Fetal Development by 2D Ultrasound in Markhoz Goat. *Iranian Journal of Veterinary Surgery*, 14: 54-59.
26. Soni T., Goswami H., Panchal K. (2016). Prenatal Development of Fore-Stomach In Small Ruminants. *Advances in Life Sciences*, 5: 10209-10215.
27. Teixeira, A., Wedel, T., Krammer, H. and Kuhnel, W. (1998). Structural differences of the enteric nervous system in the cattle forestomach revealed by whole mount immunohistochemistry. *Annals of Anatomy*, 180: 393-400.
28. Wojtasiak N., Stankiewicz T., Udała J. (2020). Badanie ultrasonograficzne u kozy domowej (*Capra hircus*) –przegląd. *Roczniki Naukowe Polskiego Towarzystwa Zootechnicznego*, 16: 65–78.
29. Zhong T., Hu J., Xiao P., Zhan S., Wang L., Guo J., Li L., Zhang H., Niu L. (2017). Identification and Characterization of MicroRNAs in the Goat (*Capra hircus*) Rumen during Embryonic Development. *Frontiers in Genetics*, 8: 163. doi: 10.3389/fgene.2017.00163
30. Zhong T., Wang C., Hu J., Chen X., Niu L., Zhan S., Wang L., Guo J., Cao J., Li L., Zhang H. (2020). Comparison of MicroRNA Transcriptomes Reveals the Association between MiR-148a-3p Expression and Rumen Development in Goats. *Animals*, 10: 1951.