

DOI 10.2478/pjvs-2013-0087

*Short communication*

# Magnetic resonance imaging assisted with fine needle aspiration biopsy in the diagnosis of fibrosarcomas of the skull in dogs

Y. Zhalniarovich<sup>1</sup>, Z. Adamiak<sup>1</sup>, P. Przyborowska<sup>1</sup>, D. Otrocka-Domagala<sup>2</sup>

<sup>1</sup> Department of Surgery and Radiology

<sup>2</sup> Department of Pathology, Faculty of Veterinary Medicine, University of Warmia and Mazury in Olsztyn, Oczapowskiego 14, 10-957 Olsztyn, Poland

## Abstract

Five canine patients were directed to low-field magnetic resonance imaging due to different neurological defects. In each case there were heterogeneous extraaxial masses covering left or right dorsal parietal and occipital lobes that were isointense to the brain on T1-weighted Spin Echo images, isointense to hypointense to the brain on T2-weighted Fast Spin Echo sequences and hypointense to the brain on Flair sequence. After MRI study fine needle aspiration biopsy of the tumors was performed. On the basis of the cytological examination fibrosarcomas with of moderate malignancy were diagnosed.

**Key words:** MRI, fibrosarcoma, brain, sequences, FNA, biopsy, dog

## Introduction

The examiner can not put proper diagnostic based only on magnetic resonance (MR) study. Additional research such as histopathological examination or fine needle aspiration (FNA) biopsy should be performed (Kraft and Gavin 1999). In the present article authors reviewed MR imaging findings in five dogs with skull fibrosarcomas involving the splanchnocranium and neurocranium, and compared MR images with cytological images obtained using fine needle aspiration biopsy.

## Materials and Methods

Five dogs were directed to MR imaging study due to different neurological defects including postural reaction deficits in all limbs, circling, unsteady gait in all limbs, abnormal coordination, staggering of obstacles, ataxia, loss of vision and tearing from the eye. The evaluated dogs aged from 8 years to 13 years (mean age 10 years). The dogs belonged to three different breeds: 2 German Shepherd dogs, 2 Labrador dogs and 1 American Staffordshire terrier.

MRI examination was performed in all dogs under general anesthesia with the use of a low-field scanner

---

Correspondence to: Y. Zhalniarovich, e-mail: eugeniusz.zolnierowicz@uwm.edu.pl

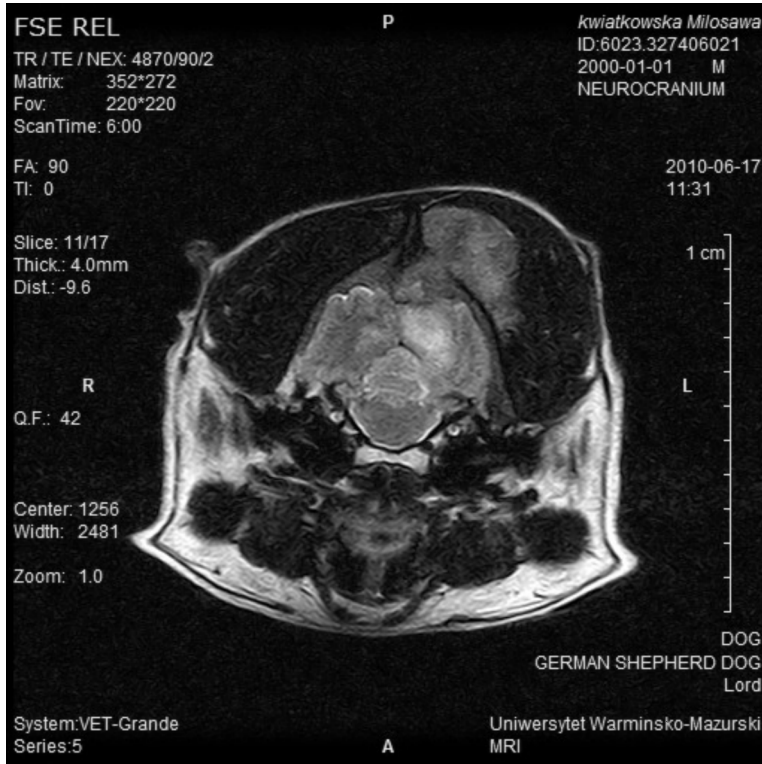


Fig. 1. MRI revealed heterogeneous masses covering the left occipital and parietal lobes isointense to hypointense to the brain on T2-weighted FSE sequences in the transverse plane.

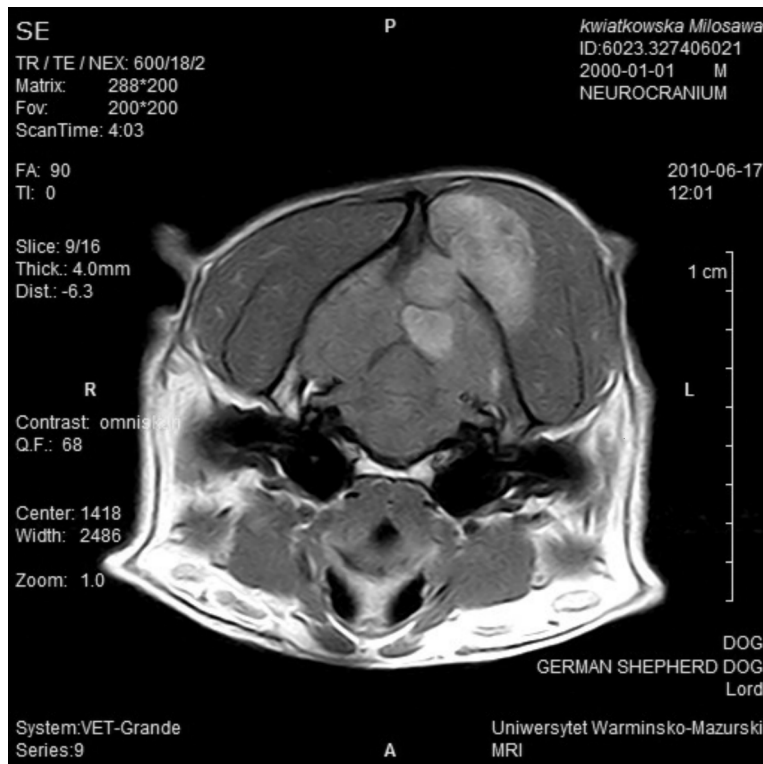


Fig. 2. Upon MRI the masses had intense contrast enhancement on postcontrast T1-weighted SE sequence in the transverse plane.

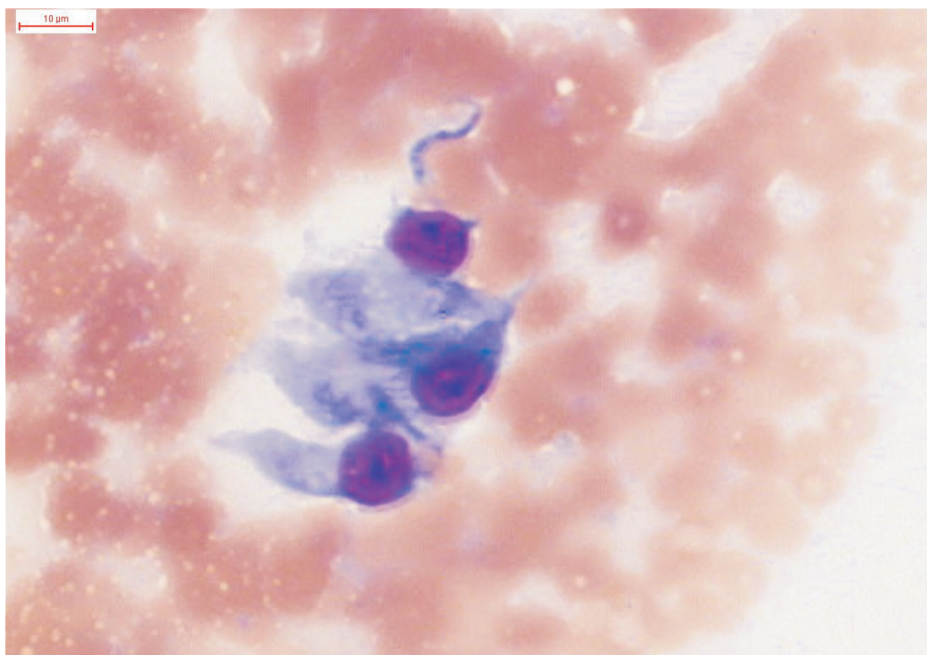


Fig. 3. Cytology revealed a moderate number of elongate to oval cells with the slightly basophilic cytoplasm. The nuclei were oval to fusiform, and had prominent nucleoli.

with a field strength of 0,25T (Vet Grande, Esaote, Italy). According to Zhalniarovich et al. (2013) the skull section was scanned with use of Spin Echo (SE) T1-weighted sequences in the transverse and sagittal planes, Fast Spin Echo (FSE) T2-weighted sequences in the sagittal and transverse plane and Fluid Attenuated Inversion Recovery (Flair) sequence in the dorsal and transverse plane.

## Results and Discussion

In each case upon MR imaging there were heterogeneous extraaxial masses covering the left or right dorsal parietal and occipital lobes that were isointense to brain on T1-weighted SE images in the sagittal and transverse plane, isointense to hypointense to brain on T2-weighted FSE sequences in the sagittal and transverse plane and hypointense to brain on Flair sequence (Fig. 1). Those patients had contrast administration intravenously at a dose of 0.2 mmol/kg body weight (Omniscan 0,5 mmol/ml gadodiamidum, GE Healthcare AS, Norway). The masses had intense contrast enhancement on postcontrast T1-weighted SE and Flair sequences (Fig. 2). After MRI study FNA biopsy of the tumors was performed. Smears were stained with Hemacolor ready-to-use staining kit (Merck KGaA, Darmstadt, Germany) and scanned using PANORAMIC MIDI (3DHISTECH Kft, Hungary) slide scanner. Cytological examination revealed the presence of a moderate number of elongate to

oval cells with slightly basophilic cytoplasm. The nuclei were oval to fusiform, and had one or more prominent nucleoli. Fibrosarcomas of moderate malignancy were diagnosed (Fig. 3).

Fibrosarcoma is malignant soft tissue neoplasm uncommon in dogs and represents about 1.5% of all skin and subcutaneous tumors (Gross TL et al. 2005). Fibrosarcomas are mostly locally invasive, which is manifested by frequent postexcisional local recurrence (Gross TL et al. 2005). The incidence of distant metastasis via hematogenous routes in dogs is between 9% to 25% depending on the level of malignancy (Gross TL et al. 2005, Raskin RE 2010). Cytologically, fibrosarcomas are composed of spindle shaped cells but more anaplastic tumors can have marked cellular pleomorphism (Cowell RL et al. 2008).

In all the dogs no surgery treatment was performed. The reason was the size of the tumors masses. In each case it was more than 42 mm. In the present studies FNA biopsy turned out to be a very useful technique to obtain data to complete the diagnosis of MRI modality.

## References

- Cowell RL, Tyler RD, Meinkoth JH (2008) Cutaneous and subcutaneous lesions. In: Cowell RL, Tyler RD, Meinkoth JH, DeNicola D (eds) Diagnostic cytology and hematology of the dog and cat. 3<sup>rd</sup> ed., Mosby Elsevier, pp 78-111.

- Gross TL, Ihrke PJ, Walder EJ, Affolter VK (2005) Mesenchymal neoplasm and other tumors. In: Gross TL, Ihrke PJ, Walder EJ, Affolter VK (eds) *Skin diseases of the dog and cat. Clinical and Histopathologic Diagnosis*. 2<sup>nd</sup> ed., Blackwell Science, Oxford, pp 722-727.
- Kraft SL, Gavin PR (1999) Intracranial neoplasia. *Clin Tech Small Anim Pract* 14: 112-123.
- Raskin RE (2010) Skin and subcutaneous tissues. In: Raskin RE, Meyer DJ (eds) *Canine and feline cytology. A color atlas of interpretation guide*. 2<sup>nd</sup> ed., Saunders Elsevier, pp 54-57.
- Zhalniarovich Y, Adamiak Z, Pomianowski A, Jaskólska M (2013) Most commonly used sequences and clinical protocols for brain and spine magnetic resonance imaging allowing better identification of pathological changes in dogs. *Pol J Vet Sci* 16: 157-163.